

## CLINICAL PRACTICE GUIDELINES

# Rectal cancer: ESMO Clinical Practice Guidelines for diagnosis, treatment and follow-up<sup>†</sup>

R. Glynne-Jones<sup>1</sup>, L. Wyrwicz<sup>2</sup>, E. Tiret<sup>3,4</sup>, G. Brown<sup>5</sup>, C. Rödel<sup>6</sup>, A. Cervantes<sup>7</sup> & D. Arnold<sup>8</sup>, on behalf of the ESMO Guidelines Committee\*

<sup>1</sup>Department of Radiotherapy, Mount Vernon Centre for Cancer Treatment, Northwood, London, UK; <sup>2</sup>Department of Gastrointestinal Cancer, Maria Skłodowska-Curie Memorial Cancer Center and Institute of Oncology, Warsaw, Poland; <sup>3</sup>Department of Surgery, Sorbonne Universités, UPMC Univ Paris 06, Paris; <sup>4</sup>APHP, Hôpital Saint-Antoine, Paris, France; <sup>5</sup>Department of Radiology, The Imperial College and Royal Marsden Hospital, Sutton, Surrey, UK; <sup>6</sup>Department of Radiotherapy and Oncology, University of Frankfurt, Frankfurt, Germany; <sup>7</sup>CIBERONC, Medical Oncology Department, INCLIVA University of Valencia, Valencia, Spain; <sup>8</sup>Instituto CUF de Oncologia (I.C.O.), Lisbon, Portugal

\*Correspondence to: ESMO Guidelines Committee, ESMO Head Office, Via L. Taddei 4, CH-6962 Viganello-Lugano, Switzerland. E-mail: clinicalguidelines@esmo.org

<sup>†</sup>Approved by the ESMO Guidelines Committee: August 2002, last update May 2017. This publication supersedes the previously published version—Ann Oncol 2013; 24 (Suppl. 6): vi81–vi88.

### Incidence and epidemiology

The incidence of rectal cancer in the European Union is ~125 000 per year, i.e. ~35% of the total colorectal cancer incidence, reflecting 15–25 cases/100 000 population per year and is predicted to increase further in both genders. The mortality is 4–10/100 000 population per year. Median age at diagnosis is ~70 years, but predictions suggest that this figure will rise in the future.

Evidence is accumulating that rectal cancer is distinct from colon cancer with different aetiologies and risk factors [1–2], possibly reflecting different environmental exposures. High body mass index, body or abdominal fatness and diabetes type II are seen as risk factors. Longstanding ulcerative colitis and Crohn's disease affecting the rectum, excessive consumption of red or processed meat and tobacco as well as moderate/heavy alcohol use increase the risk.

A healthy lifestyle and exercise can reduce the risk of developing rectal cancer [3, 4]. Consumption of garlic, milk, calcium and high dietary fibre are regarded as protective [5]. Although regular use of non-steroidal anti-inflammatory drugs (NSAIDs) is associated with reduced incidence, and there may be a protective effect of vitamin D via antitumour immunity, no formal guidelines for pharmacological primary prevention should be advised.

The majority of rectal cancers develop via the chromosomal instability (CIN) pathway. About 13% are caused by deficient mismatch repair (dMMR). There is a recognised hereditary component, although this is more pronounced for colon than rectal cancer. The most common disorders are Lynch syndrome and familial adenomatous polyposis. Hence, genetic counselling

is a critical component of management, driving surveillance and potential interventions for the patient and affected family members [6].

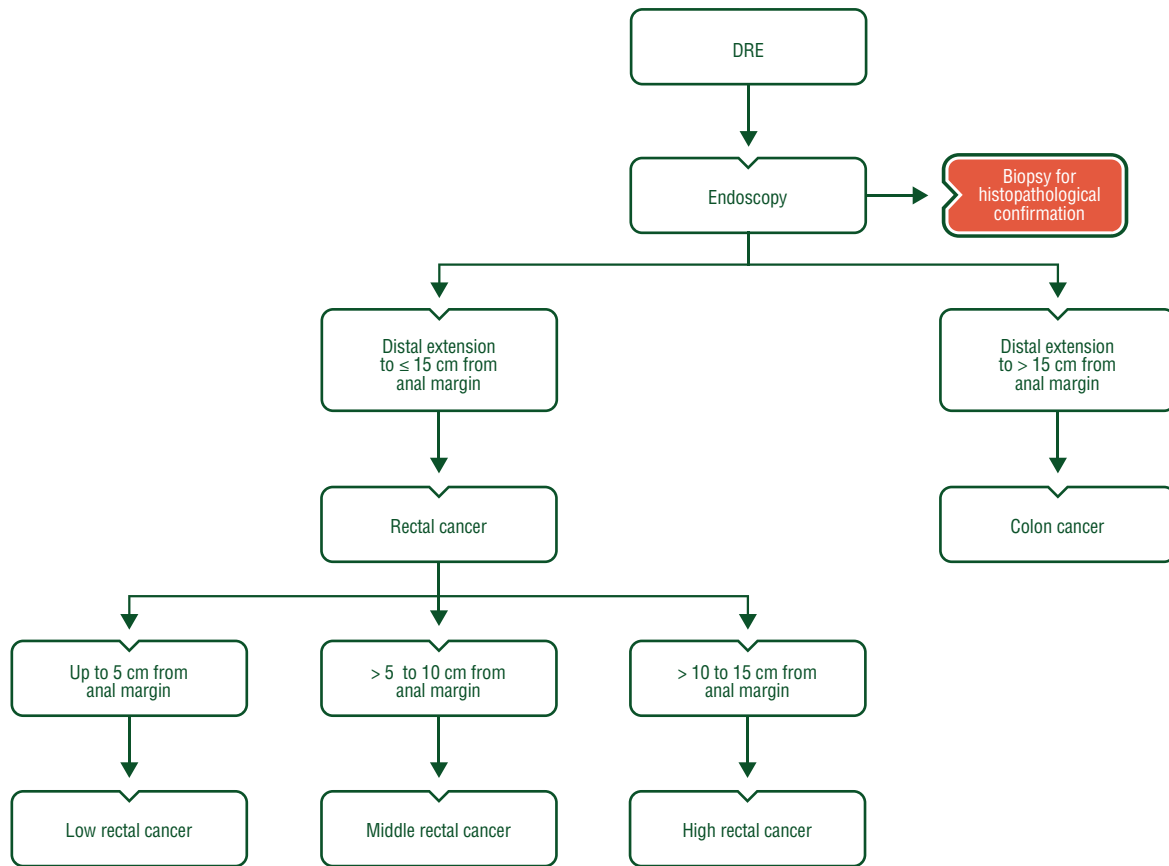
### Diagnosis and pathology/molecular biology

Diagnosis is based on a digital rectal examination (DRE) and endoscopy with biopsy for histopathological confirmation (Figure 1). Tumours with distal extension to ≤ 15 cm from the anal margin (as measured by rigid sigmoidoscopy) are classified as rectal and more proximal tumours as colonic. Cancers are categorised as low (up to 5 cm), middle (from > 5 to 10 cm) or high (from > 10 up to 15 cm).

The Cancer Genome Atlas Network analysis showed common genomic profiles for non-hypermethylated colon and rectal cancers [7]. Unique subtypes are characterised by accumulation of distinct genetic and epigenetic alterations (DNA methylation), differing slightly from colon cancer [8, 9]. A transcriptional subtype with high Wnt signalling, stem cell and mesenchymal signatures occurs in rectal cancer and has a poor prognosis. Such patients may also gain less benefit from adjuvant chemotherapy (ChT) [10].

### Staging and risk assessment

A specialised and dedicated multidisciplinary team (MDT) of named radiologists, surgeons, radiation oncologists, medical oncologists and pathologists should attend regular meetings and discuss all (relevant) patients [III, A]. Core members should be



**Figure 1.** Rectal cancer diagnosis. DRE, digital rectal examination.

present for the discussion of all cases where their input is needed [11]. There should be a MDT coordinator, and clinical guidelines should be taken into account in decision-making. The MDT should also audit whether their decisions are implemented [12] and review patient outcomes with standardised quality assurance.

A history and physical examination including DRE, full blood count, liver and renal function tests, serum carcinoembryonic antigen (CEA) and computed tomography (CT) scan of thorax and abdomen should be carried out to define functional status and presence of metastases [III, A] (Figure 2). Positron emission tomography (PET) may provide additional information in terms of disease outside the pelvis. However, current evidence is not considered strong enough to recommend the use of PET in all patients [V, C] (Table 1) [13].

Increasing age, comorbidity and decreasing functional reserves are associated with higher early postoperative mortality and worse toxicity from radiotherapy (RT) and ChT in older patients. Hence, for patients over 70 years, formal geriatric assessment or at least screening tools for frailty are recommended before any treatment [III, C] [14].

Rigid rectoscopy and preoperative colonoscopy to the caecal pole are required, or, in the case of obstruction, virtual colonoscopy to exclude synchronous colonic tumours. If no preoperative (virtual) colonoscopy was carried out, completion colonoscopy is recommended within 6 months of surgery [III, A].

**Table 1. Diagnostic work-up in primary rectal cancer**

Parameter	Method of choice
<b>Location</b> (distance from anal verge)	DRE/palpation Rigid sigmoidoscopy (flexible endoscopy)
<b>Morphological verification</b>	Biopsy
<b>cT stage</b>	
Early	ERUS MRI
Intermediate/advanced	MRI (ERUS)
<b>Sphincter infiltration</b>	MRI (ERUS, palpation, EUA)
<b>cN stage</b>	MRI (CT, ERUS)
<b>M stage</b>	CT, MRI (or US) of the liver/abdomen CT of the thorax PET-CT if extensive EMMI for other sites
<b>Evaluation for all patients</b>	MDT discussion

Methods within brackets are less optimal.

CT, computed tomography; DRE, digital rectal examination; EMMI, extramural vascular invasion; ERUS, endorectal ultrasound; EUA, examination under anaesthesia; MDT, multidisciplinary team; MRI, magnetic resonance imaging; PET, positron emission tomography; US, ultrasound.

**Table 2. UICC TNM staging (8th edition) classification for colon and rectal cancer [14]****TNM Clinical Classification****T—Primary tumour**

TX	Primary tumour cannot be assessed
T0	No evidence of primary tumour
Tis	Carcinoma <i>in situ</i> : invasion of lamina propria <sup>a</sup>
T1	Tumour invades submucosa
T2	Tumour invades muscularis propria
T3	Tumour invades subserosa or into non-peritonealised pericolic or perirectal tissues
T4	Tumour directly invades other organs or structures <sup>b,c,d</sup> and/or perforates visceral peritoneum
T4a	Tumour perforates visceral peritoneum
T4b	Tumour directly invades other organs or structures

**N—Regional lymph nodes**

NX	Regional lymph nodes cannot be assessed
N0	No regional lymph node metastasis
N1	Metastasis in 1–3 regional lymph nodes
N1a	Metastasis in 1 regional lymph node
N1b	Metastasis in 2–3 regional lymph nodes
N1c	Tumour deposit(s), i.e. satellites, <sup>e</sup> in the subserosa, or in non-peritonealised pericolic or perirectal soft tissue <i>without</i> regional lymph node metastasis
N2	Metastasis in 4 or more regional lymph nodes
N2a	Metastasis in 4–6 regional lymph nodes
N2b	Metastasis in 7 or more regional lymph nodes

**M—Distant metastasis**

M0	No distant metastasis
M1	Distant metastasis
M1a	Metastasis confined to one organ (liver, lung, ovary, non-regional lymph node(s)) without peritoneal metastases
M1b	Metastasis in more than one organ
M1c	Metastasis to the peritoneum with or without other organ involvement

<sup>a</sup>Tis includes cancer cells confined within the mucosal lamina propria (intramucosal) with no extension through the muscularis mucosae into the submucosa.

<sup>b</sup>Invades through to visceral peritoneum to involve the surface.

<sup>c</sup>Direct invasion in T4b includes invasion of other organs or segments of the colorectum by way of the serosa, as confirmed on microscopic examination, or for tumours in a retroperitoneal or subperitoneal location, direct invasion of other organs or structures by virtue of extension beyond the muscularis propria.

<sup>d</sup>Tumour that is adherent to other organs or structures, macroscopically, is classified cT4b. However, if no tumour is present in the adhesion, microscopically, the classification should be pT1–3, depending on the anatomical depth of wall invasion.

<sup>e</sup>Tumour deposits (satellites) are discrete macroscopic or microscopic nodules of cancer in the pericorectal adipose tissue's lymph drainage area of a primary carcinoma that are discontinuous from the primary and without histological evidence of residual lymph node or identifiable vascular or neural structures. If a vessel wall is identifiable on H&E, elastic or other stains, it should be classified as venous invasion (V1/2) or lymphatic invasion (L1). Similarly, if neural structures are identifiable, the lesion should be classified as perineural invasion (Pn1). The presence of tumour deposits does not change the primary tumour T category, but changes the node status (N) to pN1c if all regional lymph nodes are negative on pathological examination.

H&E, hematoxylin and eosin; UICC, the Union for International Cancer Control; TNM, tumour, node, metastasis.

Reprinted from [16], with permission from John Wiley & Sons, Inc.

Endoscopic rectal ultrasound (ERUS) may define treatment for the earliest tumours. T1 tumours appropriate for transanal endoscopic microsurgery (TEM) can be selected by determining whether a lesion is limited to the mucosa or submucosa (sm) [15]. ERUS offers less value in locally advanced rectal cancer (LARC).

Pelvic magnetic resonance imaging (MRI) is the most accurate test to define locoregional clinical staging. By detecting extramural vascular invasion (EMVI), and determining the T substage and distance to the circumferential resection margin (CRM), MRI can also predict the risks of local recurrence and synchronous/metachronous distant metastases, and should be carried out

to select patients for the respective preoperative management and to define the extent of surgery [III, A]. A standard proforma for MRI and pathology ensures a comprehensive report. The version of TNM staging used by the histopathologist and the MDT should be documented, acknowledged by all members of the MDT and regularly updated. The Union for International Cancer Control (UICC) TNM staging classification (8th edition) is shown in Table 2 [16].

High-quality MRI allows further subclassification of cT3, which is recommended as described in Table 3 [17, 18]. Stage grouping is shown in Table 4 [16].

**Table 3. Subclassification of T3 rectal cancer [18]**

	Depth of invasion beyond the muscularis propria (in mm)
T3a <sup>a</sup>	< 1
T3b	1–5
T3c	6–15
T3d	> 15

<sup>a</sup>This sub-classification based upon an evaluation using MRI before treatment decision is clinically valuable, and is used in these recommendations. It can be used also in the histopathological classification but is not validated and not incorporated in any of the TNM versions (5–7).

MRI, magnetic resonance imaging; TNM, tumour, node, metastasis. Reprinted from [18] with permission from Springer.

Meta-analyses and population data show clinical nodal staging is unreliable even using ERUS, CT and MRI combined. The use of node size > 10 mm as a criterion for node-positive disease has been shown to be inaccurate. Irregular border and heterogeneous signal provide more relevant additional information [19]. Nomograms have been suggested as a predictor of lymph node involvement but have yet to be validated [20]. The assessment of the relationship between tumour and mesorectal fascia (MRF) is more crucial to decision-making than lymph node status.

PET-CT should not be used routinely for initial staging, but can, in conjunction with liver MRI and contrast enhanced CT of the thorax, abdomen and pelvis be used to assess features at presentation associated with a high risk of metastases, e.g. extensive EMVI on MRI (see above) or high levels of CEA. Its value for assessment of primary tumour and nodal status is unproven, although it may assist RT target delineation. Bone scan and brain imaging should only be carried out if symptoms warrant.

## Histopathology

T1 tumours can be classified according to Haggitt's subclassification if the cancer is pedunculated and according to the Kudo/Kikuchi sm-system if in a sessile adenoma [21, 22]. The two systems overlap. If sessile, the level of infiltration into the sm and the width of invasion compared with the width of the cancer should be assessed [23]. If pedunculated, the grade, lymphovascular invasion (LVI) and presence of budding predict the risk of lymph node metastases, enable a risk/benefit assessment of the requirement for further surgery and define the method of excision [III, B] [24]. These specimens should be pinned-out on cork before pathology assessment to facilitate this subclassification.

Endoscopic resection for small tumours/polyps can be useful for both diagnosis and treatment, but *en bloc* resection is recommended for accurate assessment of invasion in the resection margin and the deepest area [II, B]. Piecemeal resection makes the specimen impossible to assess for the above and should be avoided.

However, radical surgery and removal of lymph nodes is recommended for high-risk pathological features according to Japanese guidelines, i.e. poorly differentiated with evidence

**Table 4. Stage grouping of colon and rectal cancer [16]**

TNM Pathological Classification			
The pT and pN categories correspond to the T and N categories.			
pN0	Histological examination of a regional lymphadenectomy specimen will ordinarily include 12 or more lymph nodes. If the lymph nodes are negative, but the number ordinarily examined is not met, classify as pN0.		
Stage			
Stage 0	Tis	N0	M0
Stage I	T1, T2	N0	M0
Stage II	T3, T4	N0	M0
Stage IIA	T3	N0	M0
Stage IIB	T4a	N0	M0
Stage IIC	T4b	N0	M0
Stage III	Any T	N1, N2	M0
Stage IIIA	T1, T2	N1	M0
	T1	N2a	M0
Stage IIIB	T1, T2	N2b	M0
	T2, T3	N2a	M0
	T3, T4a	N1	M0
Stage IIIC	T3, T4a	N2b	M0
	T4a	N2a	M0
	T4b	N1, N2	M0
Stage IV	Any T	Any N	M1
Stage IVA	Any T	Any N	M1a
Stage IVB	Any T	Any N	M1b
Stage IVC	Any T	Any N	M1c

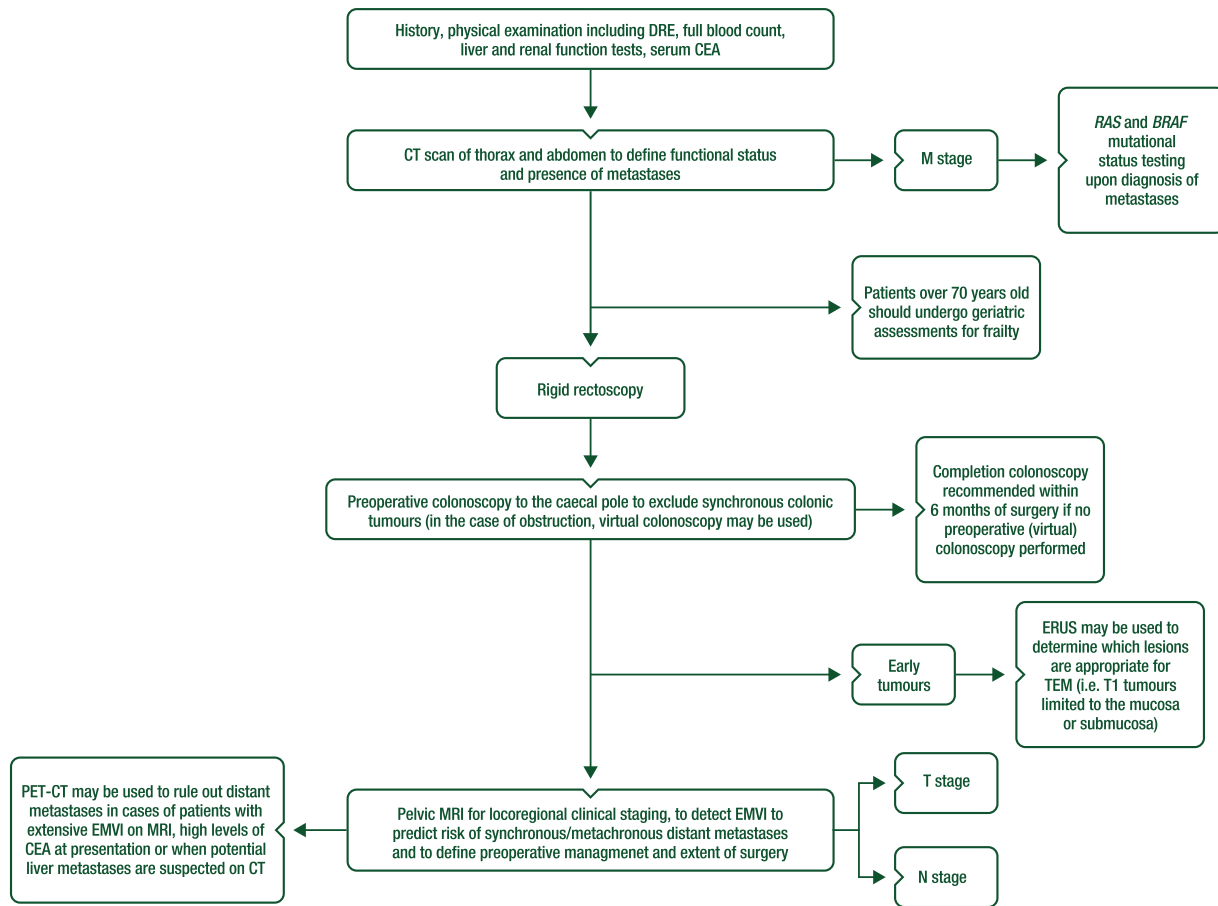
TNM, tumour, node, metastasis.

Reprinted from [16], with permission from John Wiley & Sons, Inc.

of vascular or lymphatic invasion, and an invasion depth of > 1000 micrometres [II, A] [25].

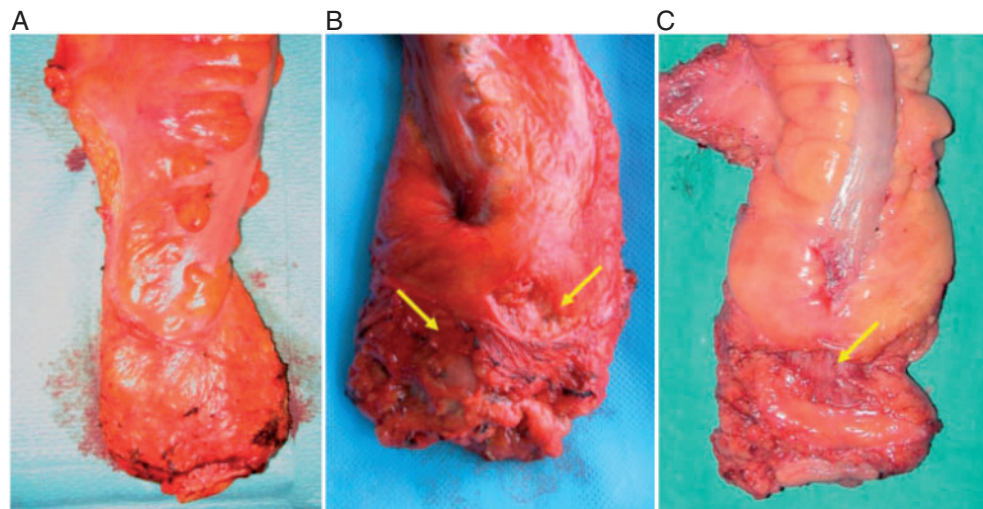
For mesorectal resections, histopathological examination should include a photographic record of the surgical specimen and assessment of total mesorectal excision (TME) quality [III, B] [26–28], which is a strong quality control measure (Figure 3). The classification has three grades based on the completeness of the removal of the mesorectum and/or plane of surgical excision (Table 5) and impacts on both local recurrence and survival. Along with the involved CRM rate (i.e. ≤ 1 mm), TME quality represents a surrogate parameter for good oncological outcomes [29]. More advanced T-stage, tumour distance from the anal verge < 8 cm, more advanced age and low surgical case volume have been independently associated with moderate or poor TME quality [30].

At least 12 regional lymph nodes should be examined. Proximal, distal and circumferential margins should be documented in millimetres (separately for tumour and involved lymph nodes). A proforma report such as the one by the Royal College of Pathologists is recommended [IV, B] [31]. Uncertainties in the interpretation of CRM and the residual (R) tumour classification (and the distinction pT4/R1) according to the TNM version can cause confusion. An expanded classification has been suggested [32]. Extranodal extension (ENE) of nodal metastases, EMVI, perineural invasion (PNI) and tumour



**Figure 2.** Rectal cancer staging.

CEA, carcinoembryonic antigen; CT, computed tomography; DRE, digital rectal examination; EMVI, extramural vascular invasion; ERUS, endorectal ultrasound; MRI, magnetic resonance imaging; PET-CT, positron emission tomography computed tomography; TEM, transanal endoscopic microsurgery.



**Figure 3.** The definitions for defining quality of mesorectal excision [28].

(A) A complete mesorectal excision—shows good bulk of mesorectum with a smooth surface and no defects. (B) A nearly complete mesorectal excision shows good bulk of mesorectum, but some defects or irregularities in the surface (arrowed) are present. (C) An incomplete mesorectal excision demonstrating a deep defect on the mesorectum below the peritoneal reflection, which allows visualisation of the muscularis propria (arrowed).

Reprinted from [28], with permission from John Wiley & Sons, Inc.

**Table 5. Grading of quality and completeness of the mesorectum in a total mesorectal excision specimen according to the plane of surgical excision [27]**

Mesorectal plane (good plane of surgery achieved)	Intact mesorectum with only minor irregularities of a smooth mesorectal surface; no defect deeper than 5 mm; no coning; and smooth circumferential resection margin on slicing
Intrameresorectal plane (moderate plane of surgery achieved)	Moderate bulk to mesorectum, with irregularities of the mesorectal surface; moderate distal coning; muscularis propria not visible with the exception of levator insertion; and moderate irregularities of circumferential resection margin
Muscularis propria plane (poor plane of surgery achieved)	Little bulk to mesorectum with defects down onto muscularis propria; very irregular circumferential resection margin; or both

The specimen is examined as a whole (fresh) and as cross-sectional slices (fixed) to make an adequate interpretation. A TME specimen ideally should have a smooth surface, without incisions, defects or cracks, as an indication of successful surgical excision of all mesorectal tissue. 'Coning' represents the tendency for the surgeon to cut inwards towards the central tube of the rectum during distal dissection, rather than staying outside the visceral mesorectal fascia. The specimen then shows a tapered, conical appearance representing suboptimal surgical quality.

TME, total mesorectal excision.

Reprinted from [27] with permission from Elsevier.

budding should also be evaluated [III, A]. Analysis of the rectal 'doughnut' is not required [IV, C] [33].

## Management of local/locoregional disease

### Risk-adapted treatment

*Very early cT1N0, with low grade (G1/G2).* Local excisional procedures such as TEM are appropriate as a single modality for early cancers (cT1N0 without adverse features like G3, V1, L1) [III, A] [34, 35]. Only patients with cT1N0 should be considered for such treatment [36], although TEM for more advanced T-stage may be appropriate for patients at high surgical risk after discussion with the patient.

TEM permits more accurate *en bloc*, full-thickness local excision of rectal tumours than local excision, and can provide similar oncological results in pT1sm1 (clinical cN0) rectal cancers compared with results achieved by TME, without compromising anorectal function.

Local recurrence after local excision often occurs in the tumour bed. If there is an unfavourable pTNM assessment following local excision, the value of adjuvant CRT in preventing local recurrence is unproven, and TME should remain the standard salvage option.

Local RT (brachytherapy or contact therapy—Papillon technique) may also be used as an alternative to local surgery [37], alone or combined with CRT [III, C].

*Early rectal cancer not suitable for local excision [cT1–cT2; cT3a/b if middle or high, N0 (or also cN1 if high), MRF clear, no EMVI].* More advanced tumours up to and including cT2c/T3a/b should be treated by radical TME surgery because of higher risks of recurrence and the higher risk of mesorectal lymph node involvement [36]. The standard of care for surgery is TME, implying that all of the mesorectal fat, including all lymph nodes, should be meticulously excised [III, A]. A partial mesorectal excision with a distal margin of at least 5 cm of mesorectum can be considered in high rectal cancer.

In rare situations, local excision can be an option in patients with a cT1 tumour or in elderly or fragile patients. TEM is then the procedure of choice.

In selecting laparoscopic or open surgery, the surgeon should take into account his/her experience with the technique, the stage and location of the cancer and patient factors such as obesity and previous open abdominal surgery. In the case of low rectal tumours, transanal TME (TaTME) may facilitate pelvic and distal mesorectal dissection, but standardisation and assessment of the technique are necessary [38].

Robotic-assisted rectal cancer surgery provides some technical advantages for surgeons compared with conventional laparoscopy, but is still under evaluation [39]. If an abdominoperineal excision is planned and the tumour extends into the levators, a cylindrical specimen should be achieved, avoiding a 'waist' effect and minimising the risk of a positive CRM and/or an R1/2 resection [40]. Selection of patients suitable for extralevator abdominoperineal excision is recommended using MRI [41].

In Japan, lateral node dissection (LND) is practised if the tumour is sited below the peritoneal reflection to reduce the risk of pelvic recurrence and improve overall survival (OS). Lateral pelvic nodes are often invaded if multiple mesorectal nodes are involved [42]. LND is rarely practised in Europe, unless involvement is suspected on imaging with enlarged lateral nodes persisting following chemoradiotherapy (CRT).

For cT2 tumours < 4 cm, local excision after preoperative RT/CRT has been considered as alternative management to abdominal surgery [43–45], with minimal adverse impact on anorectal function 1 year after surgery [45]. More mature data from other studies suggests some compromise to function [46]. This strategy is not routinely recommended outside clinical trials, except for elderly, fragile patients at high surgical risk [47, 48].

These early, favourable cases, which are not suitable for local excision, i.e. cT1-2 but with adverse pathological features (e.g. G3, V1, L1), and some cT3a/b without clear involvement of MRF (MRF-) according to MRI, when located above the levators, may be appropriate for surgery alone with TME [II, A], as the risk of local failure is very low. Although not prospectively assessed, EMVI on MRI, even in the case of cT3a/b tumours, confers a higher risk of local and distant recurrence [49].

For complete responders, in patients with cT2-3a tumours, a 'watch-and-wait' approach or local excision after neoadjuvant CRT is feasible, but because of limited data about long-term outcomes should be implemented only in prospective protocols [IV, C] [50].

**Intermediate/more locally advanced rectal cancers [cT3a/b (very low, levators clear, MRF clear or (cT3a/b in mid- or high rectum, cN1-2 (not extranodal), no EMVI)].** The routine delivery of preoperative RT, either CRT or short-course preoperative radiotherapy (SCPRT), to all patients with imaging predicted cN+ remains controversial in view of the poor accuracy if categorised by nodal size alone [19], and the lack of prognostic relevance of the preoperative MRI assessment of involved lymph nodes on the risk of local recurrence. This is particularly valid because data suggest a low risk of local recurrence if the surgeon routinely carries out good-quality TME and removes the mesorectal nodes *en bloc* [27, 51]. However, it is the responsibility of the surgeon to demonstrate that consistent, good-quality TME is being achieved.

**Locally advanced rectal cancers (>cT3b, and EMVI+).** For patients with LARC, treatment decisions regarding neoadjuvant therapy should be based on preoperative, MRI-predicted CRM ( $\leq 1$  mm), EMVI and more advanced T3 substages (T3c/T3d), which define the risk of both local recurrence and/or synchronous and subsequent metastatic disease [52, 53]. MRI also allows risk stratification in terms of the predicted required extent of surgery [37], and the achievement of a clear CRM ( $>1$  mm).

For resectable cancers, where there is no indication on MRI that surgery is likely to be associated with either an R2 or an R1 resection, standard TME should achieve a curative resection, and downstaging/downsizing is not necessary to achieve this. The use of CRT or SCPRT aims to reduce local recurrence. No differences in oncological outcomes between CRT and SCPRT were reported in two prospective studies offering preoperative therapy in unselected clinically determined T3/T4 or node-positive rectal cancer patients [54, 55]. The latter trial showed that CRT had significantly higher adverse events compared with SCPRT, with no statistically significant differences in postoperative complications [56]. Two phase III trials showed that SCPRT with delayed surgery is a useful alternative to conventional short-course RT with immediate surgery [57, 58], which is associated with significantly lower postoperative complications [57].

Previous recommendations aimed to reduce the overall risk of an involved CRM to  $< 3\%$  and local recurrence to (preferably)  $< 5\%$  in the population in whom curative treatment is intended [59]. Evidence from the UK CR07 trial suggests that, without RT, a local recurrence rate of 5% (27/543) can be achieved if a complete mesorectal excision is carried out with a negative CRM [27]. MDTs and surgeons are, therefore, required to audit their local recurrence rates. There are recognised long-term adverse consequences of surgery and RT. Symptoms such as chronic pain, faecal incontinence and sexual difficulties are reported in both sexes. Good communication between surgeons, clinicians and patients will optimise joint decision-making.

**Tumours with threatened resection margin.** The terms 'unresectable/borderline cancers' (i.e. cT4, with the resection

margin at risk, involved MRF or CRM+) are imprecise, but MRI can predict rectal cancers that are unlikely to be amenable to a curative resection without multivisceral resection, either because the tumour abuts or breaches the MRF or there is macroscopic tumour outside the MRF with local extension to pelvic side wall and sacrum or in terms of tumour spread involvement into the lateral compartment. In these circumstances, preoperative treatment is necessary to shrink the cancer back away from the threatened margin i.e. the MRF/CRM. Without preoperative treatment or in the case of no response, surgery is likely to lead to either an R1 or an R2 resection. For such patients, CRT has been shown to significantly increase the chance of performing an R0 resection compared with RT alone [60].

Treatment recommendations for rectal cancer are summarised in Figure 4. Recommended treatment options for primary rectal cancer without distant metastases are summarised in Table 6.

### Risk of recurrence according to postoperative histology

Historical studies prior to TME suggest that the postoperative histopathological features, which have an impact on the risk of local recurrence, include: pathological TNM stage, T substage (Table 3), CRM status, the number/proportion of involved lymph nodes, extracapsular extension, extranodal deposits, tumour differentiation, LVI, EMVI and PNI. Hence, it is recommended that pathologists review MRI scan reports when assessing EMVI status [61].

Histologically involved nodes have in the past been associated with a high risk of local recurrence. However, the risk of local recurrence is reduced if the quality of the mesorectal excision is good (i.e. with a complete, smooth mesorectum with no defects and no coning), ensuring removal of all mesorectal lymph nodes.

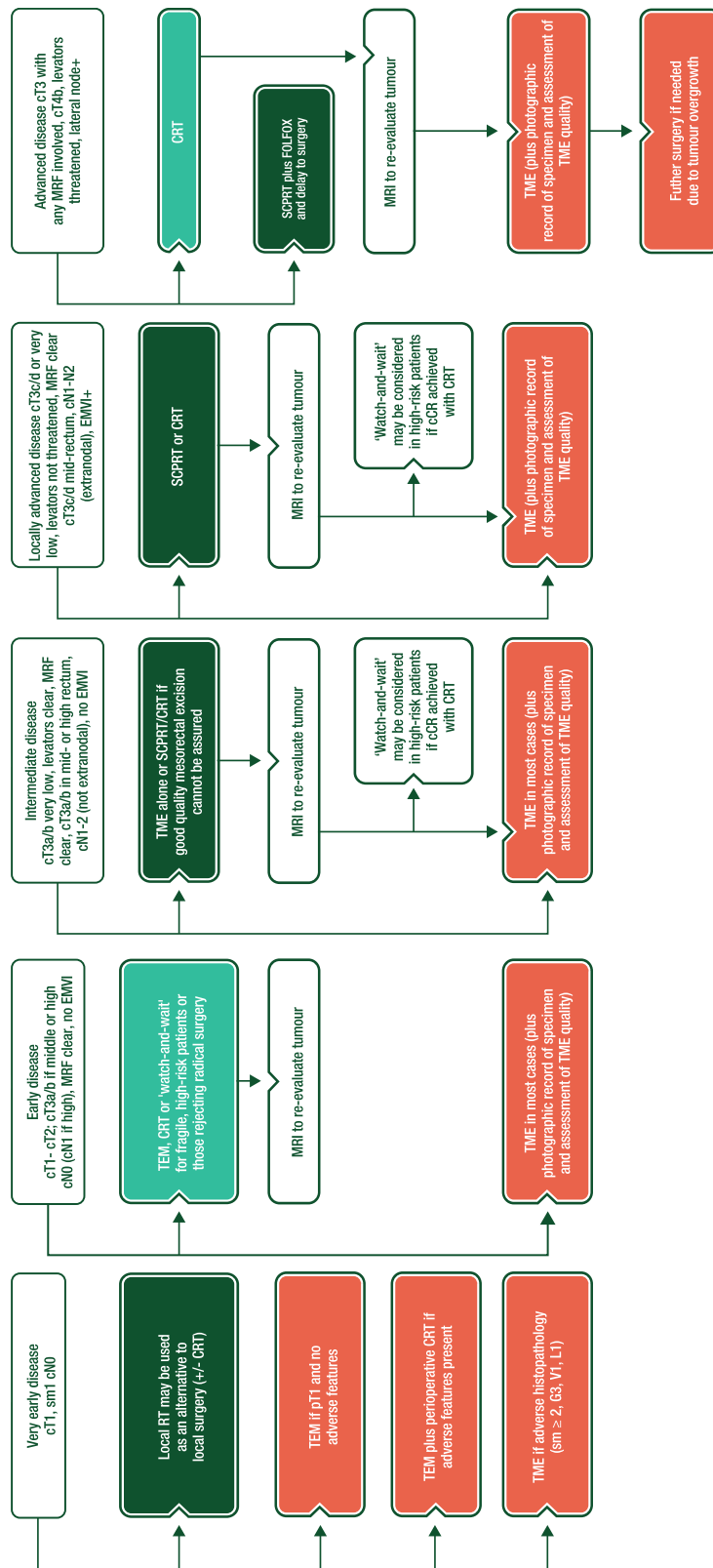
### Selection between short-course preoperative radiotherapy and long-course chemoradiotherapy

Two different schedules of preoperative therapy are standards of care:

- SCPRT with a 25 Gy total dose at 5 Gy/fraction during 1 week, followed by immediate surgery ( $< 10$  days from the first radiation fraction) [I, A]; SCPRT with delayed surgery is also a useful alternative to conventional short-course RT, with immediate surgery offering similar oncological outcomes and lower postoperative complications [57].
- CRT with a recommended dose of 45–50 Gy in 25–28 fractions; a boost with a further 5.4 Gy in 3 fractions can be considered for preoperative RT if the CRM is threatened, and for postoperative RT routinely with 5.4–9.0 Gy in 3–5 fractions according to CRM [I, A].

It is not possible to give a rigid definition of which T and N sub-stages require SCPRT or CRT. The selection of preoperative approach in LARC is based more regarding the risk of a CRM+ at TME surgery. If CRM and/or R0 resection status are predicted at risk, CRT is advised [60]. Otherwise, either SCPRT or CRT can be administered [I, A] [54, 55].

However, more recent evidence suggests that even if the predicted resection margin is at risk (CRM  $\leq 1$  mm, cT4 or fixed cT3 tumours), similar R0 resection rates and disease-free survival



**Figure 4.** Rectal cancer treatment. cCR, clinical complete response; CRT, chemoradiotherapy; EMVI, extramural vascular invasion; FOLFOX, leucovorin/fluorouracil/oxaliplatin; MRF, mesorectal fascia; MRI, magnetic resonance imaging; RT, radiotherapy; SCPRT, short-course preoperative radiotherapy; TEM, transanal endoscopic microsurgery; TME, total mesorectal excision.

**Table 6. Recommended choice of treatment options within TNM risk category of primary rectal cancer without distant metastases**

Risk group	TN substage	Possible therapeutic options	Further considerations
Very early	cT1 sm1 N0 (on ERUS and MRI)	Local excision (TEM) If pT1 and no adverse features, TEM is sufficient If adverse histopathology (sm $\geq$ 2, G3, V1, L1), requires radical resection (TME) as standard	Alternatively, in the case of adverse features on pathology, TEM plus salvage (or adjuvant) CRT in perioperative high-risk patients (but unproven benefit—with high risk of local recurrence for pT2)
Early (Good)	cT1-cT2; cT3a/b if middle or high, N0 (or also cN1 if high), MRF clear, no EMVI	Surgery (TME) alone is standard. If unexpected poor prognostic signs on histopathology (CRM+, extranodal/N2), consider postoperative CRT/CT (see postoperative recommendations in Table 7)	For fragile, high-risk patients or those rejecting radical surgery (CRT with evaluation, local excision or if achieving cCR, 'watch-and-wait', organ preservation)
Intermediate	cT3a/b very low, levators clear, MRF clear or cT3a/b in mid- or high rectum, cN1-2 (not extranodal), no EMVI	Surgery (TME) alone is a standard only if good-quality mesorectal resection assured (and local recurrence $\leq$ 0.5% or, if not, preoperative SCPRT (5 $\times$ 5 Gy) or CRT followed by TME	If CRT is given and cCR is achieved, 'watch-and-wait' in high-risk patients for surgery may be considered
Bad	cT3c/d or very low localisation levators threatened, MRF clear cT3c/d mid-rectum, cN1-N2 (extranodal), EMVI+, limited cT4aN0	Preoperative SCPRT (5 $\times$ 5cGy) or CRT followed by TME, depending on need for regression	If CRT and cCR achieved, 'watch-and-wait' in high-risk patients may be considered
Advanced (Ugly)	cT3 with any MRF involved, any cT4a/b, lateral node+	Preoperative CRT followed by surgery (TME and more extended surgery if needed due to tumour overgrowth), or preoperative SCPRT (5 $\times$ 5 Gy) plus FOLFOX and delay to surgery	Alternatively, 5 $\times$ 5 Gy alone with a delay to surgery in fragile/elderly or in patients with severe comorbidity who cannot tolerate CRT

Other factors besides T and N stages are relevant, such as EMVI, MRF involvement, distance from the anus and sphincters, size of mesorectum and patient characteristics. Patient preferences are also important.

cCR, clinical complete response; CRM, circumferential resection margin; CRT, chemoradiotherapy; CT, computed tomography; EMVI, extramural vascular invasion; ERUS, endoscopic rectal ultrasound; FOLFOX, leucovorin/fluorouracil/oxaliplatin; MRF, mesorectal fascia; MRI, magnetic resonance imaging; SCPRT, short-course preoperative radiotherapy; TEM, transanal endoscopic microsurgery; TME, total mesorectal excision; TNM, tumour, node, metastasis.

(DFS) are achieved for CRT or SCPRT followed by ChT with oxaliplatin/leucovorin/fluorouracil prior to surgery [58].

Biological molecularly targeted agents have not been successfully integrated into CRT. Several meta-analyses indicated that oxaliplatin added to CRT may slightly increase pathological complete response (pCR) rates and DFS in selected patients, but also enhances acute toxicity [62]. Given the contradictory results and lack of a clear long-term oncological benefit in the seven randomised trials [63–72] testing this combination so far, oxaliplatin as a radiosensitiser is not currently recommended to be routinely added to fluoropyrimidine-based CRT [I, D]. Continuous intravenous infusions of 5-fluorouracil (5-FU) or oral capecitabine during CRT are recommended rather than bolus 5-FU [I, A] [63, 73].

In summary, preoperative RT or CRT reduces the rate of local recurrence without improvement of OS for mid/low stage II/III rectal cancers [I, A], but is associated with significantly worse intestinal and sexual functions after surgery [I, A].

Upper rectal cancers (>12 cm from the anal verge) above the peritoneal reflection do not benefit from preoperative SCPRT or CRT and should be treated as colon cancer [I, A]. Patients with cT4 tumours falling back into the pelvis might benefit from neoadjuvant CRT or neoadjuvant ChT (NACT) alone [IV, D].

## Radiotherapy field sizes

It is beyond the scope of these guidelines to present a detailed recommendation of field sizes for each T- and N-stage depending on the location within the rectum. Most current guidelines are based on a consensus of experts rather than being evidence-based. Widely encompassing nodal regions will be more appropriate for patients with advanced tumours for whom radical surgery is not intended, and smaller volumes for early cancers with the same plan.

## Preoperative (neoadjuvant) chemotherapy

Strategies using induction ChT before/after CRT or SCPRT and surgery are being investigated in multiple trials.

NACT alone using a fluoropyrimidine and oxaliplatin or combined with targeted agents has been proposed instead of preoperative CRT in cT3 tumours not threatening the CRM and cT4 tumours in the mid- and upper-rectum, with the aim of promptly treating potential micrometastases and individualising treatment options [72]. After NACT, pCR is achieved in some 25% of early stage cases. However, limited long-term oncological outcome data are available for more advanced stages, particularly with CRM

involvement; hence, NACT alone is not recommended for the treatment of localised, non-metastatic disease outside clinical trials.

### Reassessment/response assessment after preoperative (chemo)radiotherapy

**Assessment of the primary tumour response.** The standard methods of clinically re-assessing patients following preoperative therapy rely on clinical examination using DRE, proctoscopy, and re-imaging by MRI. These findings direct appropriate surgical strategy, the type of operation intended and the possibility of choosing a 'watch-and-wait' strategy.

**Clinical complete response and a 'watch-and-wait' approach.** Following CRT or SCPRT, a clinical complete response (cCR) can be obtained in 10%–40% of patients when assessed after an interval of 12 weeks from the start of treatment. The likelihood of achieving a cCR will depend partly on initial stage and currently unknown molecular factors. cCR has only partial concordance with pCR [74]. Although not universally agreed, a cCR is defined as the absence of any palpable tumour or irregularity at DRE, no visible lesion at rectoscopy except a flat scar, telangiectasia or whitening of the mucosa. These minimal criteria can be complemented by absence of any residual tumour in the primary site and draining lymph nodes on imaging with MRI or ERUS, and negative biopsies from the scar. An initially raised CEA level which returns to normal (< 5 ng/ml) after CRT is associated with an increased likelihood of cCR and pCR, and hence supports the opinion that a cCR has been achieved [IV, C].

Dedicated centres have reported encouraging oncological and functional outcome results for selected patients treated with standardised CRT and a non-operative strategy. However, such patients have been subjected to rigorous and meticulous follow-up, where MRI surveillance is available [75], and more frequent than routine surveillance (see below) to ensure that surgical salvage is feasible and timely.

Substantially more follow-up and larger numbers of patients treated within properly controlled prospective studies are needed to validate the 'watch-and-wait' approach. Ongoing experiences from large databases, such as the European Registry of Cancer Care (EURECCA) 'International Watch & Wait Database' [www.iwwd.org](http://www.iwwd.org) [50], will provide more information on its safety and efficacy, and help to select appropriate patients. Patients should be informed that the strategy remains unproven and that a small increased oncological risk of uncontrolled pelvic and metastatic disease exists, although the prognosis of patients with cCR is excellent even without surgery. A standardised protocol for intensive surveillance is, therefore, recommended.

**Patients planned for surgery.** In LARC, it is recommended to re-evaluate the primary tumour/CRM with MRI after CRT prior to resection to achieve clear margins [41, 76], although re-imaging after CRT may both underestimate (poor discrimination between residual tumour and radiation-induced fibrosis), and overestimate pathological response and T downstaging (tumour fragmentation).

Comparison of sequential MRIs provides MRI tumour regression grading (mriTRG), which can discriminate/determine good and poor responders and predict survival outcomes, even though

**Table 7. Potential indications for postoperative chemoradiotherapy if preoperative chemoradiotherapy not given**

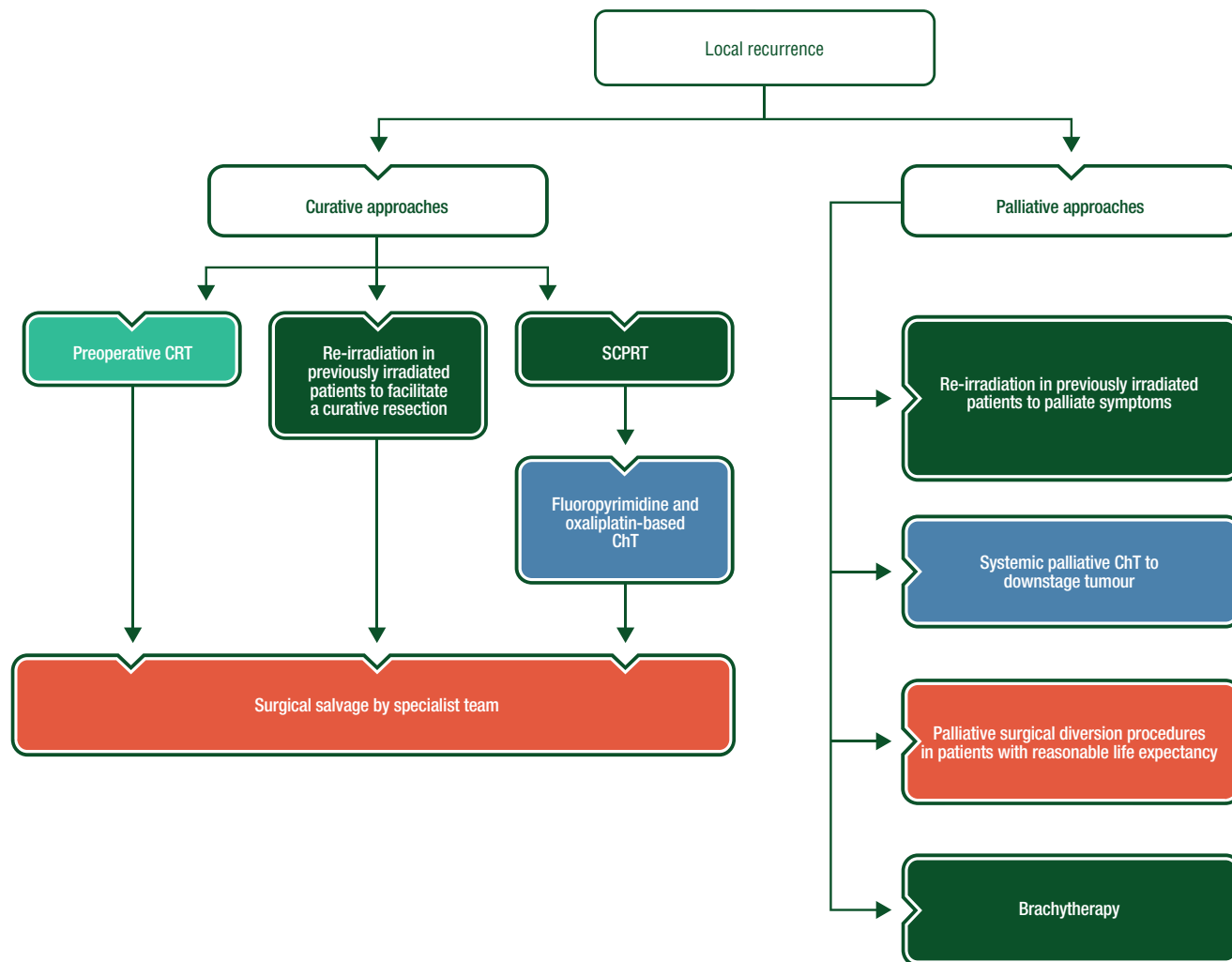
Sufficient and necessary	Insufficient and unnecessary
CRM ≤ 1 mm	pT1/pT2
pT4b	pT3
pN2 extracapsular spread close to MRF	CRM > 2 mm
Extranodal deposits (N1c)	pT4a above peritoneal reflection
pN2 if poor mesorectal quality/defects	pN1 If good quality smooth intact mesorectum
<b>Sufficient</b>	
pN2 low tumours within 4 cm of anal verge (risk of involved LPLN)	
Extensive extramural vascular invasion/perineural invasion close to MRF	
<b>Borderline sufficient</b>	
pN2 in mid/upper rectum if good mesorectal quality	
CRM 1–2 mm	
Circumferential obstructing tumours	
CRM, circumferential resection margin; LPLN, lateral pelvic lymph node; MRF, mesorectal fascia.	

inter-reader agreement has not been widely tested. mriTRG does not correlate well with histopathological TRG, and there is discordance with RECIST (response evaluation criteria in solid tumours) tumour measurements [77].

The additional value of diffusion-weighted imaging, gadofosveset-enhanced MRI or Apparent Diffusion Coefficient (ADC) measurements have not been validated. The value of CT in assessment of local response is relatively low. PET should not be routinely used as response tool, although reduction in uptake can be quantified. The relevance of these changes is not understood, and the extent of surgery should not be modified based on these findings [IV, D].

In the case of persistent potential CRM involvement on imaging following CRT, the consensus is that such patients should not undergo trial dissection but rather should be formally referred to a MDT with experience in multivisceral resection, so the treated tumour can be removed *en bloc* [78]. Further ChT may be useful for some but is unproven [79]. The ultimate decision should be made by the MDT. Difficulty in distinguishing between tumour and fibrosis on restaging MRI may lead to potential discordance between imaging and clinical findings at surgery.

**Distant metastases.** Routine restaging of chest and abdomen after neoadjuvant CRT is not recommended, but patients with more advanced cT4 cancers, threatened CRM and the presence of EMVI should be re-staged within 3 months of original staging to exclude metastatic disease prior to surgery. If metastatic disease is diagnosed, the patient should be re-evaluated by the MDT to determine appropriate management. Earlier stage tumours do not merit this practice unless clinical progression, including new



**Figure 5.** Rectal cancer treatment of local recurrence.

ChT, chemotherapy; CRT, chemoradiotherapy; RT, radiotherapy; SCPRT, short-course preoperative radiotherapy.

symptoms which may be related to metastasis or dramatically increased serum CEA, is observed.

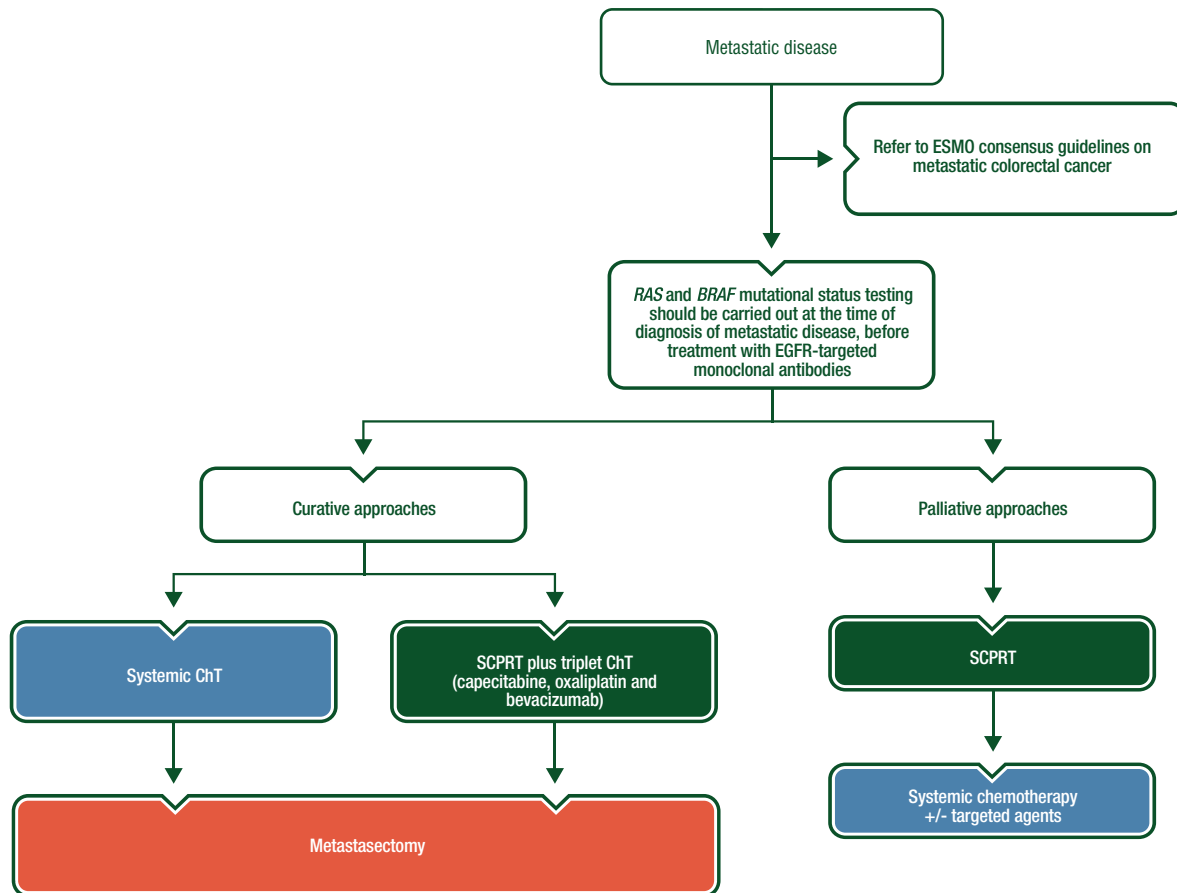
**Pathological assessment of response.** A pCR after CRT is associated with low rates of local and distant recurrence. A standardised definition of pCR is recommended [80]. Several tumour regression grades (TRGs) are in use, but interobserver agreement is limited. pCR is classified by Mandard as TRG1 but by Dworak as TRG5 [81, 82]. The optimal system (e.g. reproducibility and prognostic information) remains unclear; as a minimum, tumours should be graded as having either complete response, partial response or no response [IV, B]. Other dynamic histopathological features, i.e. amount of necrosis, regression of EMVI and downstaging of T and N stage, may also define outcomes.

**Interval to surgery.** The optimal timing of surgical resection of LARC after preoperative CRT or SCPRT remains controversial and is addressed in trials [83–89]. The ideal interval requires a balance between allowing sufficient time for the maximal effects

of the RT to be fully expressed (but before tumour repopulation) and for the acute reaction to settle so that surgery can be carried out safely.

In the case of SCPRT in resectable cancers, where downstaging is not required, ‘immediate’ surgery is recommended to take place within 7 days from the end of neoadjuvant treatment, and ideally within 0–3 days if the patient is  $\geq 75$  years (<10 days from the first radiation fraction) [I, A] [83, 86].

Longer intervals after SCPRT or CRT may enhance pCR rates (with unknown prognostic implications), but risks repopulation delays the use of postoperative systemic adjuvant ChT and risks subsequent metastases. In practice, there is a wide variation in the timing of surgery (4–12 weeks) due to patient/surgeon choice, recovery from treatment and/or waiting list issues. Prospective trials have been carried out, one randomising between 6 and 12 weeks and the other between 7 and 11 weeks after CRT. The latter shows that the longer interval does not increase cCR and is associated with higher surgical morbidity [84]. In contrast, preliminary results from the former suggest a significant increase in pCR [85].



**Figure 6.** Rectal cancer treatment of metastatic disease.

ChT, chemotherapy; EGFR, epidermal growth factor receptor; ESMO, European Society for Medical Oncology; SCPRT, short-course preoperative radiotherapy.

## Postoperative therapy

**Postoperative chemoradiotherapy.** Preoperative CRT (i.e. 45–54 Gy, 1.8–2.0 Gy/fraction) or SCPRT has better outcomes than postoperative CRT [87, 88]. Traditionally, postoperative CRT was administered for all patients with pT3–4 or pN+ tumours, and combined with additional 4 months of adjuvant bolus 5-FU ChT, but the routine use of CRT to reduce local recurrence can be questioned if a good-quality TME can be assured [53].

Postoperative CRT could be selectively used in patients with unexpected adverse histopathological features after primary surgery—e.g. positive CRM, perforation in the tumour area, incomplete mesorectal resection, extranodal deposits or nodal deposits with extracapsular spread close to the MRF, or in other cases with high risk of local recurrence if preoperative RT has not been given [I, A] (see Table 7).

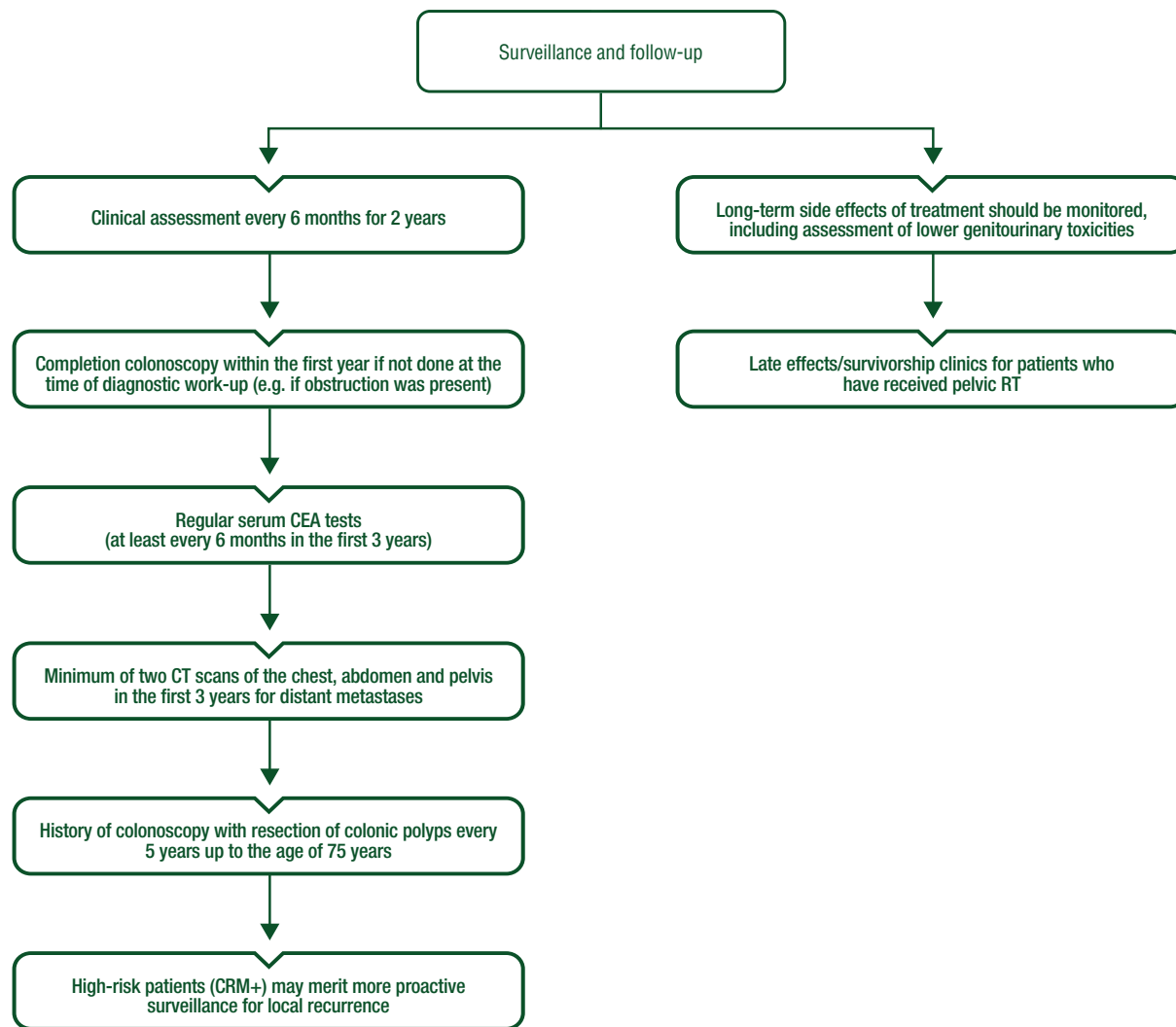
**Postoperative chemotherapy.** In colon cancer, adjuvant ChT has an established role for patients with ‘high-risk’ stage II and stage III disease. Patients with rectal cancer were specifically excluded from most phase III adjuvant studies because of the potential toxicity and confounding impact of RT or CRT. Postoperative pathological staging (ypTNM) can predict a high risk of

subsequent local and distant recurrence, but there is no automatic benefit from the use of adjuvant ChT.

After surgery alone for rectal cancer, individual trials and meta-analyses indicate that there is a benefit for adjuvant 5-FU-based ChT in terms of DFS and OS [89, 90], but the magnitude of benefit is smaller than for colon cancer. However, only few studies included in the meta-analysis-mandated TME surgery and/or preoperative RT/CRT. In contrast, following SCPRT or CRT, individual randomised trials [91–93] and meta-analyses [94] have not shown any benefit for 5-FU alone.

The addition of oxaliplatin to 5-FU may improve DFS [70, 95], but results are not consistent [96] and there is no effect on OS. A single randomised, phase II study suggests that adding oxaliplatin to 5-FU/leucovorin in a modified leucovorin/fluorouracil/oxaliplatin regimen (mFOLFOX6) improves relapse-free survival and OS in high-risk rectal cancers without downstaging after preoperative 5-FU-based CRT [97], but this data should not be used to recommend that all patients with ypN+ disease should receive oxaliplatin-based postoperative ChT.

It also remains unclear whether the initial clinical (yc) or pathological (yp) stage should be used to determine the risk/benefit of adjuvant treatment. In general, downgrading in T or N stage has been recognised more as a prognostic factor of favourable outcome rather than predictive biomarker for adjuvant treatment.



**Figure 7.** Rectal cancer surveillance and follow-up.

CEA, carcinoembryonic antigen; CRM, circumferential resection margin; CT, computed tomography; RT, radiotherapy.

Summarising, it is reasonable to consider adjuvant ChT in rectal cancer patients after preoperative CRT/RT with yp stage III (and ‘high-risk’ yp stage II). The level of scientific evidence for sufficient benefit is much lower than in colon cancer and is probably limited to DFS rather than to OS [II, C]. Hence, the decision on postoperative ChT (fluoropyrimidine alone or combined with oxaliplatin) should be risk-balanced, taking into account both the predicted toxicity for a particular patient and the risk of relapse, and should be made jointly by the individual and the clinician.

### Management of local recurrence

Local recurrence is less frequent with good-quality TME and preoperative RT/CRT. Recurrent pelvic tumour can cause severe pain, often requiring opiate and non-opiate pain relief with an offensive mucinous discharge and incontinence. Surgical salvage is complicated by the loss of the normal anatomical planes. Hence surgical salvage is recommended to be carried out by specialist teams.

If RT has not already been given, patients should be considered for standard-dose, preoperative CRT (45–50 Gy in 5–6 weeks)

[III, A] prior to an attempt at resection [60]. Alternatively, SCPRT followed by a fluoropyrimidine and oxaliplatin-based ChT as used in the Polish-2 study can be also applied [58].

In patients previously irradiated, re-irradiation to lower doses (with concomitant ChT is safe and can be used in selected patients to facilitate a curative resection or *per se* to palliate symptoms [IV, C] [98]. If salvage surgery is not currently an option, systemic palliative ChT may be used to downstage the tumour, although reports of efficacy are rare [V, C] [99]. Palliative surgical diversion procedures in patients with reasonable life expectancy are also recommended. Brachytherapy can be an effective palliative option [100]. See Figure 5.

### Management of advanced/metastatic disease

Metastatic rectal cancer stages are covered already in the ESMO consensus guidelines on metastatic colorectal cancer [13], but, in principle, should reflect the goals of treatment: tumour- and disease-related characteristics, patient-related factors (comorbidity,

**Table 8. Summary of recommendations****Staging and risk assessment**

- A history and physical examination including DRE, full blood count, liver and renal function tests, serum CEA and CT scan of thorax and abdomen should be carried out to define functional status and presence of metastases [III, A].
- Rigid rectoscopy and preoperative colonoscopy to the caecal pole are required, or, in the case of obstruction, virtual colonoscopy to exclude synchronous colonic tumours. If no preoperative (virtual) colonoscopy was carried out, completion colonoscopy is recommended within 6 months of surgery [III, A].
- Pelvic MRI is the most accurate test to define locoregional clinical staging. By detecting EMVI, and determining the T substage and distance to the CRM, it can predict the risks of synchronous/metachronous distant metastases, and should be carried out to select patients for the respective preoperative management and to define the extent of surgery [III, A].
- At least 12 regional lymph nodes should be examined. Proximal, distal and circumferential margins should be documented in millimetres (separately for tumour and involved lymph nodes). A proforma report such as the one by the Royal College of Pathologists is recommended [IV, B]. For mesorectal resections, histopathological examination should include a photographic record of the surgical specimen and assessment of TME quality [III, B], which is a strong quality control measure.

**Management of local/locoregional disease**

- Local excisional procedures such as TEM are appropriate as a single modality for early cancers (cT1N0 without adverse features like G3, V1, L1) [III, A]. Local RT (brachytherapy or contact therapy—Papillon technique) may also be used as an alternative to local surgery, alone or combined with CRT [III, C].
- More advanced tumours up to and including cT2c/T3a/b should be treated by radical TME surgery because of higher risks of recurrence and the higher risk of mesorectal lymph node involvement. The standard of care for surgery is TME, implying that all of the mesorectal fat, including all lymph nodes, should be meticulously excised [III, A].
- For patients with LARC, treatment decisions regarding neoadjuvant therapy should be based on preoperative, MRI-predicted CRM ( $\leq 1$  mm), EMVI and more advanced T3 substages (T3c/T3d), which define the risk of both local recurrence and/or synchronous and subsequent metastatic disease. For resectable cancers, where there is no indication on MRI that surgery is likely to be associated with either an R2 or an R1 resection, standard TME should achieve a curative resection. The use of CRT or SCPRT aims to reduce local recurrence.
- The selection of preoperative approach in LARC is based more on the MDT decision regarding the risk of a CRM+ at TME surgery. If CRM and/or R0 resection status are predicted at risk, CRT is advised. Otherwise, either SCPRT or CRT can be administered [I, A]. Continuous intravenous infusions of 5-FU or oral capecitabine during CRT are recommended rather than bolus 5-FU [I, A].
- Preoperative RT or CRT reduces the rate of local recurrence without improvement of OS for mid/low stage II/III rectal cancers [I, A], but is associated with significantly worse intestinal and sexual functions after surgery [I, A].
- Upper rectal cancers (>12 cm from the anal verge) above the peritoneal reflection do not benefit from preoperative SCPRT or CRT and should be treated as colon cancer [I, A].
- In the case of SCPRT in resectable cancers, where downstaging is not required, 'immediate' surgery is recommended to take place within 7 days from the end of neoadjuvant treatment, and ideally within 0–3 days if the patient is  $\geq 75$  years (<10 days from the first radiation fraction) [I, A].
- Postoperative CRT could be selectively used in patients with unexpected adverse histopathological features after primary surgery—e.g. positive CRM, perforation in the tumour area, incomplete mesorectal resection, extranodal deposits or nodal deposits with extracapsular spread close to the MRF, or in other cases with high risk of local recurrence if preoperative RT has not been given [I, A].

**Follow-up, long-term implications and survivorship**

- During follow-up, clinical examination, completion colonoscopy and pelvic imaging using MRI and/or CT and for distant metastases CT of the chest, abdomen and pelvis are recommended [V, B].  
A minimum provisional recommendation for average-risk patients is as follows:
  - Clinical assessment: every 6 months for 2 years [V, D].
  - A completion colonoscopy within the first year if not done at the time of diagnostic work-up (e.g. if obstruction was present) [I, A].
  - History and colonoscopy with resection of colonic polyps every 5 years up to the age of 75 years [I, B].
  - It is reasonable to offer a minimum of two CTs of the chest, abdomen and pelvis in the first 3 years and regular serum CEA tests (at least every 6 months in the first 3 years).
- High-risk patients (CRM+) may merit more proactive surveillance for local recurrence.

CEA, carcinoembryonic antigen; CRM, circumferential resection margin; CRT, chemoradiotherapy; CT, computed tomography; DRE, digital rectal examination; EMVI, extramural vascular invasion; 5-FU, 5-fluorouracil; LARC, locally advanced rectal cancer; MDT, multidisciplinary team; MRF, mesorectal fascia; MRI, magnetic resonance imaging; OS, overall survival; RT, radiotherapy; SCPRT, short-course preoperative radiotherapy; TEM, transanal endoscopic microsurgery; TME, total mesorectal excision.

socioeconomic factors and expectations of the patient), and treatment-related factors such as toxicity. See Figure 6.

Whether the primary tumour remains *in situ* and untreated may impact on the treatment strategy. ChT alone may be insufficient in those cases, and local palliation of rectal symptoms with RT may be required. SCPRT (if feasible) is preferred to CRT since systemic ChT can start within 2 weeks from the start of treatment.

This latter strategy palliates symptoms in ~80% of patients and avoids a salvage stoma for selected patients [101]. If the patient has a chance for cure (oligometastatic disease), the treatment should aim for rapid local control with effective systemic ChT and appropriate sequence/timing of metastasectomy. Single-institution series suggest that SCPRT can be safely combined with triplet ChT (capecitabine, oxaliplatin and bevacizumab) to

**Table 9. Levels of evidence and grades of recommendation (adapted from the Infectious Diseases Society of America–United States Public Health Service Grading System<sup>a</sup>)****Levels of evidence**

- I Evidence from at least one large randomised, controlled trial of good methodological quality (low potential for bias) or meta-analyses of well-conducted randomised trials without heterogeneity
- II Small randomised trials or large randomised trials with a suspicion of bias (lower methodological quality) or meta-analyses of such trials or of trials with demonstrated heterogeneity
- III Prospective cohort studies
- IV Retrospective cohort studies or case–control studies
- V Studies without control group, case reports, experts opinions

**Grades of recommendation**

- A Strong evidence for efficacy with a substantial clinical benefit, strongly recommended
- B Strong or moderate evidence for efficacy but with a limited clinical benefit, generally recommended
- C Insufficient evidence for efficacy or benefit does not outweigh the risk or the disadvantages (adverse events, costs, . . .), optional
- D Moderate evidence against efficacy or for adverse outcome, generally not recommended
- E Strong evidence against efficacy or for adverse outcome, never recommended

<sup>a</sup>By permission of the Infectious Diseases Society of America [108].

facilitate the resection of borderline resectable liver metastasis and the primary tumour [102]. There are no randomised studies, so the MDT should be responsible for critical decisions in patients with potentially curable metastatic disease.

### Personalised medicine

There are no molecular markers in rectal cancers available that can evaluate specific situations or treatments (e.g. whether a patient needs preoperative treatment for a localised or locally advanced rectal cancer, indicating that surgery will not be radical). Similarly, there are no known markers that can predict response to RT or CRT. Rectal cancers with distant metastases should be studied for *RAS* and *BRAF* mutational status and the other requirements addressed in the ESMO consensus guidelines on metastatic colorectal cancer [13].

### Follow-up, long-term implications and survivorship

Follow-up/surveillance with clinical examination, imaging and colonoscopy aims to improve prognosis by early detection and salvage of local recurrence and metastases, and to prevent/detect second colorectal cancers. See Figure 7.

Clinical examination and pelvic imaging using MRI and/or CT and for distant metastases CT of the chest, abdomen and pelvis are recommended [V, B]. Patients with rectal tumours (particularly more advanced stages) have a higher risk of recurrence and benefit more from follow-up [103], although <10% may have salvageable recurrence. Routine use of PET-CT as surveillance is not recommended, although when recurrence is diagnosed, PET-CT may be helpful for defining other unrecognised sites of disease.

CEA screening and CT monitoring increase the rate of surgical resection of recurrence with curative intent, although the optimum modality, intensity and frequency remain undefined [104,

105]. Isolated CEA monitoring is insufficiently sensitive [106]. Routine monitoring of CEA and CT imaging is only recommended up to 5 years following surgery.

Both rectal cancer surgery and the additional pre- or postoperative (C)RT may result in late sequelae, which impact daily function. Long-term side effects of treatment should be monitored. These include assessment of lower genitourinary toxicities (e.g. erectile dysfunction, dyspareunia and urinary incontinence).

An increased risk of developing a second primary cancer following RT for rectal cancer within or outside of the irradiated volume may have been overestimated [107]. However, with better treatments, increasing numbers of patients are living with the long-term consequences of surgery, ChT and RT—such as stomas, poor mobility, and attendant co-morbidity (osteopaenia, malabsorption, endocrinology problems and cardiovascular disease). Surveillance should address the social, financial and emotional aspects as well as practical and functional consequences to maximise survivors' long-term well-being. Important components include guidelines for the proactive detection of likely future effects and an educational program (before and after treatment) to promote engagement with the healthcare system and an appropriate and healthy lifestyle.

Evidence supports late effects/survivorship clinics for patients who have received pelvic RT.

A minimum provisional recommendation for average-risk patients is as follows:

- Clinical assessment: every 6 months for 2 years [V, D].
- A completion colonoscopy within the first year if not done at the time of diagnostic work-up (e.g. if obstruction was present) [I, A].
- History and colonoscopy with resection of colonic polyps every 5 years up to the age of 75 years [I, B].
- A minimum of two CTs of the chest, abdomen and pelvis in the first 3 years and regular serum CEA tests (at least every 6 months in the first 3 years).

High-risk patients (CRM+) may merit more proactive surveillance for local recurrence.

## Methodology

These Clinical Practice Guidelines were developed in accordance with the ESMO standard operating procedures for Clinical Practice Guidelines development <http://www.esmo.org/Guidelines/ESMO-Guidelines-Methodology>. The relevant literature has been selected by the expert authors. A summary of key recommendations is given in Table 8. Levels of evidence and grades of recommendation have been applied using the system shown in Table 9. Statements without grading were considered justified standard clinical practice by the experts and the ESMO Faculty. This manuscript has been subjected to an anonymous peer review process.

## Acknowledgements

RG-J would like to acknowledge the advice of Dr Bruce Mcfarlane, Dr Marcia Hall, CNS Angela Wheeler, and Dr Teresa Leverton. LW would like to express his gratitude to Dr Jacek Krynski and Pr Krzysztof Bujko for discussions on multimodality treatment of rectal cancer. AC is a member of CIBERONC, a research network of the Spanish National Institute of Health Charles III.

## Disclosure

RG-J has received honoraria for lectures from Roche, Sanofi, Merck Serono and Servier and for attending advisory boards from Eli Lilly, Roche, Servier, Eisai Amgen, Bristol-Myers Squibb and Mundipharma. He has received research funding for investigator-led phase II trials from Merck and Roche. LW has received honoraria for lectures from Amgen, Merck Serono, Roche and Servier and for advisory boards from Halozyme and Eisai. AC has received honoraria for lectures from Amgen, Roche, Merck Serono, Takeda and Servier and for advisory boards from Eli Lilly, Bayer, Roche, Merck Serono, Servier and Amgen; he has received research funding from Merck Serono, Eli Lilly, Bayer, Genentech and Roche. DA has reported research grants from Roche and Sanofi and has received honoraria for lectures from Roche, Merck Serono, Bayer and Servier and for advisory boards from Eli Lilly, Bayer, Roche, Merck Serono and Servier. ET, GB and CR have reported no potential conflicts of interest.

## References

- World Cancer Research Fund/American Institute for Cancer Research. Continuous Update Project Report Summary. Food, Nutrition, Physical Activity, and the Prevention of Colorectal Cancer 2011.
- Wei EK, Giovannucci E, Wu K et al. Comparison of risk factors for colon and rectal cancer. *Int J Cancer* 2004; 108: 433–442.
- Kirkegaard H, Johnsen NF, Christensen J et al. Association of adherence to lifestyle recommendations and risk of colorectal cancer: a prospective Danish cohort study. *BMJ* 2010; 341: c5504.
- Aleksandrova K, Pischon T, Jenab M et al. Combined impact of healthy lifestyle factors on colorectal cancer: a large European cohort study. *BMC Med* 2014; 12: 168.
- Murphy N, Norat T, Ferrari P et al. Dietary fibre intake and risks of cancers of the colon and rectum in the European prospective investigation into cancer and nutrition (EPIC). *PLoS One* 2012; 7: e39361.
- Balmaña J, Balaguer F, Cervantes A, Arnold D. Familial risk-colorectal cancer: ESMO Clinical Practice Guidelines. *Ann Oncol* 2013; 24 (Suppl 6): vi73–vi80.
- Cancer Genome Atlas Network. Comprehensive molecular characterization of human colon and rectal cancer. *Nature* 2012; 487: 330–337.
- Sadanandam A, Wang X, de Sousa E Melo F et al. Reconciliation of classification systems defining molecular subtypes of colorectal cancer. *Cell Cycle* 2014; 13: 353–357.
- Guinney J, Dienstmann R, Wang X et al. The consensus molecular subtypes of colorectal cancer. *Nat Med* 2015; 21: 1350–1356.
- Song N, Pogue-Geile KL, Gavin PG et al. Clinical outcome from oxaliplatin treatment in stage II/III colon cancer according to intrinsic subtypes: secondary analysis of NSABP C-07/NRG oncology randomized clinical trial. *JAMA Oncol* 2016; 2: 1162–1169.
- National Cancer Action Team. The characteristics of an effective multidisciplinary team (MDT), 2010. [www.ncin.org.uk/view?rid=136](http://www.ncin.org.uk/view?rid=136) (28 May 2017, date last accessed).
- Munro A, Brown M, Niblock P et al. Do multidisciplinary team (MDT) processes influence survival in patients with colorectal cancer? A population-based experience. *BMC Cancer* 2015; 15: 686.
- Van Cutsem E, Cervantes A, Adam R et al. ESMO consensus guidelines for the management of patients with metastatic colorectal cancer. *Ann Oncol* 2016; 27: 1386–1422.
- Papamichael D, Audisio RA, Glimelius B et al. Treatment of colorectal cancer in older patients: International Society of Geriatric Oncology (SIOG) consensus recommendations 2013. *Ann Oncol* 2015; 26: 463–476.
- Burdan F, Sudol-Szopinska I, Staroslawska E et al. Magnetic resonance imaging and endorectal ultrasound for diagnosis of rectal lesions. *Eur J Med Res* 2015; 20: 4.
- Brierley JD, Gospodarowicz MK and Wittekind C. (eds). *TNM Classification of Malignant Tumours*, 8th edition. Oxford: John Wiley & Sons, Inc. 2016.
- Zinicola R, Pedrazzi G, Haboubi N, Nicholls RJ. The degree of extramural spread of T3 rectal cancer: an appeal to the American Joint Committee on Cancer. *Colorectal Dis* 2017; 19: 8–15.
- Edge SB, Byrd DR, Compton CC (eds). *AJCC Cancer Staging Handbook*, 7th edition. New York: Springer 2010.
- Brown G, Richards CJ, Bourne MW et al. Morphologic predictors of lymph node status in rectal cancer with use of high-spatial-resolution MR imaging with histopathologic comparison. *Radiology* 2003; 227: 371–377.
- Liu Y, Wang R, Ding Y et al. A predictive nomogram improved diagnostic accuracy and interobserver agreement of perirectal lymph nodes metastases in rectal cancer. *Oncotarget* 2016; 7: 14755–14764.
- Haggitt RC, Glotzbach RE, Soffer EE, Wruble LD. Prognostic factors in colorectal carcinomas arising in adenomas: implications for lesions removed by endoscopic polypectomy. *Gastroenterology* 1985; 89: 328–336.
- Kikuchi R, Takano M, Takagi K et al. Management of early invasive colorectal cancer. Risk of recurrence and clinical guidelines. *Dis Colon Rectum* 1995; 38: 1286–1295.
- Toh EW, Brown P, Morris E et al. Area of submucosal invasion and width of invasion predicts lymph node metastasis in pT1 colorectal cancers. *Dis Colon Rectum* 2015; 58: 393–400.
- Sigourakis G, Lanitis S, Gockel I et al. Transanal endoscopic microsurgery for T1 and T2 rectal cancers: a meta-analysis and meta-regression analysis of outcomes. *Am Surg* 2011; 77: 761–772.
- Ikematsu H, Yoda Y, Matsuda T et al. Long-term outcomes after resection for submucosal invasive colorectal cancers. *Gastroenterology* 2013; 144: 551–559.
- Hermanek P, Hermanek P, Hohenberger W et al. The pathological assessment of mesorectal excision: implications for further treatment and quality management. *Int J Colorectal Dis* 2003; 18: 335–341.
- Quirke P, Steele R, Monson J et al. Effect of the plane of surgery achieved on local recurrence in patients with operable rectal cancer: a prospective study using data from the MRC CR07 and NCIC-CTG CO16 randomised clinical trial. *Lancet* 2009; 373: 821–828.
- García-Granero E, Faiz O, Muñoz E et al. Macroscopic assessment of mesorectal excision in rectal cancer: a useful tool for improving quality control in a multidisciplinary team. *Cancer* 2009; 115: 3400–3411.

29. Kreis ME, Ruppert R, Ptok H et al. Preoperative magnetic resonance imaging to select patients with rectal cancer for neoadjuvant chemoradiation–interim analysis of the German OCUM Trial (NCT01325649). *J Gastrointest Surg* 2016; 20: 25–32.
30. Garlipp B, Ptok H, Schmidt U et al. Factors influencing the quality of total mesorectal excision. *Br J Surg* 2012; 99: 714–720.
31. Quirke P, Williams GT. *Minimum Dataset for Colorectal Cancer Histopathology Reports*. London: Royal College of Pathologists 1998.
32. Wittekind C, Compton C, Quirke P et al. A uniform residual tumor (R) classification: integration of the R classification and the circumferential margin status. *Cancer* 2009; 115: 3483–3488.
33. Ng CW, Lieske B, Tan KK. Routine histological sampling of doughnuts post oncologic anterior resection is not necessary. *Int J Colorectal Dis* 2014; 29: 843–845.
34. Bach SP, Hill J, Monson JR et al. A predictive model for local recurrence after transanal endoscopic microsurgery for rectal cancer. *Br J Surg* 2009; 96: 280–290.
35. Junginger T, Goenner U, Hitzler M et al. Long-term oncologic outcome after transanal endoscopic microsurgery for rectal carcinoma. *Dis Colon Rectum* 2016; 59: 8–15.
36. Stormes T, Wibe A, Nesbakken A et al. National early rectal cancer treatment revisited. *Dis Colon Rectum* 2016; 59: 623–629.
37. Gérard JP, Ortholan C, Benezery K et al. Contact X-ray therapy for rectal cancer: experience in Centre Antoine-Lacassagne, Nice, 2002–2006. *Int J Radiat Oncol Biol Phys* 2008; 72: 665–670.
38. Penna M, Hompes R, Arnold S et al. Transanal total mesorectal excision: international registry results of the first 720 cases. *Ann Surg* 2017; 266: 111–117.
39. Sun Y, Xu H, Li Z et al. Robotic versus laparoscopic low anterior resection for rectal cancer: a meta-analysis. *World J Surg Oncol* 2016; 14: 61.
40. Holm T, Ljung A, Häggmark T et al. Extended abdominoperineal resection with gluteus maximus flap reconstruction of the pelvic floor for rectal cancer. *Br J Surg* 2007; 94: 232–238.
41. Battersby NJ, How P, Moran B et al. Prospective validation of a low rectal cancer magnetic resonance imaging staging system and development of a local recurrence risk stratification model: the MERCURY II study. *Ann Surg* 2016; 263: 751–760.
42. Ishihara S, Kanemitsu Y, Muroto K et al. Oncological benefit of lateral pelvic lymph node dissection for rectal cancer treated without preoperative chemoradiotherapy: a multicenter retrospective study using propensity score analysis. *Int J Colorectal Dis* 2016; 31: 1315–1321.
43. Lezoche E, Baldarelli M, Lezoche G et al. Randomized clinical trial of endoluminal locoregional resection versus laparoscopic total mesorectal excision for T2 rectal cancer after neoadjuvant therapy. *Br J Surg* 2012; 99: 1211–1218.
44. Bujko K, Richter P, Smith FM et al. Preoperative radiotherapy and local excision of rectal cancer with immediate radical re-operation for poor responders: a prospective multicentre study. *Radiother Oncol* 2013; 106: 198–205.
45. Garcia-Aguilar J, Renfro LA, Chow OS et al. Organ preservation for clinical T2N0 distal rectal cancer using neoadjuvant chemoradiotherapy and local excision (ACOSOG Z6041): results of an open-label, single-arm, multi-institutional, phase 2 trial. *Lancet Oncol* 2015; 16: 1537–1546.
46. Gornicki A, Richter P, Polkowski W et al. Anorectal and sexual functions after preoperative radiotherapy and full-thickness local excision of rectal cancer. *Eur J Surg Oncol* 2014; 40: 723–730.
47. Morino M, Risio M, Bach S et al. Early rectal cancer: the European Association for Endoscopic Surgery (EAES) clinical consensus conference. *Surg Endosc* 2015; 29: 755–773.
48. Smith FM, Rao C, Oliva Perez R et al. Avoiding radical surgery improves early survival in elderly patients with rectal cancer, demonstrating complete clinical response after neoadjuvant therapy: results of a decision-analytic model. *Dis Colon Rectum* 2015; 58: 159–171.
49. Bugg WG, Andreou AK, Biswas D et al. The prognostic significance of MRI-detected extramural venous invasion in rectal carcinoma. *Clin Radiol* 2014; 69: 619–623.
50. Van de Valk M. The International Watch and Wait database (IWWD) for rectal cancer: an update. *J Clin Oncol* 2017; 35 (Suppl 4S): abstr 521.
51. Taylor FG, Quirke P, Heald RJ et al. Preoperative high-resolution magnetic resonance imaging can identify good prognosis stage I, II, and III rectal cancer best managed by surgery alone: a prospective, multicenter, European study that recruited consecutive patients with rectal cancer. *Ann Surg* 2011; 253: 711–719.
52. Hunter CJ, Garant A, Vuong T et al. Adverse features on rectal MRI identify a high-risk group that may benefit from more intensive preoperative staging and treatment. *Ann Surg Oncol* 2012; 19: 1199–1205.
53. Taylor FG, Quirke P, Heald RJ et al. Preoperative magnetic resonance imaging assessment of circumferential resection margin predicts disease-free survival and local recurrence: 5-year follow-up results of the MERCURY study. *J Clin Oncol* 2014; 32: 34–43.
54. Bujko K, Nowacki MP, Nasierowska-Guttmejer A et al. Long-term results of a randomized trial comparing preoperative short-course radiotherapy with preoperative conventionally fractionated chemoradiation for rectal cancer. *Br J Surg* 2006; 93: 1215–1223.
55. Ngan SY, Burmeister B, Fisher RJ et al. Randomized trial of short-course radiotherapy versus long-course chemoradiation comparing rates of local recurrence in patients with T3 rectal cancer: Trans-Tasman Radiation Oncology Group Trial 01.04. *J Clin Oncol* 2012; 31: 3827–3833.
56. Ansari N, Solomon MJ, Fisher RJ et al. Acute adverse events and post-operative complications in a randomized trial of preoperative short-course radiotherapy versus long-course chemoradiotherapy for T3 adenocarcinoma of the rectum: Trans-Tasman Radiation Oncology Group Trial (TROG 01.04). *Ann Surg* 2017; 265: 882–888.
57. Erlandsson J, Holm T, Pettersson D et al. Optimal fractionation of preoperative radiotherapy and timing to surgery for rectal cancer (Stockholm III): a multicentre, randomised, non-blinded, phase 3, non-inferiority trial. *Lancet Oncol* 2017; 18: 336–346.
58. Bujko K, Wyrwicz L, Rutkowski A et al. Long-course oxaliplatin-based preoperative chemoradiation versus 5 × 5 Gy and consolidation chemotherapy for cT4 or fixed cT3 rectal cancer: results of a randomized phase III study. *Ann Oncol* 2016; 27: 834–842.
59. Glimelius B, Tiret E, Cervantes A et al. Rectal cancer: ESMO Clinical Practice Guidelines for diagnosis, treatment and follow-up. *Ann Oncol* 2013; 24 (Suppl 6): vi81–vi88.
60. Braendengen M, Tveit KM, Berglund A et al. Randomized phase III study comparing preoperative radiotherapy with chemoradiotherapy in nonresectable rectal cancer. *J Clin Oncol* 2008; 26: 3687–3694.
61. Chand M, Siddiqui MR, Swift I, Brown G. Systematic review of prognostic importance of extramural venous invasion in rectal cancer. *World J Gastroenterol* 2016; 22: 1721–1726.
62. Yang YJ, Cao L, Li ZW et al. Fluorouracil-based neoadjuvant chemoradiotherapy with or without oxaliplatin for treatment of locally advanced rectal cancer: an updated systematic review and meta-analysis. *Oncotarget* 2016; 7: 45513–45524.
63. O’Connell MJ, Colangelo LH, Beart RW et al. Capecitabine and oxaliplatin in the preoperative multimodality treatment of rectal cancer: surgical end points from National Surgical Adjuvant Breast and Bowel Project trial R-04. *J Clin Oncol* 2014; 32: 1927–1934.
64. Allegra CJ, Yothers G, O’Connell MJ et al. Neoadjuvant 5-FU or capecitabine plus radiation with or without oxaliplatin in rectal cancer patients: a phase III randomized clinical trial. *J Natl Cancer Inst* 2015; 107: pii: djv248.
65. Aschele C, Cionini L, Lonardi S et al. Primary tumor response to preoperative chemoradiation with or without oxaliplatin in locally advanced rectal cancer: pathologic results of the STAR-01 randomized phase III trial. *J Clin Oncol* 2011; 29: 2773–2780.
66. Aschele C, Lonardi S, Cionini L et al. Final results of STAR-01: a randomized phase III trial comparing preoperative chemoradiation with or without oxaliplatin in locally advanced rectal cancer. *J Clin Oncol* 2016; 34 (Suppl): abstr 3521.

67. Gérard JP, Azria D,ourgou-Bourgade S et al. Clinical outcome of the ACCORD12/0405 PRODIGE 2 randomized trial in rectal cancer. *J Clin Oncol* 2012; 30: 4558–4565.
68. Francois E, Gourgou-Bourgade S, Azria D et al. ACCORD12/0405-Prodige 2 phase III trial neoadjuvant treatment in rectal cancer: results after 5 years of follow-up. *J Clin Oncol* 2016; 34 (Suppl 4S): abstr 490.
69. Schmoll HJ, Haustermans K, Price TJ et al. Preoperative chemoradiotherapy and postoperative chemotherapy with capecitabine and oxaliplatin versus capecitabine alone in locally advanced rectal cancer: disease-free survival at interim analysis. *J Clin Oncol* 2014; 32 (Suppl): abstr 3501.
70. Rödel C, Graeven U, Fietkau R et al. Oxaliplatin added to fluorouracil-based preoperative chemoradiotherapy and postoperative chemotherapy of locally advanced rectal cancer (the German CAO/ARO/AIO-04 study): final results of the multicentre, open-label, randomised, phase 3 trial. *Lancet Oncol* 2015; 16: 979–989.
71. Jiao D, Zhang R, Gong Z et al. Fluorouracil-based preoperative chemoradiotherapy with or without oxaliplatin for stage II/III rectal cancer: a 3-year follow-up study. *Chin J Cancer Res* 2015; 27: 588–596.
72. Deng Y, Chi P, Lan P et al. Modified FOLFOX6 with or without radiation versus fluorouracil and leucovorin with radiation in neoadjuvant treatment of locally advanced rectal cancer: initial results of the Chinese FOWARC multicenter, open-label, randomized three-arm phase III trial. *J Clin Oncol* 2016; 34: 3300–3307.
73. Hofheinz RD, Wenz F, Post S et al. Chemoradiotherapy with capecitabine versus fluorouracil for locally advanced rectal cancer: a randomised, multicentre, non-inferiority, phase 3 trial. *Lancet Oncol* 2012; 13: 579–588.
74. Glynne-Jones R, Hughes R. Critical appraisal of the ‘wait and see’ approach in rectal cancer for clinical complete responders after chemoradiation. *Br J Surg* 2012; 99: 897–909.
75. Martens MH, Maas M, Heijnen LA et al. Long-term outcome of an organ preservation program after neoadjuvant treatment for rectal cancer. *J Natl Cancer Inst* 2016; 108: pii: djw171.
76. van der Paardt MP, Zagers MB, Beets-Tan RG et al. Patients who undergo preoperative chemoradiotherapy for locally advanced rectal cancer restaged by using diagnostic MR imaging: a systematic review and meta-analysis. *Radiology* 2013; 269: 101–112.
77. Siddiqui MR, Bhoday J, Battersby NJ et al. Defining response to radiotherapy in rectal cancer using magnetic resonance imaging and histopathological scales. *World J Gastroenterol* 2016; 22: 8414–8434.
78. Beyond TME Collaborative. Consensus statement on the multidisciplinary management of patients with recurrent and primary rectal cancer beyond total mesorectal excision planes. *Br J Surg* 2013; 100: E1–E33.
79. Sclafani F, Brown G, Cunningham D et al. Systemic chemotherapy (CT) as salvage treatment for locally advanced rectal cancer (LARC) patients (pts) who fail to respond to neoadjuvant chemoradiotherapy (CRT). *J Clin Oncol* 2017; 35 (Suppl 4S): abstr 709.
80. Loughrey MB, Quirke P, Shepherd NA, Royal College of Pathologists. Standards and Datasets for Reporting Cancers. Dataset for Colorectal Cancer Histopathology Reports July 2014, 3rd edition. <https://www.rcpath.org/asset/E94CE4A2-D722-44A7-84B9D6829413CFC/> (28 May 2017, date last accessed).
81. Mandard AN, Dalibar DF, Mandard JC. Pathological assessment of tumour regression after preoperative chemoradiotherapy of oesophageal carcinoma. Clinicopathologic correlations. *Cancer* 1994; 73: 2680–2686.
82. Dworak O, Kelholz L, Hoffman A. Pathological features of rectal cancer after preoperative radiochemotherapy. *Int J Colorectal Dis* 1997; 12: 19–23.
83. Pettersson D, Holm T, Iversen H et al. Preoperative short-course radiotherapy with delayed surgery in primary rectal cancer. *Br J Surg* 2012; 99: 577–583.
84. Evans J, Bhoday J, Sizer B et al. Results of a prospective randomised control 6 vs 12 trial: is greater tumour downstaging observed on post treatment MRI if surgery is delayed to 12-weeks versus 6-weeks after completion of neoadjuvant chemoradiotherapy?. *Ann Oncol* 2016; 27 (Suppl 6): vi149 (abstract 4520).
85. Lefevre JH, Mineur L, Kotti S et al. Effect of interval (7 or 11 weeks) between neoadjuvant radiochemotherapy and surgery on complete pathologic response in rectal cancer: a multicenter, randomized, controlled trial (GRECCAR-6). *J Clin Oncol* 2016; 34: 3773–3780.
86. van den Broek CB, Vermeer TA, Bastiaannet E et al. Impact of the interval between short-course radiotherapy and surgery on outcomes of rectal cancer patients. *Eur J Cancer* 2013; 49: 3131–3139.
87. Sauer R, Becker H, Hohenberger W et al. Preoperative versus postoperative chemoradiotherapy for rectal cancer. *N Engl J Med* 2004; 351: 1731–1740.
88. Sebag-Montefiore D, Stephens RJ, Steele R et al. Preoperative radiotherapy versus selective postoperative chemoradiotherapy in patients with rectal cancer (MRC CR07 and NCIC-CTG C016): a multicentre, randomised trial. *Lancet* 2009; 373: 811–820.
89. Quasar Collaborative Group, Gray R, Barnwell J et al. Adjuvant chemotherapy versus observation in patients with colorectal cancer: a randomised study. *Lancet* 2007; 370: 2020–2029.
90. Petersen SH, Harling H, Kirkeby LT et al. Postoperative adjuvant chemotherapy in rectal cancer operated for cure. *Cochrane Database Syst Rev* 2012; 3: CD004078.
91. Bosset JF, Calais G, Mineur L et al. Fluorouracil-based adjuvant chemotherapy after preoperative chemoradiotherapy in rectal cancer: long-term results of the EORTC 22921 randomised study. *Lancet Oncol* 2014; 15: 184–190.
92. Sainato A, Cernusco Luna Nunzia V, Valentini V et al. No benefit of adjuvant fluorouracil leucovorin chemotherapy after neoadjuvant chemoradiotherapy in locally advanced cancer of the rectum (LARC): long term results of a randomized trial (I-CNR-RT). *Radiother Oncol* 2014; 113: 223–229.
93. Breugom AJ, van Gijn W, Muller EW et al. Adjuvant chemotherapy for rectal cancer patients treated with preoperative (chemo)radiotherapy and total mesorectal excision: a Dutch Colorectal Cancer Group (DCCG) randomised phase III trial. *Ann Oncol* 2015; 26: 696–701.
94. Breugom AJ, Swets M, Bosset JF et al. Adjuvant chemotherapy after preoperative (chemo)radiotherapy and surgery for patients with rectal cancer: a systematic review and meta-analysis of individual patient data. *Lancet Oncol* 2015; 16: 200–207.
95. Zhao L, Liu R, Zhang Z et al. Oxaliplatin/fluorouracil-based adjuvant chemotherapy for locally advanced rectal cancer after neoadjuvant chemoradiotherapy and surgery: a systematic review and meta-analysis of randomized controlled trials. *Colorectal Dis* 2016; 18: 763–772.
96. Glynne-Jones R, Counsell N, Quirke P et al. Chronicle: results of a randomised phase III trial in locally advanced rectal cancer after neoadjuvant chemoradiation randomising postoperative adjuvant capecitabine plus oxaliplatin (XELOX) versus control. *Ann Oncol* 2014; 25: 1356–1362.
97. Hong YS, Nam BH, Kim KP et al. Oxaliplatin, fluorouracil, and leucovorin versus fluorouracil and leucovorin as adjuvant chemotherapy for locally advanced rectal cancer after preoperative chemoradiotherapy (ADORE): an open-label, multicentre, phase 2, randomised controlled trial. *Lancet Oncol* 2014; 15: 1245–1253.
98. Guren MG, Undseth C, Rektstad BL et al. Reirradiation of locally recurrent rectal cancer: a systematic review. *Radiother Oncol* 2014; 113: 151–157.
99. Alberda WJ, Haberkorn BC, Morshuis WG et al. Response to chemotherapy in patients with recurrent rectal cancer in previously irradiated area. *Int J Colorectal Dis* 2015; 30: 1075–1080.
100. Bishop AJ, Gupta S, Cunningham MG et al. Interstitial brachytherapy for the treatment of locally recurrent anorectal cancer. *Ann Surg Oncol* 2015; 22 (Suppl 3): S596–S602.
101. Tyc-Szczepaniak D, Wyrwicz L, Kepka L et al. Palliative radiotherapy and chemotherapy instead of surgery in symptomatic rectal cancer with synchronous unresectable metastases: a phase II study. *Ann Oncol* 2013; 24: 2829–2834.
102. van Dijk TH, Tamas K, Beukema JC et al. Evaluation of short-course radiotherapy followed by neoadjuvant bevacizumab, capecitabine, and

- oxaliplatin and subsequent radical surgical treatment in primary stage IV rectal cancer. *Ann Oncol* 2013; 24: 1762–1769.
103. Pugh SA, Shinkins B, Fuller A et al. Site and stage of colorectal cancer influence the likelihood and distribution of disease recurrence and post-recurrence survival: data from the FACS randomized controlled trial. *Ann Surg* 2016; 263: 1143–1147.
104. Baca B, Beart RW, Jr, Etzioni DA. Surveillance after colorectal cancer resection: a systematic review. *Dis Colon Rectum* 2011; 54: 1036–1048.
105. Primrose JN, Perera R, Gray A et al. FACS Trial Investigators. Effect of 3 to 5 years of scheduled CEA and CT follow-up to detect recurrence of colorectal cancer: the FACS randomized clinical trial. *JAMA* 2014; 311: 263–270.
106. Nicholson BD, Shinkins B, Pathiraja I et al. Blood CEA levels for detecting recurrent colorectal cancer. *Cochrane Database Syst Rev* 2015; 12: CD011134.
107. Martling A, Smedby KE, Birgisson H et al. Risk of second primary cancer in patients treated with radiotherapy for rectal cancer. *Br J Surg* 2017; 104: 278–287.
108. Dykewicz CA. Summary of the guidelines for preventing opportunistic infections among hematopoietic stem cell transplant recipients. *Clin Infect Dis* 2001; 33: 139–144.