

## CONFLITOS DE INTERESSE

Os autores declaram que não possuem conflitos de interesses.

## FONTES DE FINANCIAMENTO

Os autores declaram não ter recebido subsídios ou bolsas para a elaboração do artigo.

## REFERÊNCIAS

- Zaietta GA, Raval AA, Murillo L, Mehta J, Byrd RP Jr, Roy TM. Case report and review of the literature: spontaneous aortobronchial fistula. *Tenn Med.* 2013;106:39-42.
- Santiago S, Tobias J, Williams AJ. A reappraisal of the causes of hemoptysis. *Arch Intern Med.* 1991;151:2449-51.
- Hirshberg B, Biran I, Glazer M, Kramer MR. Hemoptysis: etiology, evaluation, and outcome in a tertiary referral hospital. *Chest.* 1997;112:440-4.
- Kazerooni EA, Williams DM, Abrams GD, Deeb GM, Weg JG. Aortobronchial fistula 13 years following repair of aortic transection. *Chest.* 1994;106:1590-4.
- Miyazaki M, Hiraga S, Kitamura M, Takamiya T, Iida T, Hida M, et al. Aortobronchial fistula complicated with an aortic aneurysm in hemodialysis patient. *Nephron.* 1990;56:101-2.
- Mac Intosh EL, Parrott JC, Unruh HW. Fistulas between the aorta and tracheobronchial tree. *Ann Thorac Surg.* 1991;51:515-9.
- Demeter SL, Cordasco EM. Aortobronchial fistula: Keys to successful management. *Angiology.* 1980;31:431-5.
- Szolar DH, Riepl T, Stiskal M, Preidler KW. Aortobronchial fistula as a late complication of posttraumatic chronic aortic aneurysm. *AJR Am J Roentgenol.* 1995; 164:1511-3.
- Milano A, De Carlo M, Mussi A, Falashi F, Bortolotti U. Aortobronchial fistula after coarctation repair and blunt chest trauma. *Ann Thorac Surg.* 1999;67:539-41.
- Coblentz CL, Sallee DS, Chiles C. Aortobronchopulmonary fistula complicating aortic aneurysm: diagnosis in four cases. *AJR.* 1988;150:535-8.
- Ono M, Takamoto S, Kawauchi M, Egami J, Kotsuka Y. Aortobronchial fistula late after transverse arch replacement. *Ann Thorac Surg.* 2000;70:964-6.
- Urschel JD. The diagnostic importance of computed tomography in aortobronchial fistula—A case report. *Angiology.* 1993;44:817-9.
- Agarwal P, Chughtai A, Matzinger F, Kazerooni EA. Multidetector CT of aortic thoracic aneurysms. *RadioGraphics.* 2009;29:537-52.
- Ferretti GR, Choplin RH, Haponik EF, Hudspeth AS. Case report. Aortic pseudoaneurysm with aortobronchial fistula: diagnosis with CT angiography. *J Comput Assist Tomogr.* 1996;20:975-8.
- Riesenman PJ, Brooks JD, Farber MA. Thoracic endovascular aortic repair of aortobronchial fistulas. *J Vasc Surg.* 2009;50:992-8.

## Endometrial Tuberculosis Simulating an Ovarian Cancer

## Tuberculose Endometrial Simulando um Carcinoma do Ovário



Silvia Eleonora DI GIOVANNI<sup>1</sup>, Teresa Margarida CUNHA<sup>2</sup>, Ana Luisa DUARTE<sup>3</sup>, Inês ALVES<sup>4</sup>  
 Acta Med Port 2016 Jun;29(6):412-415 - <http://dx.doi.org/10.20344/amp.7706>

## ABSTRACT

Female genital tuberculosis remains a major health problem in developing countries and is an important cause of infertility. As symptoms, laboratory data and physical findings are non-specific, its diagnosis can be difficult. We describe a case of a 39-year-old woman suffering from peri-umbilical pain and increased abdominal size for one year, anorexia, asthenia, weight loss, occasionally dysuria and dyspareunia, and four months amenorrhea. Laboratory data revealed cancer antigen 125 (CA-125) level of 132.3 U/mL, erythrocyte sedimentation rate of 42 mm/h, and gamma-globulins of 2.66 g/dL. Computer Tomography scan showed loculated ascites. It was initially suspected a carcinomatous origin, but ascites evaluation was negative for malignant cells. Magnetic Resonance Imaging from another hospital showed endometrial heterogeneity. Therefore, an endometrial biopsy was performed demonstrating an inflammatory infiltrate with giant cells of type Langhans and bacteriological culture identified *Mycobacterium tuberculosis*.

**Keywords:** Tuberculosis, Female Genital; Endometritis; Peritonitis, Tuberculosis; Ovarian Neoplasms.

## RESUMO

A tuberculose genital feminina continua a representar uma patologia importante nos países em desenvolvimento e constitui uma causa importante de infertilidade. Os seus sintomas, achados laboratoriais e exame físico não são específicos, tornando difícil o seu diagnóstico. Descrevemos o caso de uma doente do sexo feminino, de 39 anos, com dor peri-umbilical e aumento do volume abdominal desde há um ano, anorexia, astenia, perda ponderal, ocasionalmente disúria e dispareunia, assim como amenorria desde há quatro meses. Os dados laboratoriais mostraram valores de 132,3 U/mL do marcador tumoral CA-125, 42 mm/h de velocidade de sedimentação e 2,66 g/dL de gama-globulinas. A tomografia computadorizada mostrou ascite loculada. Inicialmente suspeitou-se de etiologia maligna, mas o exame citológico do líquido ascítico foi negativo para células malignas. Foi efectuada ressonância magnética pélvica, noutra instituição, que revelou heterogeneidade do endométrio. Foi então realizada biópsia endometrial que revelou um infiltrado inflamatório com células gigantes de Langhans e o exame bacteriológico isolou *Mycobacterium tuberculosis*.

**Palavras-chave:** Tuberculose Genital Feminina; Endometrite; Peritonite Tuberculosa; Neoplasia do Ovário.

1. Department of Radiological Sciences. Institute of Radiology. Catholic University of Sacred Heart. A. Gemelli Hospital. Rome. Italy.

2. Department of Radiology. Instituto Português de Oncologia de Lisboa. Lisboa. Portugal.

3. Department of Radiology. Hospital do Espírito Santo. Évora. Portugal.

4. Radiology Department. Hospital Central do Funchal. Funchal. Portugal.

✉ Autor correspondente: Silvia Eleonora Di Giovanni. sedg15@yahoo.it

Recebido: 07 de abril de 2016 - Aceite: 25 de maio de 2016 | Copyright © Ordem dos Médicos 2016



## INTRODUCTION

Tuberculosis (TB) is an important health problem in developing countries.<sup>1</sup> Genitourinary TB accounts for about 15% of all extra-pulmonary TB and, after lung, is the most common site.<sup>2</sup> The endometrium is involved in approximately 50-60% of women with female genital TB (FGTB).<sup>3-8</sup>

FGTB is typically asymptomatic and is usually diagnosed incidentally during infertility evaluation. Symptomatic disease usually presents with pelvic pain, and/or menstrual irregularities.<sup>3</sup>

The disease can mimic many conditions, including bowel disease, malignancy and other infectious diseases.<sup>2</sup> FGTB presenting as abdominal lump with raised Cancer Antigen 125 (CA-125) and ascites can be a differential diagnosis of advanced ovarian malignancy or disseminated peritoneal carcinomatosis.<sup>2</sup>

No laboratory test is sufficiently sensitive or specific to allow a diagnosis; however lymphocytosis, accelerated erythrocyte sedimentation rate (ESR) and increased gamma-globulin levels in blood can be found. The imaging findings are also not specific.<sup>4</sup>

Hysteroscopy provides direct information about endometrial integrity and may reveal a scarred atrophic endometrial layer with adhesions varying from mild to severe, leading to Asherman's syndrome and secondary amenorrhea.<sup>3</sup> However, histopathological evidence from biopsies of premenstrual endometrial tissue or the demonstration of tubercle bacilli in cultures of menstrual blood or endometrial curetting is necessary to provide a conclusive diagnosis of the disease.<sup>3-5,8</sup>

## CASE REPORT

A 39-year-old woman from Guinea-Bissau with abdominal mass and ascites suspected to be an ovarian cancer was referred to our hospital for diagnostic and therapeutic evaluation.

She reported peri-umbilical pain and increased abdominal size for one year; she also reported anorexia, asthe-

nia, weight loss, occasionally dysuria and dyspareunia, and amenorrhea for four months. The patient had no significant medical history. No history of TB in relatives was described. Physical examination detected ascites and left inguinal lymphadenopathy. The speculum examination was painless and unremarkable. Laboratory data revealed CA-125 serum level of 132.3 U/mL (reference range, 0-35 U/mL), ESR 42 mm/h (normal value < 30 mm/h), gamma-globulins 2.66 g/dL (normal range, 0.5-1.5 g/dL). Human Immunodeficiency Virus test was negative. The intradermal test injection of purified protein derivative had a maximum diameter of 15 mm. The chest X-ray (CRX) showed densification in the right lung base, likely due to fibrotic bands, with associated bronchiectasis.

A computer tomography (CT) scan was performed and revealed the presence of pseudocystic lesion in the abdomen, associated with smooth peritoneal thickening and omental fat stranding (Fig. 1).

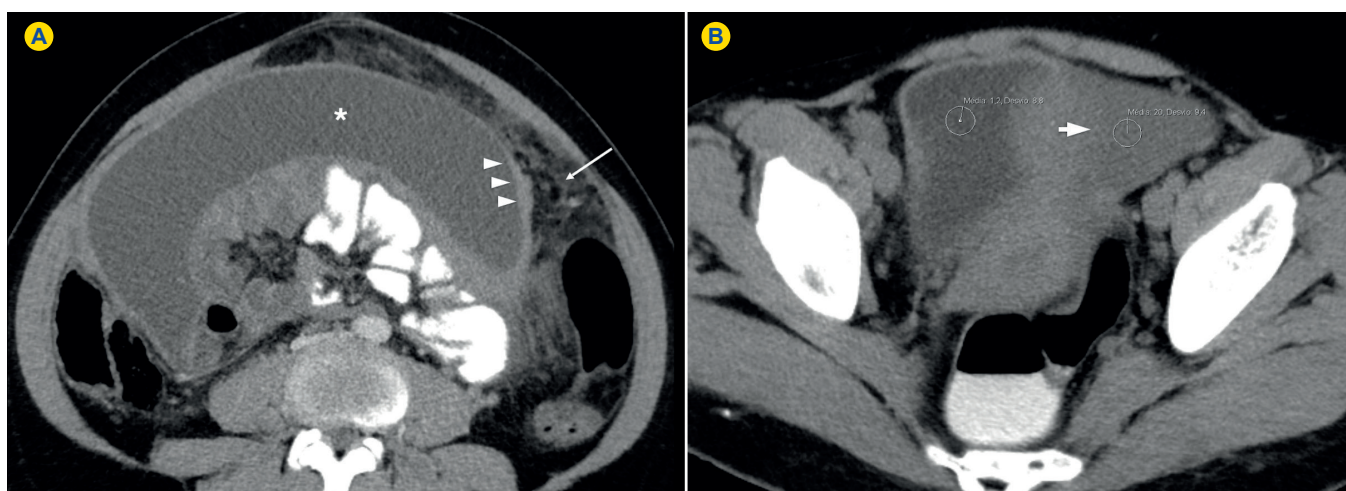
For the exclusion of an occult malignancy, gastrointestinal endoscopy and colonoscopy were performed and no significant findings were found. Drainage of the ascitic fluid was also performed and no malignant cells were detected nor bacteriological growth was observed.

The images of a previous magnetic resonance imaging (MRI) exam from another hospital were reevaluated, showing thickened and heterogeneous endometrium with an irregular surface (Fig. 2).

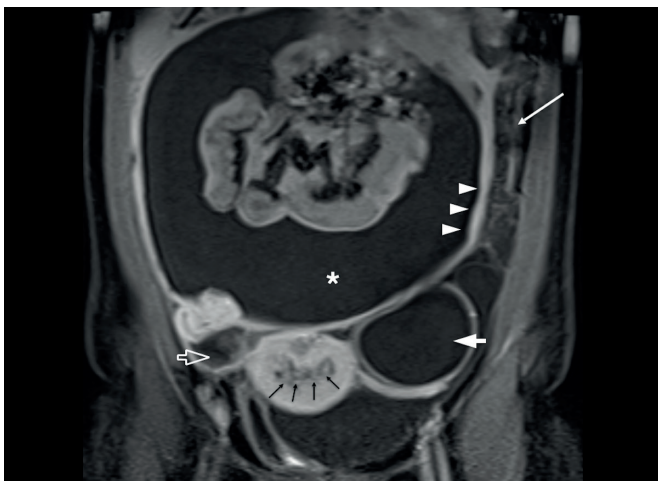
Therefore, hysteroscopy was performed and the endometrial biopsy revealed marked chronic necrotizing granulomatous inflammation with type Langhans giant cells. The bacteriological direct examination after Ziehl-Neelsen staining was negative, but bacteriological culture in Lowenstein-Jensen identified *Mycobacterium tuberculosis* complex.

## DISCUSSION

FGTB occurs secondary to primary disease in the



**Figure 1** - Endometrial Tuberculosis in a 39-year-old woman. Contrast-enhanced axial computed tomography image in the portal-venous phase (A) and unenhanced axial computed tomography image (B) after oral and rectal contrast administration (A, B) show ascites (asterisk in A) and smooth thickening of the peritoneum (arrowheads in A), associated with omental fat stranding (arrow in A). Note the slightly high attenuation of the ascitic fluid (20 Hounsfield Unit) compared to urine within the bladder (1.2 Hounsfield Unit) (thick arrow in B).



**Figure 2** - Endometrial Tuberculosis in a 39-year-old woman. Coronal gadolinium-enhanced fat-suppressed T1-weighted magnetic resonance imaging shows large amounts of ascites in the peritoneal cavity (asterisk), with smooth thickening and enhancement of the peritoneum (arrowheads) and omental thickening (white arrow). Simple cyst in the left ovary (thick arrow) and right-sided hydrosalpinx (open arrow) are also seen. Note the irregular myometrium/endometrium interface, with thickened and heterogeneous endometrium (black arrows).

lung, lymph nodes, urinary tract, bones, joints, and bowel. The spread is usually by the hematogenous or lymphatic route. Sexual transmission and direct spread from other intraperitoneal foci are very rare.<sup>1,4,7,8</sup>

The fallopian tubes are involved in 90-100% of the cases, endometrium in 50-60%, ovaries in 20-30%, and cervix in 5-15%.<sup>3-9</sup> TB of vagina and vulva is rare (1-2%).<sup>6,9</sup>

The highest prevalence (75% of all cases) is seen in the reproductive age group (20-45 years), with great impact on fertility.<sup>9,10</sup> It is rare in postmenopausal women and comprises 1% of postmenopausal bleeding cases.<sup>4,7,8,11</sup>

FGTB is often asymptomatic or presents with non-specific symptoms. Therefore, it is difficult to establish the true incidence, since many cases remain undiagnosed.<sup>4</sup>

When present, commonest initial findings are infertility (44%), pelvic pain (25%) and vaginal bleeding (18%);

less frequent symptoms are amenorrhea (5%), vaginal discharge (4%), and postmenopausal bleeding (2%). Rarely, it can manifest with ascites, abdominal mass, tubo-ovarian abscess and vague abdominal distention.<sup>4,8,9,11</sup>

Authors suggest that when ascites is present, it is indicative of tuberculous peritonitis (TBP).<sup>1</sup> As described in literature, there are three types of TBP: the wet type, that presents as either free or loculated ascites, associated or not with diffuse and smooth peritoneal thickening; the dry type, characterized by peritoneal and mesenteric thickening with caseous nodules, lymph nodes enlargement and fibrinous adhesions; finally, the fibrous type, that shows remarkable omental thickening and enlargement of bowel loops clinically resembling a mass.<sup>12,13</sup>

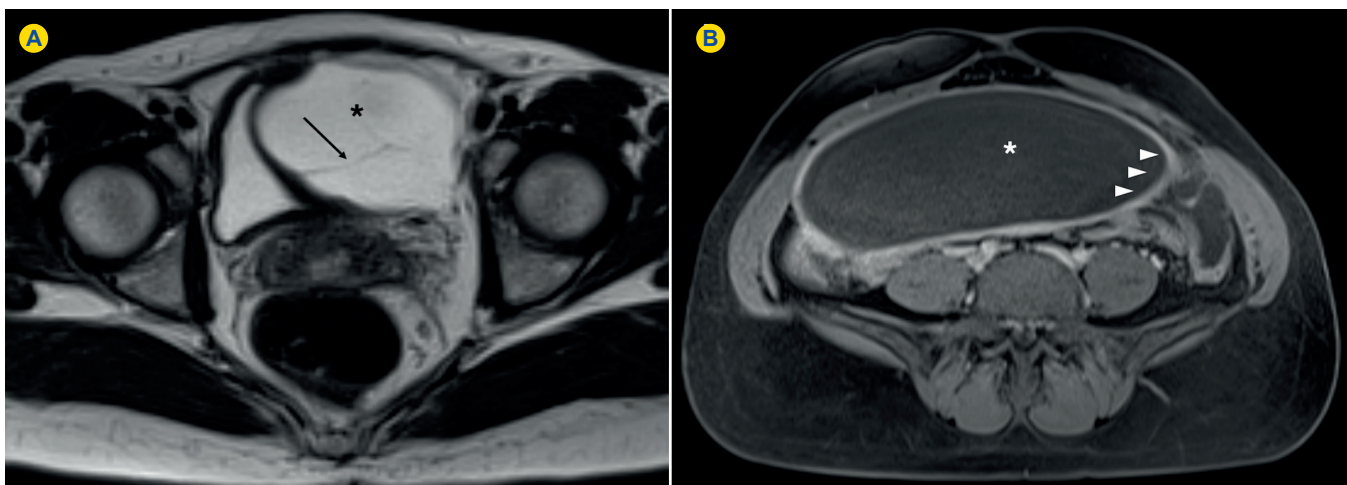
In our case, the presence of smooth and regular peritoneal thickening and lobulated ascites can be attributed to the wet type of TBP (Fig. 3).

In presence of these findings, the differential diagnosis with peritoneal carcinomatous can be difficult. Furthermore, since the laboratory findings are non-specific, they cannot provide an accurate diagnosis of FGTB; abdominal and gynecologic examinations may be normal, and CRX is also unremarkable in most cases, as in ours.

On hysterosalpingography, acute endometritis can be identified as irregularity of the contour of the endometrial cavity, while the presence of fibrosis, scarring, and calcifications are characteristics of the chronic form.<sup>10</sup> However, the final diagnosis of FGTB is obtained by the detection of *Mycobacterium tuberculosis*, either by direct microscopic examination or after positive cultures in pathological samples.<sup>3-5,8</sup> The sampling is obtained through endometrial biopsy, laparoscopy or laparotomy or, less frequently, hysterectomy.<sup>4</sup>

After treatment, reduction of ascites and CA-125 serum levels have been described, as well as abdominal distension and abdominopelvic mass resolution.<sup>2</sup>

In conclusion, the diagnosis of FGTB remains a challenge, due to the wide range of clinical presentations, non-specific laboratory findings and the superimposition of



**Figure 3** - Wet type tuberculous peritonitis. Axial T2-weighted magnetic resonance imaging (A) and gadolinium-enhanced fat-suppressed T1-weighted magnetic resonance imaging (B) show loculated ascites (asterisk in A and B) and thin septa within the ascitic fluid (black arrow in A). Note the diffuse, smooth and regular peritoneal thickening with marked contrast uptake after intravenous contrast injection (arrowheads in B).

imaging findings with other diseases, particularly peritoneal carcinomatosis. However, in patients in childbearing age presenting with abdominal mass and ascites, particularly if coming from a developing country, FGTB should be considered.

#### PROTECTION OF HUMANS AND ANIMALS

The authors declare that the procedures were followed according to the regulations established by the Clinical Research and Ethics Committee and to the Helsinki Declaration of the World Medical Association.

#### REFERENCES

- Sahin H, Isik H, Uygun Ilikhan S, Tanriverdi H, Bilici M. Disseminated tuberculosis in a non immun compromised patient with a complicated diagnosis. *Respir Med Case Rep.* 2014;14:1-3.
- Noor S, Nahar N, Bilkis A, Jabin T. Abdomino Pelvic Tuberculosis Versus Advanced Ovarian Malignancy: A Diagnostic Dilemma. *Chatt Maa Shi Hosp Med Coll J.* 2015;14:65-9.
- Nabag WO, Nur Hassan A, Sayed DM, El Sheikh MA. Endometrial Tuberculosis and Secondary Amenorrhea: A Report of Three Cases in Sudan. *J Minim Invasive Surg Sci.* 2012;1:30-3.
- Elbahraoui H, Elmazghi A, Bouziane H, Elghanmi A, Lakhdar A, Ferhati D. Post-menopausal tuberculous endometritis simulating endometrial cancer: report of a case. *Pan Afr Med J.* 2012;11:7.
- Errarhay S, Hmidani N, Fatmi H, Saadi H, Bouchikhi C, Amarti A, et al. Post-menopausal endometrial tuberculosis mimicking carcinoma: An important differential diagnosis to consider. *Int J Mycobacteriol.* 2013;2:118-20.
- Sharma JB. Current Diagnosis and Management of Female Genital Tuberculosis. *J Obstet Gynaecol India.* 2015;65:362-71.
- Mondal SK. Histopathologic analysis of female genital tuberculosis: a fifteen-year retrospective study of 110 cases in eastern India. *Turk Patoloji Derg.* 2013;29:41-5.
- Güngördük K, Ulker V, Sahbaz A, Ark C, Tekirdag AI. Postmenopausal tuberculosis endometritis. *Infect Dis Obstet Gynecol.* 2007;2007:27028.
- Ramilo I, Caeiro F, Mendinhos G, Santos AP, Pereira J. Tuberculose do aparelho reprodutivo feminino: experiência de 10 anos. *Rev Port Doenc Infec.* 2014;2:62-9.
- Shah HU, Sannananja B, Baheti AD, Udare AS, Badhe PV. Hysterosalpingography and ultrasonography findings of female genital tuberculosis. *Diagn Interv Radiol.* 2015;21:10-5.
- Júlio C, Amaral N, Biscaia I, Torrezão I, Fatela A. Tuberculose genital: uma causa rara de hemorragia pós-menopausa. *Acta Med Port.* 2010;4:723-6.
- Rocha EL, Pedrassa BC, Bormann RL, Kierszenbaum ML, Torres LR, D'Ippolito G. Abdominal tuberculosis: a radiological review with emphasis on computed tomography and magnetic resonance imaging findings. *Radiol Bras.* 2015;48:181-91.
- Burrill J, Williams CJ, Bain G, Conder G, Hine AL, Misra RR. Tuberculosis: a radiologic review. *RadioGraphics.* 2007;27:1255-73.

#### DATA CONFIDENTIALITY

The authors declare having followed the protocols in use at their working center regarding patient's data publication.

#### CONFLICTS OF INTEREST

The authors declare that there are no conflicts of interest.

#### FUNDING SOURCES

No subsidies or grants contributed to this work.