



ESCOLA UNIVERSITÁRIA VASCO DA GAMA

MESTRADO INTEGRADO EM MEDICINA VETERINÁRIA

SURGICAL MANAGEMENT OF KERATOMAS IN HORSES

A Retrospective study of 10 cases

João Diogo Sarabando Coelho Mendes

Coimbra, outubro de 2020



ESCOLA UNIVERSITÁRIA VASCO DA GAMA

MESTRADO INTEGRADO EM MEDICINA VETERINÁRIA

SURGICAL MANAGEMENT OF KERATOMAS IN HORSES
A Retrospective study of 10 cases

Coimbra, outubro 2020

João Diogo Sarabando Coelho Mendes

Aluno do Mestrado Integrado em Medicina Veterinária

Constituição do Júri

Presidente do Júri: Prof. Doutora Ana Calado

Arguente: Prof. Doutor Pedro Pinto Bravo

Orientador: Prof. Doutora Anabela Almeida

Orientador Interno

Prof. Doutora Anabela Almeida

Coorientador Interno

Mestre Ricardo Campos

Orientadores Externos

Dr. Gregory S. Staller, DVM

(Running 'S' Equine Veterinary Services)

Dr. João Araújo

(Hospital Veterinário Bom Jesus)

*Dissertação de Estágio Curricular do Ciclo de Estudos Conducente ao Grau de Mestre em Medicina
Veterinária da EUVG*

Acknowledgments

I would like to thank my family for all the efforts so that my entire journey, from the degree in Veterinary Nursing, to the culmination of the Veterinary Medicine course was possible. I thank my Mother for the dialogues in less good situations and for the fact that she has never given up on encouraging me. To my Father for the constant availability for all my needs. To my Sister for her help in exam times, availability and sharing of information, and also for the conversations and meetings between friends.

To my Uncle Joaquim Padilha and my Grandfather Joaquim Mendes, who would certainly like to see me as a Veterinarian, I thank all the vast knowledge that they transmitted to me. To my Aunt Milú who so often “helped” me when I needed to sew my academic costume. To my Grandmother Alda and Aunt Natália for always making their essential goods available. To my Cousins Misé, Juca, Ana and Rodrigo and Gabriel, and to Joana and Marco, for always showing interest in my academic path.

I thank all my teachers at the Escola Superior Agrária de Viseu, because without them my course would not have been the same, for sure, and that I still have the privilege of keeping in touch.

I am particularly grateful to all the members of Tunadão 1998, for the countless nights of socializing, shared knowledge, music and fundamentally for the friendships that started there and will stay forever.

I would like to thank Dr. André Santos for making himself available to “welcome” me at his Veterinary Center, since the beginning of my journey, in order to be able to carry out my mini-internships. For all the experience I acquired, for all the knowledge, tips and for having the opportunity to put them into practice. Without it, there would not have been the necessary impetus to start the Veterinary Medicine course. To Miguel Maia, Rodrigo Torres and Diana Maria especially for all the good times.

To Dr. Greg Staller, for having welcomed me into his residence and clinic, and for all the valuable teachings that I will certainly take with me, both professionally and personally, and which made this thesis possible by giving me all the data on this topic. Thanks also to the entire RSEVS work team and to Catherine Haddad for their hospitality and friendliness. Without forgetting the person who made my internship in the USA possible, I thank Roberto Brasil who put me in contact with Dr. Greg.

To all the fantastic people who welcomed me during this period on the American continent, more specifically to the Portuguese community that is emigrated there. Alexandre Brás and family, Diogo Marques and family, Licínio, Clotilde, Brian and the rest, were fantastic people with whom I had the pleasure to deprive.

To Dr. João Araújo and all the staff of Hospital Veterinário Bom Jesus for my internship.

Last but not least, a sincere thanks to all the teachers and employees of the Vasco da Gama University School, in particular to Dr. Anabela Almeida, my internship supervisor, for the availability shown whenever requested by me, and also to Dr. Ricardo Campos.

Contents

Acknowledgments	iii
List of figures	v
List of tables	vi
List of acronyms and abbreviations	vi
Titlepage	1
Abstract	2
Keywords	2
Resumo	3
Palavras-chave.....	3
1. Background	4
2. Materials and methods	6
2.1. Animals	6
2.2. Diagnostic Examination	6
2.3. Surgical treatment.....	7
2.4. Outcomes Evaluation.....	8
3. Results	9
3.1. Clinical Examination Findings	9
3.3. Outcome Evaluation Results	12
4. Discussion	13
5. Conclusions	15
6. References	16
Annex 1	I
Table 1. Answers of the horses' owners to the website survey	I
Table 2. Case reports, retrospective studies and case series about keratoma	II

List of figures

Figure 1 – Representative example of the size of a keratoma.....7

Figure 2 – Two examples of the radiographic appearance of keratomas.....11

Figure 3 – Images of the clinical examination finding, radiograph, intraoperative evidence of the keratoma and the postsurgical of the horse number 3.....12

List of tables

Table 1 – Demographic characterization of the target population (n=10), including affected limbs.....8

Table 2 - Clinical data, diagnosis and outcomes of the cases of keratoma.....10

List of acronyms and abbreviations

CT – Computed Tomography

DLPMO - Dorsolateral-Palmaro/Plantaromedial Oblique

DMPLO - Dorsomedial-Palmaro/Plantarolateral Oblique

DP – Dorsopalmar/plantar

DPPDO - Dorsoproximal-Palmarodistal Oblique

DW - Danish Warmblood

HT - Hoof Tester

LM – Lateromedial

MRI – Magnetic Resonance Imaging

P3 – Distal Phalanx

TB – Thoroughbred

YO – Years Old

SURGICAL MANAGEMENT OF KERATOMAS IN HORSES
A Retrospective study of 10 cases

João Mendes^a, Gregory S. Staller^b, Ricardo Campos^a, Anabela Almeida^{a, c}

^aCentro de Investigação Vasco da Gama (CIVG) / Veterinary Sciences Department. Escola Universitária Vasco da Gama, Av. José R. Sousa Fernandes 197, Campus Universitário- Bloco B, Lordemão, 3020-210, Coimbra, Portugal (joasarabandomendes@gmail.com); (rbrascampos@gmail.com); (almeida.anabela@gmail.com)

^bRunning 'S' Equine Veterinary Services (RSEVS), 118 Fairmount Road West, Califon, New Jersey 07830 (USA)
(greg.staller@runningsequine.com; info@runningsequine.com)

^cCoimbra Institute for Biomedical Imaging and Translational Research (CIBIT), University of Coimbra, Edifício do ICNAS, Polo 3 Azinhaga de Santa Comba, 3000-548 Coimbra, Portugal.
(almeida.anabela@gmail.com)

Abstract

The keratoma is classified as a benign keratinized abnormal mass, generally situated between the hoof wall or sole of the horse's foot, that has the potential to negatively impact the horse's physical activity and performance. The condition has an unknown etiology and is considered rare. A keratoma can result in lameness which is indication for radiographic examination, which is used to identify the lesion before surgical treatment. Surgical treatment is based on partial resection of the hoof wall, for complete removal of the mass and surrounding affected tissues.

This retrospective study aimed to characterize equine keratoma in ten horses submitted to lameness investigation between July 2011 and August 2019 at the Running 'S' Equine Veterinary Services (New Jersey, United States of America). Thus, available data from clinical presentation, diagnostic approach (radiographic and histopathological findings), surgical treatment and clinical outcomes were considered.

In the present study, keratomas appeared mostly in geldings (90%) and in Thoroughbred-crosses or pure Thoroughbreds (70%), with the left hindlimb being the most affected. The postoperative outcomes were mostly favourable, with complications in 2 of the 10 horses (20%). The complications were solved with a second surgery. In balance, these outcomes suggested, as described previously, that the surgical technique used to remove the keratoma was useful to achieve resolution of the condition, with a low complication rate.

Additionally, considering the scarce data and few studies involving keratoma in horses, more studies should be carried out with a larger number of cases contributing to a better understanding of the conditions for its appearance.

Keywords

Equine, Keratin, Lameness, Partial resection.

Resumo

O queratoma é classificado como uma massa queratinizada, benigna e anormal, situada entre a parede do casco ou sola do dígito do cavalo, que tem a capacidade de afetar negativamente a sua atividade física e performance. Esta patologia tem uma etiologia desconhecida e é considerada rara. O queratoma pode resultar em claudicação, que é indicação para exame radiográfico, que por sua vez é utilizado para identificar a lesão antes do tratamento cirúrgico. Este tratamento é baseado na ressecção parcial da parede do casco, para remoção completa da massa e tecidos adjacentes afetados.

Este estudo retrospectivo teve como objetivo caracterizar o queratoma em dez cavalos submetidos a avaliação por claudicação, entre julho de 2011 e agosto de 2019, na Running 'S' Equine Veterinary Services (New Jersey, Estados Unidos da América). Para tal foram considerados todos os dados relativos à apresentação clínica, abordagem diagnóstica (achados radiográficos e histopatológicos) e tratamento cirúrgico e resposta ao tratamento.

No presente estudo, os queratomas apareceram majoritariamente em machos castrados (90%) e em cavalos da raça Puro-Sangue Inglês ou cruzados da mesma raça (70%), com o membro posterior esquerdo a ser o mais afectado. Os resultados pós-operatórios foram majoritariamente satisfatórios, com complicações em 2 dos 10 cavalos (20%). As complicações foram resolvidas com uma segunda intervenção cirúrgica. Em suma, esses resultados sugerem, conforme descrito por estudos prévios, que a técnica cirúrgica utilizada para remover o queratoma foi útil para atingir a resolução da condição, com um baixo índice de complicações.

Adicionalmente, considerando a escassez de dados e o baixo número de estudos prévios sobre queratoma equino, estudos adicionais devem ser considerados, envolvendo um maior número de animais, a fim de contribuir para um melhor entendimento sobre os fatores que podem levar ao seu aparecimento.

Palavras-chave

Equino, Claudicação, Queratina, Ressecção parcial.

1. Background

The equine foot is composed by the distal end of the second phalanx, the distal phalanx (P3) and the navicular bone, which are enclosed within the hoof capsule (O'Grady, 2008). The wall of the hoof and the sole are comprised by cornified epidermal tissue (horn). The coronary band is where the skin meets the hoof capsule, and is composed by a thickened dermis that surrounds the top of P3 around the hoof to form a ring of dermis, from which the hoof wall grows down to the ground (Davies & Philip, 2007). On the inner surface of the wall and sole there is the insensitive laminae (*stratum internum*), that interdigitates with the highly vascular sensitive laminae of the wall (laminar corium) and sole (solar corium). The white line, visible at the sole, is the junction of the insensitive laminae of the hoof wall and the horn of the sole (Honnas, 1991).

The keratoma has been described by many authors as a benign and uncommon keratin mass (Hall, 2015; Miller & Katzwinkel, 2015; Stashak, 1987), classified as a conical/cylindrical or spherical (Greet, 2016), that develops between the hoof wall and the P3 (Turner, 2016; Cullimore & Booth, 2010; Boys Smith et al., 2006). It is produced by epidermal keratin-producing cells of the coronary band or solar corium (Cullimore & Booth, 2010) and can originate from any point of the inner surface of the dorsal hoof wall or the sole (O'Grady & Horne, 2001). Keratoma was also described by McDiarmid (2007) from the corium of a horse's frog. Although the term "keratoma" may lead to the association of a neoplastic process, it is a hyperplasia or an abnormal regeneration of the superficial keratin of the hoof (Turner, 2016; Hamir et al., 1992).

The etiology of this keratinized mass is still unknown (Cullimore, 2010), although it may be related with chronic irritation, infection or trauma (Turner, 2016). A case report described a horse, referred for suspected keratoma growth based on a history of recurring abscesses in the foot, which was diagnosed through Computed Tomography (CT) with hyperplasia and hyperkeratosis of the laminar epidermis due to chronic inflammation (Tatarniuk *et al.*, 2013). The authors theorized that this abnormality might be an early stage of keratoma formation, and with time the lesion would develop into the usual appearance of a keratoma.

Keratomas can cause a mild to moderate lameness in several ways, as they can change the normal architecture of the coronary band when they grow between the interior of the hoof wall and the P3, creating a bulge or a deviation of the white line (Dabareiner, 2007; Turner, 2016). This mass may also leads to a disruption of the junction between the P3 and the hoof wall, causing consequently bacterial invasion of the area (Hall, 2015; Back et al., 2007). Although, in some cases, until the mass has grown down to the weight-bearing surface of the hoof, lameness does not become apparent due to its small size or location (Rowland et al., 2016; Dabareiner, 2007).

For the diagnosis in a lame horse, it is important to confirm that the pain is in the foot. Lameness can be localized to the foot using hoof testers and confirmed by perineural anaesthesia, often through an abaxial sesamoid nerve block (Eastman, 2015; Hall, 2015; Baxter & Stashak, 2011). Keratomas are an accumulation of keratin and are radiographically differentiated from the hoof wall and surrounding soft tissue (Getman et al., 2011). Radiography is the most commonly used diagnosis

approach (Gasiowski et al., 2011). Some authors argue that CT is not necessary for the diagnosis of keratoma (Gasiowski et al., 2011), however, CT and Magnetic Resonance Imaging (MRI) have been reported to be used to accurately identify the location and vascularity of keratomas in cases where radiography was not definitive (Anderson, 2013; Getman et al., 2011). After the surgical removal of the mass, it is also important to perform a histopathologic examination for definitive diagnosis (Hamir *et al.*, 1992).

Surgical treatment is indicated when a keratoma diagnosis is confirmed. Surgery entails partial resection of the hoof wall, in order to gain access to the mass and allow the complete removal of the keratoma, as well as the removal of surrounding reactive tissue or infection, if present (Baxter & Stashak, 2011; Boys Smith et al., 2006). These procedures can be performed either with the horse standing sedated under regional anaesthesia of the digit, or under general anaesthesia, depending on the surgeon's experience or the temperament of the horse (Honnas *et al.*, 2003). In the partial resection, the surgeon creates a small 'window' in the hoof wall, centred over the marked section, at the proximal extent of the abnormal tract. According to Boys Smith (2006) and collaborators, this 'window' could be enlarged intraoperatively or a second 'window' could be made through the sole, in order to gain complete access to ensure removal of all the abnormal tissues.

After the complete removal of the keratoma, sterile gauze soaked in sterile physiologic saline and povidone iodine solution should be applied on the surgical site, covered with a sterile bandage. Immediately after surgery, a large padded bandage is applied under pressure to control hemorrhage, as the wound created cannot be closed. Bandages should be regularly changed until healthy granulation tissue has filled the wall defect and has keratinized (Christman, 2008). In addition, the application of a stable and supportive shoe (generally a bar shoe with side clips) should be considered, in order to alleviate weight-bearing from the hoof wall at the surgical site and increase the stability of the wall. A hospital plate may be advocated in case of solar keratomas to protect the surgical site (Cullimore & Booth, 2010; Redding, 2007).

This retrospective study is aimed to describe and characterize the management of equine keratoma at the Running 'S' Equine Veterinary Services (New Jersey, United States of America), with emphasis on the clinical presentation and the surgical treatment, in order to contribute to a better understanding of this condition.

2. Materials and methods

2.1. Animals

This was a retrospective study enrolling ten horses that were presented to the Running 'S' Equine Veterinary Services (RSEVS), Califon, New Jersey (United States of America), between July 2011 and August 2019, for lameness investigation or referred specifically for keratoma confirmation and surgical excision. Horses were included if they had partial resection of the hoof wall to expose and remove the keratoma. The diagnosis was based on the clinical and radiological findings, at the time of the surgery. Only four cases had histologic confirmation of keratoma.

Parameters related with signalment and clinical characterization of the affected horses were considered in this study and obtained from the medical records, including breed, gender, age, weight and origin, affected limb, grade and duration of lameness (acute, with less than 1 month, or chronic, more than 1 month) and surgical treatment outcomes. The motive for consultation was also recorded and subcategorized as recurrent lameness, and chronic abscesses.

All owners consented to allow the use of clinical data from their horses for research purposes. This study was approved by the Scientific Council of Vasco da Gama University School, Coimbra, Portugal.

2.2. Diagnostic Examination

All horses were submitted to a complete general examination, performed by a Diplomate veterinary surgeon certified by the American College of Veterinary Surgeons. Clinical examination included the evaluation of the overall condition (body temperature, heart/pulse and respiratory rate, and body condition score), and a more specific musculoskeletal examination. This comprised a lameness exam, focusing ultimately on the affected digit. Examination of the foot includes evaluation of the quality of the digital pulse, percussion of the hoof wall, walk/trot out in hand in a straight line or in circles, careful examination with a hoof tester, and macroscopic evaluation of the digit. Lameness was graded on a 0 to 5 point scale (with 0 representing no detectable lameness; 5 representing non-weightbearing lameness), based on lameness scale of the American Association of Equine Practitioners (AAEP, 2020).

All horses underwent digital radiographic evaluation (Sound-Eklin EDR6 and Eklin EDR3 MkII; Sound-Eklin Medical Systems, Carlsbad, California, USA) with lateromedial (LM), 65° dorsopalmar/plantar (DP), dorsomedial-palmaro/plantarolateral oblique (DMPLO), 45° dorsolateral-palmaro/plantaromedial oblique (DLPMO), 65° dorsoproximal-palmarodistal oblique (DPPDO) views.

In four cases, samples of the mass and surrounding tissue were collected and submitted for histologic evaluation (Department of Biomedical Sciences of the Cornell University – Animal Health Diagnostic Center). Histopathology confirmed the presence of a keratoma in all samples.

2.3. Surgical treatment

The location of entry into the hoof wall was determined before the surgical preparation of the foot, using radiographs as a guide. For a “standing” procedure (6 horses) the horse was moved to a suitable environment and prepared for surgery. Regional anaesthesia of the digit was performed, through a nerve block at the level of the abaxial surface of the proximal sesamoid bones. The horse’s foot was clipped from the coronet band to four centimetres proximal to the metacarpophalangeal articulation and the periople was carefully removed from the hoof wall with a rasp. A tourniquet was placed at the level of the metacarpophalangeal joint, over the proximal sesamoid bones, palmarly. The digit was placed on a sterile drape on top of a wooden block to elevate it from the ground. A sterilized motorized rotary cutting tool (Dremel, Racine, Wisconsin, USA) fitted with a sterile steel cylindrical cutting burr was used to create a roughly circular hole through the hoof wall, with the most distal aspect approximately at the level of the solar margin of the distal phalanx, leaving roughly 12mm of hoof wall intact distal to the opening. When the hoof wall was penetrated and the insensitive laminae were encountered, the outline of the keratoma was generally evident. The keratoma could be identified as a discrete tapering bundle of keratinized fibres that is generally darker or lighter in colour than the surrounding tissue. The opening in the hoof wall was enlarged and elongated proximally to completely expose the mass, which could then be elevated and the keratoma removed (Figure 1).

Additional curettage and debridement was carried out until the keratoma and associated reactive and abnormal tissue was removed. Samples of tissue were collected for microbiologic culture. Affected distal phalangeal bone was curetted to hard, bleeding bone. The surgical site lavaged with sterile physiologic saline and the exposed area was packed with sterile gauze soaked in sterile physiologic saline and povidone iodine solution. Haemorrhage was controlled with pressure, so the defect was packed tightly. The entire foot was wrapped with sterile gauze saturated with povidone iodine solution and a padded foot wrap was applied.

Surgery under general anaesthesia was performed in 4 horses using essentially the same procedures, except that the horse was positioned in lateral recumbency with the appropriate aspect of the affected digit facing up. After surgery, broad-spectrum antibiotic therapy was initiated and anti-inflammatory treatment was instituted.

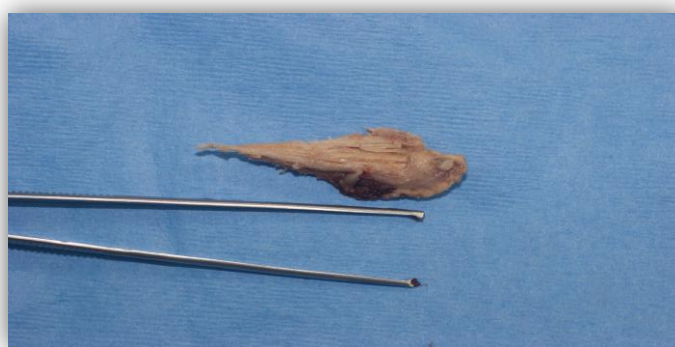

Figure 1. Representative example of the size of a keratoma. (Image kindly provided by Dr. Greg Staller, RSEVS)

The post-surgical bandage remained in place for 48-72 hours. After that time, the wound packing was removed and the operative site was inspected. A similar bandage was replaced, with less tightly-packed gauze in the hoof wall defect, until the wound bed had completely cornified. After this point, the bed was simply kept clean and dry, as the hoof wall continued to grow down over the area.

A shoe was applied to the foot to support the horse's weight while alleviating weight-bearing from the wall at the surgical site, reduce motion of the digital structures within the hoof capsule, stabilize the wall in the area of the surgery, and to allow access to the operative site.

2.4. Outcomes Evaluation

The outcomes were assessed through postoperative complications encountered while the horse was hospitalized or as reported by the owner once the horse was discharged from the clinic, and the time until soundness and return to work. Long-term outcome was assessed using a website survey (Annex 1), where owners were asked if 1) the horse had any problem with the foot since the surgery; 2) the horse had developed any infections or abscesses in the operated foot since the surgery; 3) there was any lameness in the operated foot since the surgery; 4) the owner was able to use the horse as intended since recovering from the surgery and if 5) the owner was satisfied with the results of the surgical excision of the keratoma.

3. Results

During the study, 10 horses, diagnosed with keratoma were treated between July 2011 and August 2019 at Running 'S' Equine Veterinary Services. Animal census variables included gender, age, breed, affected limbs and state of origin, and are summarized in Table 1. Two of the 10 cases were referred to the RSEVS.

Table 1. Characterization of the target population (n=10)

		Male	Female
n		9	1
Age (years)	M	18	8
	Min-Max	4-28	8
Breed	Pure	6 (66.7%)	1 (100%)
	TB	4 (44.4%)	-
	Hannoverian	-	1 (100%)
	Danish Warmblood	1 (11.1%)	-
	Arabian	1 (11.1%)	-
	Mixed breed	3 (33.3%)	-
	Shire/TB	1 (11.1%)	-
	Percheron/TB	1 (11.1%)	-
n (%)	Belgium/TB	1 (11.1%)	-
Limb	Front	2 (22.2%)	1 (100%)
	Left	1 (11.1%)	-
	Right	1 (11.1%)	-
	Both	-	1 (100%)
	Hind	7 (77.8%)	-
	Left	6 (66.7%)	-
n (%)	Right	1 (11.1%)	-
Origin (state)	NJ	6 (66.7%)	1 (100%)
n (%)	PA	3 (33.3%)	-

Key: TB, Thoroughbred; NJ, New Jersey; PA, Pennsylvania; M, Median; Min, Minimum; Max, Maximum

The studied population comprised 9 males (90%) and 1 female (10%), with ages ranging from 4 to 28 years (mean 17 years). The horses included in this study were of different breeds, with pure TB (n=4, 40%) the most represented, and with mixed breed TB (n=3, 30%). In 9 of 10 (90%) cases, one leg was affected. One horse (10%) presented 2 affected legs. Regarding the affected legs characterization, 4 involved the front limbs, with 1 in the right foot, 1 in the left foot and 1 horse that had both front limbs affected. Of the 7 affected hind limbs, one horse had a lesion in the right foot and 6 patients had a lesion in the left foot.

At the time of the study, to the best of the owner's knowledge, 2 (20%) horses died of a condition unrelated to the keratoma or the keratoma surgery.

3.1. Clinical Examination Findings

At the time of presentation in the clinic, 1 horse (10%) had a history of recurrent lameness and 2 horses (20%) had a history of chronic lameness, due to chronic abscesses or infection associated to

the keratoma. Initial clinical evaluation revealed a subsolar abscess in 1 patient (10%). Two horses (20%) had a known history of a keratoma in the affected limb. Seven (70%) horses had an elevated digital pulse and 5 horses (50%) were positive to hoof testers. All 10 horses (100%) had visible lesions on initial examination suspicious of a keratoma, like bulging of the hoof wall or a focal deviation of the white line (Table 2). Two horses (20%) presented typical discharge of an anaerobic infection associated to the keratoma. Regional diagnostic anesthesia by perineural blocks was performed in 1 (10%) case.

Table 2. Clinical data, diagnosis and outcomes of the cases of keratoma

Case No.	Case Details	Affected Foot	Clinical Examination Findings	Radiographic Findings	Post-operative complications	Time until surgery site fully keratinized (months)
1	28 YO TB-cross gelding	Left Hind	Large cavity in the hoof wall	Area of lysis over the P3 with gas tracking	Yes	4
2	17 YO TB-cross gelding; 680 Kg	Left Hind	Lameness 1.5/5; mild distortion of the hoof wall	Smooth focal lysis of the P3, consistent with a space-occupying mass	No	1
3	17 YO TB gelding; 500 Kg	Left Front	Lameness 1-2/5; DP↑; Positive HT	Cone-shaped area of lysis of the P3, with sclerotic margins	No	2
4	8 YO Hannoverian filly; 498 Kg	Left and Right Front	Lameness 2/5 LF; DP↑ LF; unfolding of the white line	Discrete osteolysis of the P3 in a crescent shape	No	3
5	16 YO DW gelding; 490 Kg	Left Hind	Deep defect in the white line LH; History of chronic keratoma	Mild enlargement of the crescent-shaped area of lysis of the P3	No	1
6	14 YO TB gelding	Left Hind	History of chronic lameness; chronic defect in the sole at the white line	Large defect with sclerosis, loss of normal trabecular detail	No	2
7	15 YO TB-cross gelding	Right Front	Lameness 3/5; DP↑; Positive HT	Small area of osteolysis of the P3 associated with a chronic tract	No	3
8	21 YO TB gelding; 415 Kg	Left Hind	Lameness 2/5; DP↑	Typical concavity of the P3 consistent with keratoma	No	1
9	4 YO TB gelding; 518 Kg	Left Hind	Lameness 3-4/5; DP↑	Crescent-shaped defect at the heel quarter, increased soft tissue density	Yes	3
10	21 YO Arabian gelding; 460 Kg	Right Hind	Lameness 3/5; DP↑; medial defect in the sole	Conical area of lysis of the P3, consistent with keratoma	No	3

Key: YO, Years Old; TB, Thoroughbred; DW, Danish Warmblood; DP, Digital Pulse; HT, Hoof Tester; LH, Left Hindlimb; P3, Distal Phalanx

3.2. Diagnosis and Treatment

All animals were submitted to diagnostic evaluation plus surgical treatment. All 10 horses (100%) had radiological evidence of either an area of lysis of the solar margin of the P3, considered to be indicative of a keratoma or pedal osteitis with more irregular areas of lysis in the P3 (Figure 2). All 10 horses (100%) were diagnosed with the keratoma described as a conical or horny-shaped keratoma.

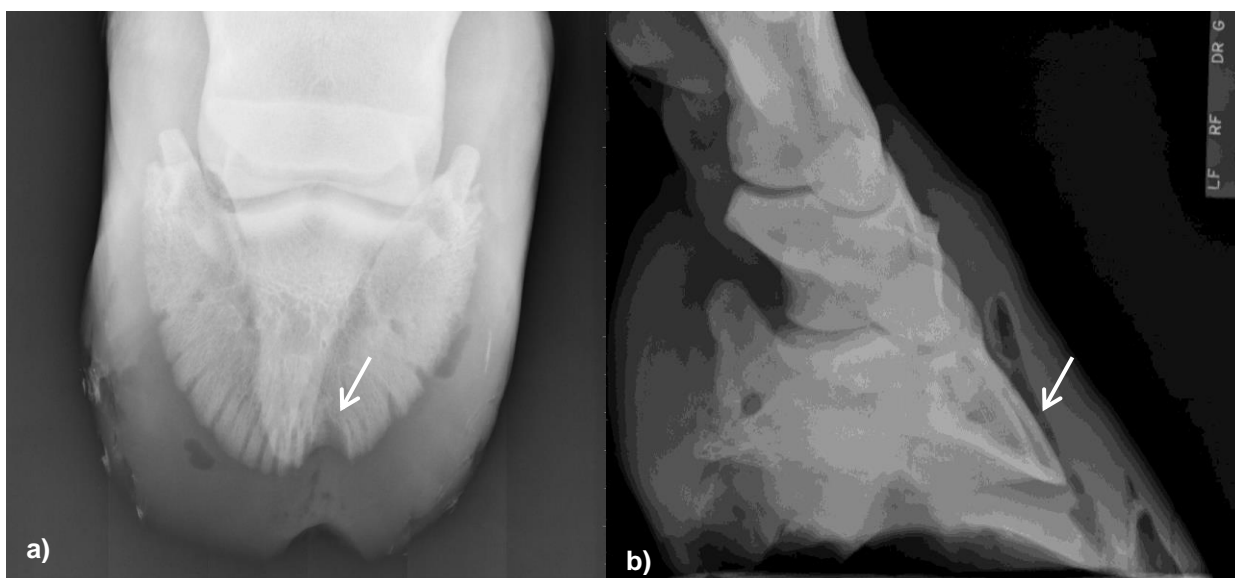


Figure 2. Two examples of the radiographic appearance of keratomas. a) Dorso 65° Proximal-Palmarodistal Oblique (DPPDO) radiograph of the right hindfoot P3 of horse number 10. There is a track in the sole in the immediate location of the defect in the sole, hoof wall and P3. There is also bone loss to track about one-half way proximal on the dorsal medial P3 wal (white arrow). In addition, there is gas shadows at the medial and lateral aspects of the subsolar area. b) Dorsal 45° medial-palmarolateral oblique (DMPLO) radiograph of the left hindfoot of horse number 1. There is a tapering area of lysis over the P3 beneath this hoof wall cavity with gas tracking proximally to the coronary corium (white arrow). (Images kindly provided by Dr. Greg Staller, RSEVS).

All 10 horses (100%) underwent partial hoof wall resection for the complete removal of the keratoma. Six horses (60%) went through the surgical procedure under standing sedation and 4 horses (40%) under general anesthesia (right or left recumbency, depending on the affected limb). Figure 3 indicates the horse number 3 at the clinical examination, which had a history of chronic abscess in the left front foot, and the radiograph of the foot, showing an area of lysis of the P3, suggesting the presence of a keratoma. At the partial resection of the hoof wall, the keratoma was evident, with a conical shape.

Excisional biopsies were obtained from 4 (40%) cases at the time of surgery, for histopathological examination. All samples presented histopathologic features consistent with keratoma, described as both normal tissue (keratinizing epithelium in linear, regular and parallel bands), as well as large, irregular aggregates of keratinized epithelium with multiple enmeshed medusoid *foci* and large islands of epithelial cells.

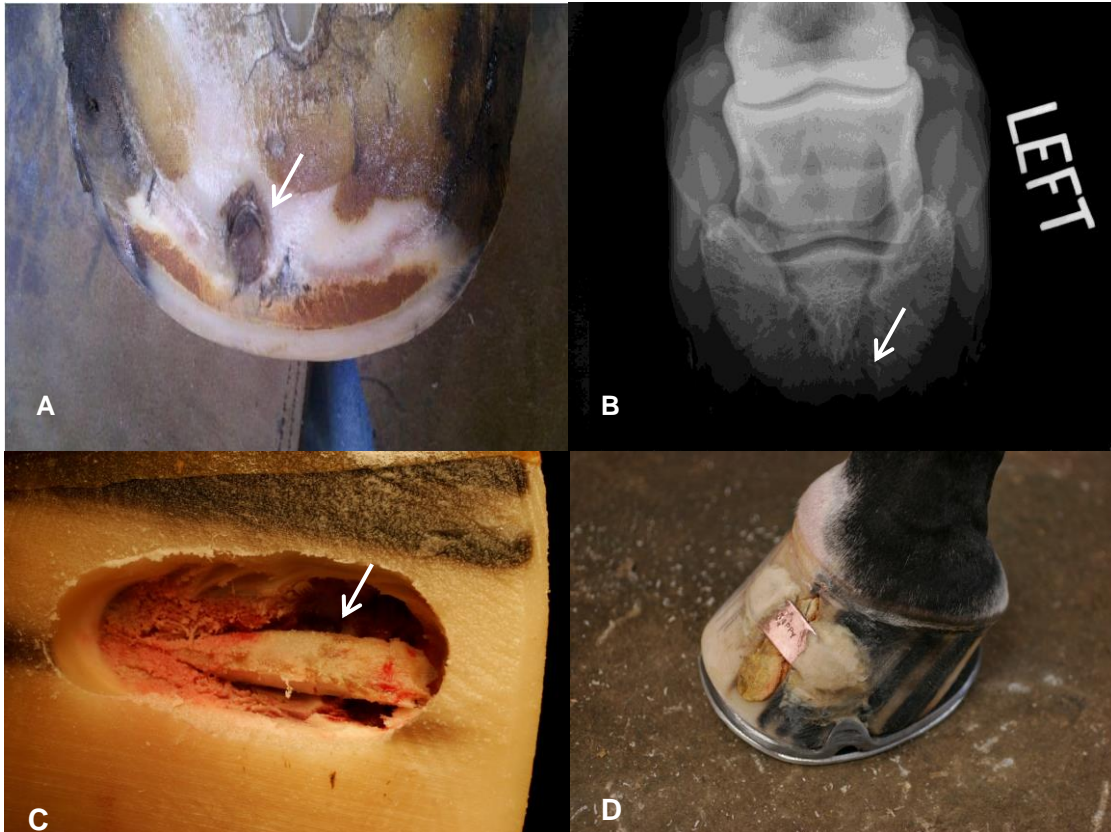


Figure 3. Images of the follow-up of the horse number 3. A – Foot of the horse number 3 at the clinical examination, with history of chronic abscess (white arrow); B – Dorso 45° Proximal-Palmarodistal Oblique (DPPDO) radiograph of the left front foot P3 of the horse number 3. There is a discrete, cone-shaped area of lysis of the P3 (white arrow) extending from the solar margin proximally along the dorsal surface of the P3. There is a discrete soft tissue density overlaying this area of bony lysis; C – Image of the foot of the horse number 3 during the partial resection of the hoof wall for the removal of the keratoma, with evidence of the mass (white arrow); D – Image of the foot of the horse number 3, after the surgical procedure. (Images kindly provided by Dr. Greg Staller, RSEVS)

3.3. Outcome Evaluation Results

In two horses (20%), in which postoperative complications occurred, the conditions were detected within a few days after surgery. Complications included the formation of exuberant granulation tissue on the surgery site and contamination (n=1, 10%) and infection of the surgical site (n=1, 10%). In these two cases, a second surgical debridement was performed. The time until soundness and the time until the surgery site was fully keratinized, 3 horses (30%) took 1 month, 2 horses (20%) took 2 months, 4 horses (40%) took 3 months and 1 horse (10%) needed 4 months.

After the surgery, an internet survey was made available to the horses' owners as described previously, to which 7 of the 10 owners responded (Annex 1). Regarding owners answers, only one owner responded positively to the question 1) "if the horse had any problem with the foot since the surgery"; all owners stated "No" to the question 2) "if the horse had developed any infections or abscesses in the operated foot since the surgery", and only one owner answered "Yes" to the question 3) "if there was any lameness in the operated foot since the surgery"; To the question 4) "if the owner was able to use the horse as intended since recovering from the surgery" 2 owners answered "No". At last, to the question 5) "if the owner was satisfied with the results of the surgical excision of the keratoma", all owners responded "Yes".

4. Discussion

Although no concrete cause is known yet, it has been suggested that keratomas arise from previous trauma or chronic irritation of dorsal sensitive laminae or solar corium through pressure (Rowland *et al.*, 2016; Miller & Katzwinkel, 2015; Redding & O'Grady, 2012), or may be induced by infection or subsolar abscesses, which are usually associated with this mass (Dabareiner, 2007; Katzman *et al.*, 2019). However, cases have also been recorded with no recognized previous history of trauma (Chan & Munroe, 1997; Boys Smith *et al.* 2006). In our study, only 20% of the cases had a history of chronic lameness due to abscesses.

There is no gender or breed predisposition according to some studies (Boys Smith *et al.* 2006; Mair & Linnenkohl, 2012), however, the present study included a higher proportion of geldings (90%) and TB and TB-crosses (70%), suggesting a male as well as a TB predisposition for the appearance of keratoma. However, this may simply represent the sample population. Getman and collaborators (2011) showed similar data in their study, with 80% geldings and 60% TB. Six horses had the left hind foot affected, the remaining horses had only one of the other feet affected each, and 1 horse had both front feet affected. Nevertheless, in other studies (Mair & Linnenkohl, 2012; Getman *et al.*, 2011) the front limbs were the most affected. In comparison with a study of Mair & Linnenkohl (2012) there was a higher number of cases with only one leg affected (95%), with a 90% cases with one affected leg in the present study.

From the 10 equids that underwent keratoma removal only one mare was included, with bilateral front foot keratomas. The keratomas were identified simultaneously in this mare but the keratoma in the left front foot was removed first, followed by removal of the second keratoma in the right front foot about one month later.

Radiological changes suggestive of keratoma (circular radiolucent area of lysis in the P3 with or without marginal sclerosis) were identified in all 10 cases in this study. This radiological sign is thought to be due to pressure from the growing keratoma and have been commonly reported (Chan and Munroe, 1997; Getman *et al.*, 2011). However, three studies have describing the use of CT and MRI for assisting in keratoma diagnosis (Anderson, 2013; Gasiorowski *et al.*, 2011; Getman *et al.*, 2011) concluded that these recent imaging-modalities are useful to better identify and localize the keratomas. In this study, neither CT nor MRI were performed, as they were not considered to be necessary.

The treatment of keratoma includes the complete removal of the keratinized mass and abnormal adjacent tissue from beneath the hoof wall (Honnas, 1998). Limited dorsal hoof wall resection, by various means, has been described to allow surgical access to the lesion (Boys Smith *et al.*, 2006; Getman *et al.* 2011). A retrospective study suggested that partial hoof wall resection rather than complete hoof wall resection is preferable, because it is related with fewer complications and a faster return to soundness (Boys Smith *et al.* 2006). By using this technique to remove the keratomas, in the present study, we had only 20% postoperative complications. In no cases was there recurrence of the keratoma, and a mean time to return to work (soundness), with the surgery site fully keratinized,

of 2.3 months. Also, in this study, the mean time until the hoof wall resection site has had completely grown out was 6.4 months. In comparison, a previous study (Getman *et al.*, 2011) showed that horses became sound in 2.7 months (mean time) after surgery, and according to other study (Boys Smith *et al.*, 2006), after the removal of the keratoma, the hoof wall can take 6 to 8 months to regrow completely.

The reason for the low postoperative complication rates and a quicker return to work seen in these horses is likely to be multifactorial. Previous reports had found that postoperative complications are decreased when partial hoof wall resection is used, ensuring that all of the abnormal tissue is removed and allowing for hoof wall stability to be maintained (Boys Smith *et al.*, 2006). However, a disadvantage of performing a partial hoof wall resection using only radiographic guidance is the potential for keratoma recurrence, if all of the abnormal tissue is not removed at the time of surgery (Getman *et al.*, 2011).

The histological examination was performed in 4 cases, which confirmed the presence of the keratoma.

The horses that had complication after surgery had few characteristics in common. They were both geldings and TB pure or crossbred and in both cases the left hind foot was affected. One horse was 28 years old and took 4 months to return to soundness, and the other horse was 4 years old and took 3 months to return to work sound.

In the owners' answers from the survey, only 1 of the 7 horses whose owners responded had presented lameness in the operated foot since the surgery and none of those 7 horses had presented infections or abscesses in the operated foot since the surgery. Only 2 of the 7 owners hadn't been able to use the horse as intended since recovering from the surgery, which result in total satisfaction of all 7 owners with the outcomes of the surgical removal of the keratoma.

One of the greatest limitations of this study is the number of cases (n), which was too low to allow statistically significant conclusions. In spite of the low sample size, the dataset is valuable to study this condition, allowing comparison with past and future reports (retrospective and prospective). In addition, bibliographic data on this issue are scarce, and few studies about keratoma in horses include larger samples (Annex 2). Only a recent retrospective case series involved 32 animals (Katzman *et al.*, 2019). The Annex 2 refers to the study cases about keratoma and in 16 of them, 5 had between 10 and 32 animals involved, one had 2 animals involved and 10 had 1 animal involved. On balance, the number of animals in this case series on keratomas is relatively low, but the uncommon occurrence of the condition makes the assembly of large numbers of cases challenging. However, this group of 11 keratomas in 10 horses in this single location over a nine year period is a relatively large number.

5. Conclusions

Preoperative examination and radiographic imaging of the feet were useful in the diagnosis and surgical planning of keratomas in horses. Thoroughbred was the most affected breed, and the left hind foot was the most affected. The removal of the keratoma was performed through partial hoof wall resection with a low rate of post-surgical complications (20%) and 0% rate of recurrence.

Considering the few studies involving keratoma in horses, more studies with a larger number of cases may allow more powerful conclusions to be drawn regarding diagnosis and treatment. Prospective studies designed to elucidate the etiology of the keratoma, and allow identification at an early stage than is possible presently, would be valuable.

6. References

1. American Association of Equine Practitioners. (2020). *Lameness Exams: Evaluating the Lamé Horse*. <https://aaep.org/horsehealth/lameness-exams-evaluating-lame-horse>
2. Anderson, J. D. C. (2013). Characterization of keratomas of the equine digit using contrast enhanced computed tomography (CECT) to facilitate surgical removal and provide prognostic information regarding post operative morbidity. *Equine Veterinary Journal*, 45, 11-11.
3. Back, W., van Schie, M. J. J. & Bosch, G. (2007). Clinical Commentary: Keratoma and its cutting edges. *Equine Veterinary Education*. 19(6), 288-289.
4. Baxter, G. M. & Stashak, T. S. (2011). Keratoma. In G. M. Baxter, *Adams and Stashak's Lameness in Horses*, 6th Ed. (pp. 991-996). West Sussex: John Wiley and Sons.
5. Boys Smith, S. J., Clegg, P. D., Hughes, I., & Singer, E. R. (2006). Complete and partial hoof wall resection for keratoma removal: post operative complications and final outcome in 26 horses (1994–2004). *Equine Veterinary Journal*, 38(2), 127-133.
6. Chan, C. C-H. & Munroe, G. A. (1997). Treatment of a keratoma in a Clydesdale horse. *The Veterinary Record*. 140(17), 453-456.
7. Christman, C. (2008). Multiple keratomas in an equine foot. *Canadian Veterinary Journal*. 49(9), 904–906.
8. Cullimore, A & Booth, T (2010). Clinical aspects of the equine foot Part 5: Equine keratoma. *UK Vet Companion Animal*. 1 (2), 11-15.
9. Dabareiner, R. M. (2007). Keratoma: a similar cause of lameness. *Compendium Equine Edition*, 2(3), 140-42.
10. Davies, H. S. & Philip, C. (2007). Gross Anatomy of the Equine Digit. In A. E. Floyd & R. A. Mansmann, *Equine Podiatry*, First Edition (pp. 1-24). Elsevier.
11. Diaz, G. M., Guerri, C. R. & Maldonado, B. S. (2008). Case report of a keratoma in the hoof wall of a horse. *Revista Complutense de Ciencias Veterinarias*. 2(2), 115-119.
12. Eastman, T. G. (2015). Keratomas. In Robinson's Current Therapy in *Equine Medicine*, 850–851.

13. Gasiorowski, J.C., Getman L. M. & Richardson, D.W. (2011). Supracoronary approach for keratoma removal in horses: Two cases. *Equine Veterinary Education*. 23(10), 489–493.
14. Getman, L. M., Davidson, E. J., Ross, M. W., Leitch, M., & Richardson, D. W. (2011). Computed tomography or magnetic resonance imaging-assisted partial hoof wall resection for keratoma removal. *Veterinary Surgery*, 40(6), 708-714.
15. Greet, T (2016). The management of multiple keratoma lesions in an equine foot. *Equine Veterinary Education*. 28(6), 315-318.
16. Hall, S (2015). Case study: Keratoma – A cause of recurrent lameness. *Equine Health*. 2015(21), 32-34.
17. Hamir, A.N., Kunz, C. & Evans, L.H. (1992). Equine keratoma. *Journal of Veterinary Diagnostic Investigation*. 4(1), 99–100.
18. Honnas, C. M., Dabareiner, R. M., & McCauley, B. H. (2003). Hoof wall surgery in the horse: approaches to and underlying disorders. *Veterinary Clinics: Equine Practice*, 19(2), 479-499.
19. Honnas, C. M. (2011). Clinical Commentary: Supracoronary approach for keratoma removal. *Equine Veterinary Education*. 23(10), 494-495.
20. Honnas, C. M. (1998). Keratomas of the equine digit. *Equine Veterinary Education*. 4, 68-72.
21. Honnas, C. M. (1991). Standing surgical procedures of the foot. In A. L. Bertone (Eds) *Veterinary Clinics of North America: Equine Practice* (Vol. 7(3), pp. 695-722). Philadelphia: W. B. Saunders Company.
22. Katzman, S. A., Spriet, M. & Galuppo, L. D. (2019). Outcome following computed tomographic imaging and subsequent surgical removal of keratomas in equids: 32 cases (2005–2016). *Journal of the American Veterinary Medical Association*. 254(2), 266-274.
23. Mair, T. S. & Linnenkohl, W. (2012). Low-field magnetic resonance imaging of keratomas of the hoof wall. *Equine Veterinary Education*. 24(9), 459-468.
24. McDiarmid, A. (2007). Keratoma from the frog corium of a horse. *Equine Veterinary Education*. 19(6), 285-287.

25. Miller, S.M. & Katzwinkel, R.H. (2015). Solar keratoma: An atypical case. *Journal of the South African Veterinary Association*. 86(1), 1-4. doi:10.4102/jsava.v86i1.1257.
26. O'Grady, S. E. (2008). Basic farriery for the performance horse. In A. M. Cruz (Eds) *Veterinary Clinics of North America: Equine Practice* (Vol. 24(1), pp. 203-218). Philadelphia: Elsevier.
27. O'Grady, S. E. & Horne, P. A. (2001). Lameness caused by a solar keratoma: a challenging differential diagnosis. *Equine Veterinary Education*. 13(2), 87-89.
28. Redding, W. R., & O'Grady, S. E. (2012). Nonseptic Diseases Associated with the Hoof Complex. *Veterinary Clinics of North America: Equine Practice*, 28(2), 407–409.
29. Redding, W. R. (2007). Pathologic Conditions Involving the Internal Structures of the Foot. In A. E. Floyd & R. A. Mansmann, *Equine Podiatry*, First Edition (pp. 253-293). Elsevier.
30. Reeves, M. J., Yovich, J. V. & Turner, A. S. (1989). Miscellaneous Conditions of the Equine Foot. In J. V. Yovich, *Veterinary Clinics of North America: Equine Practice* (Vol. 5(1), pp. 221-242). Philadelphia: W. B. Saunders Company.
31. Rowland, A. L., Goodrich, L. R., Bass, L. D., Aldrich, E. D., Edmondson, E. F., & Mueller, L. W. (2016). Diagnosis and treatment of biaxial keratomas in the left fore foot of a 15-year-old Clydesdale mare. *Equine Veterinary Education*, 28(6), 310-314.
32. Stashak, T. S. (1987). Keratoma. In T. S. Stashak, *Adams' lameness in horses* (p. 541). Philadelphia: Lea and Febiger.
33. Tatarniuk, D. M., Bracamonte, J. L., Wilson, D. G., Sharma, A., & Perry, A. W. (2013). Laminar epidermal hyperplasia and hyperkeratosis in an equine hoof. *The Canadian Veterinary Journal*, 54(9), 849-852.
34. Turner, T (2016). Equine keratoma. *Equine Veterinary Education*. 28(6), 319-320.
35. Valentine, B. A., Scott, E. A., Watrous, B. J. & Stonecipher, C. R. (2000). What Is Your Diagnosis?. *Journal of the American Veterinary Medical Association*, 217(7), 993-994.

Annex 1

Table 1. Answers of the horses' owners to the website survey

Case No.	1. Have/Had there been any problems with the foot since the surgery?	2. Has/Had the horse develop any infections or abscesses in the operated foot since the surgery?	3. Has/Had there been any lameness in the operated foot since the surgery?	4. Have/Had the owner been able to use the horse as intended since recovering from the surgery?	5. Is/Were the owner happy/satisfied with the results of the surgical excision of the keratoma?
1	No	No	No	Yes	Yes
4	Yes	No	Yes	Yes	Yes
5	No	No	No	Yes	Yes
6	No	No	No	No	Yes
7	No	No	No	Yes	Yes
8	No	No	No	No	Yes
10	No	No	No	Yes	Yes

Table 2. Case reports, retrospective studies and case series about keratoma

Year	Authors	<i>n</i>	Ratio M/F (%)	Age (~YO)	Breed	Objective of the study	Histological confirmation
1992	Hamir, Kunz & Evans	1	M	15	QH	To describe a keratoma in the coronary band	Yes
1997	Chan & Munroe	1	M	6	Clydesdale	To describe a keratoma with severe and concurrent digital infection	Yes
2000	Valentine, Scott, Watrous & Stonecipher	1	M	6	Appaloosa	To describe the diagnosis of a keratoma	Yes
2001	O'Grady & Horne	1	M	12	TB	To describe a keratoma found in the dermis of the sole	Yes
2006	Boys Smith, Clegg, Hughes & Singer	26	65 / 35	10.3	TB, TB-cross	To identify important factors in the outcome and compare the post operative complications	Yes
2007	McDiarmid, A	1	M	12	WB	To describe a keratoma of the frog corium in a horse	Yes
2008	Christman, C.	1	M	19	Arabian	To describe a multiple keratoma (3) in the left hind foot	No
2008	Diaz, Guerri & Maldonado	1	M	16	/	To describe a keratoma in a horse with chronic lameness	Yes
2011	Gasiorowski, Getman & Richardson	2	M	15	TB and Hannoverian	Supracoronary approach for a keratoma removal	Yes
2011	Getman, Davidson, Ross	10	80 / 20	11.7	TB, Arabian, QH, Paint	To describe CT and MRI appearance of keratomas and evaluate the morbidity	Yes
2012	Mair & Linnenkohl	21	48 / 52	12	WB, TB, Shire-cross	To describe the use of MRI in horses with keratoma	Yes
2013	Anderson, J.D.C.	10	/	9.3	/	To characterise keratomas using CECT and provide information regarding post operative morbidity	Yes
2015	Hall, S.	1	F	9	/	To describe a keratoma in a horse with chronic lameness	Yes
2015	Miller & Katzwinkel	1	M	4	TB	To describe a solar keratoma	Yes
2016	Rowland <i>et al.</i>	1	F	15	Clydesdale	To describe the diagnosis and treatment of biaxial keratomas	Yes
2019	Katzman, Spriet & Galuppo	32	75 / 25	13.9	TB, WB, Arabian, QH, Friesian, Paint	To describe the use of CT and determine postoperative complications and outcome	Yes

Key: CECT, Contrast Enhanced Computed Tomography; CT, Computed Tomography; *n*, Number of animals; M/F, Male/Female; MRI, Magnetic Resonance Imaging; TB, Thoroughbred; QH, Quarter Horse; WB, Warmblood; YO, Years Old