

The technical challenge of Functional ^{18}F -FDG-PET Brain imaging in paediatric epilepsy

A. M. Mota¹ (ana.v.mota@jmellosoaude.pt), A. Geão¹, A. Santos¹, L. Dias¹, P. Quaresma¹, P. Colarinha¹

¹ Nuclear Medicine Department, Cuf Descobertas Hospital

Epilepsy is a chronic brain disease, characterized by the appearance of seizures, caused by abnormal electric activity on brain cells. Neuroimaging might be necessary in the work-up of epilepsy for identification of seizure focus for possible surgical intervention.

In our department, we started performing interictal ^{18}F -2-deoxyglucose (FDG)-PET/TC Brain imaging for paediatric patients (pt) in 2009, following EANM procedure guidelines.

Aim: the aim of our study was to retrospectively review all performed interictal ^{18}F -FDG-PET/TC brain imaging, to assess the difficulties found during these procedures and the deviation according to the guideline recommendations. We also intend to focus on the major importance of an optimal cooperation with other departments, such as anaesthesiology and neurophysiology.

Material and Methods: between 2009 and 2012, 10 patients (pt) were referred for a ^{18}F -FDG-PET/TC brain study, with ages between 10 months and 18 years old. All pt had medically intractable epilepsy. Exceptional procedures call for special conditions. Thus, examinations were performed with different conditions according to pt particular necessities.

All pt followed the required preparation: fasting for at least 4 hours; blood glucose levels below 160mg/dL; pt were comfortably positioned in a quiet room from several minutes before FDG injection and at least 20 minutes after injection.

If sedation is required it should be performed as late as possible, after FDG injection. When Electroencephalogram (EEG) is used, it should start at least 2h before FDG injection and until 20 min after.

TABLE 1 - Exam conditions

PATIENTS	AGE	WEIGHT (Kg)	ACTIVITY (MBq)	ACTIVITY VARIATION (%)	CT (mAs/kV)	BLOOD GLUCOSE LEVELS (mg/dL)	SEDATION	EEG	TIME INJECTION / AQUISITION
1	6 years	20	63	- 6	30 mAs 90 kV	82	✓	✗	64'
2	13 years	53	144	- 8	20 mAs 90 kV	103	✗	✗	40'
3	18 years	32	93	- 9	30 mAs 90 kV	81	✓	✗	65'
4	11 years	39	118	- 3	20 mAs 90 kV	91	✗	✗	44'
5	10 months	11	40	- 2	20 mAs 90 kV	66	✓	✗	57'
6	7 years	29	111	+ 19	20 mAs 90 kV	107	✓	✗	41'
7	4 years	15	48	- 9	20 mAs 90 kV	98	✓	✗	33'
8	9 years	41	150	+19	20 mAs 90 kV	87	✓	✗	54'
9	2 years	14	47	- 6	20 mAs 90 kV	46	✓	✗	47'
10	3 years	16	49	- 10	20 mAs 90 kV	62	✓	✓	88'
Guidelines*	-	-	Baseline Activity(14 MBq) X Multiple (EANM dosage card v.1.5.2008)		10-30 mAs 140 kV	<160	If needed	✓	30'- 60'

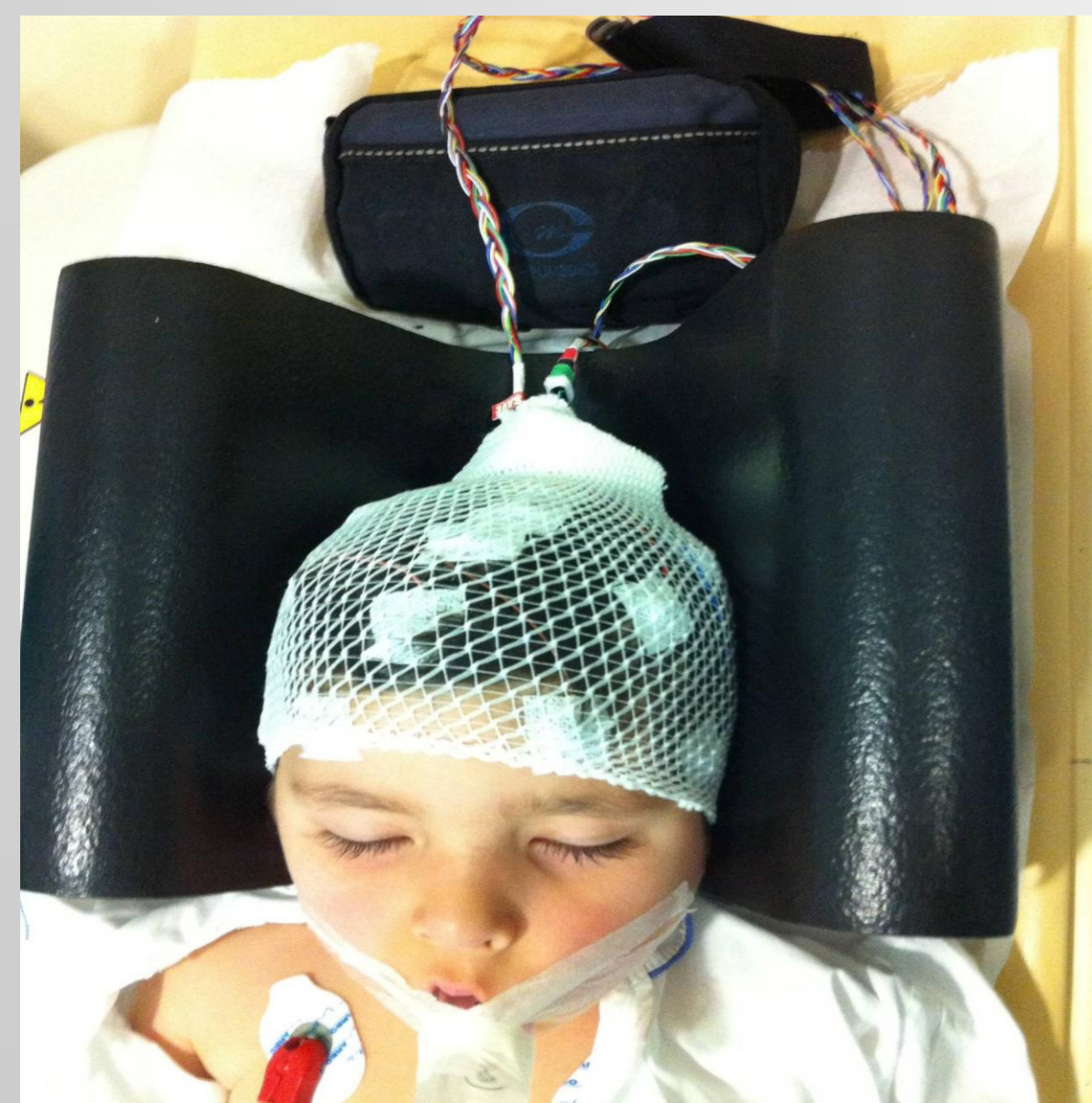
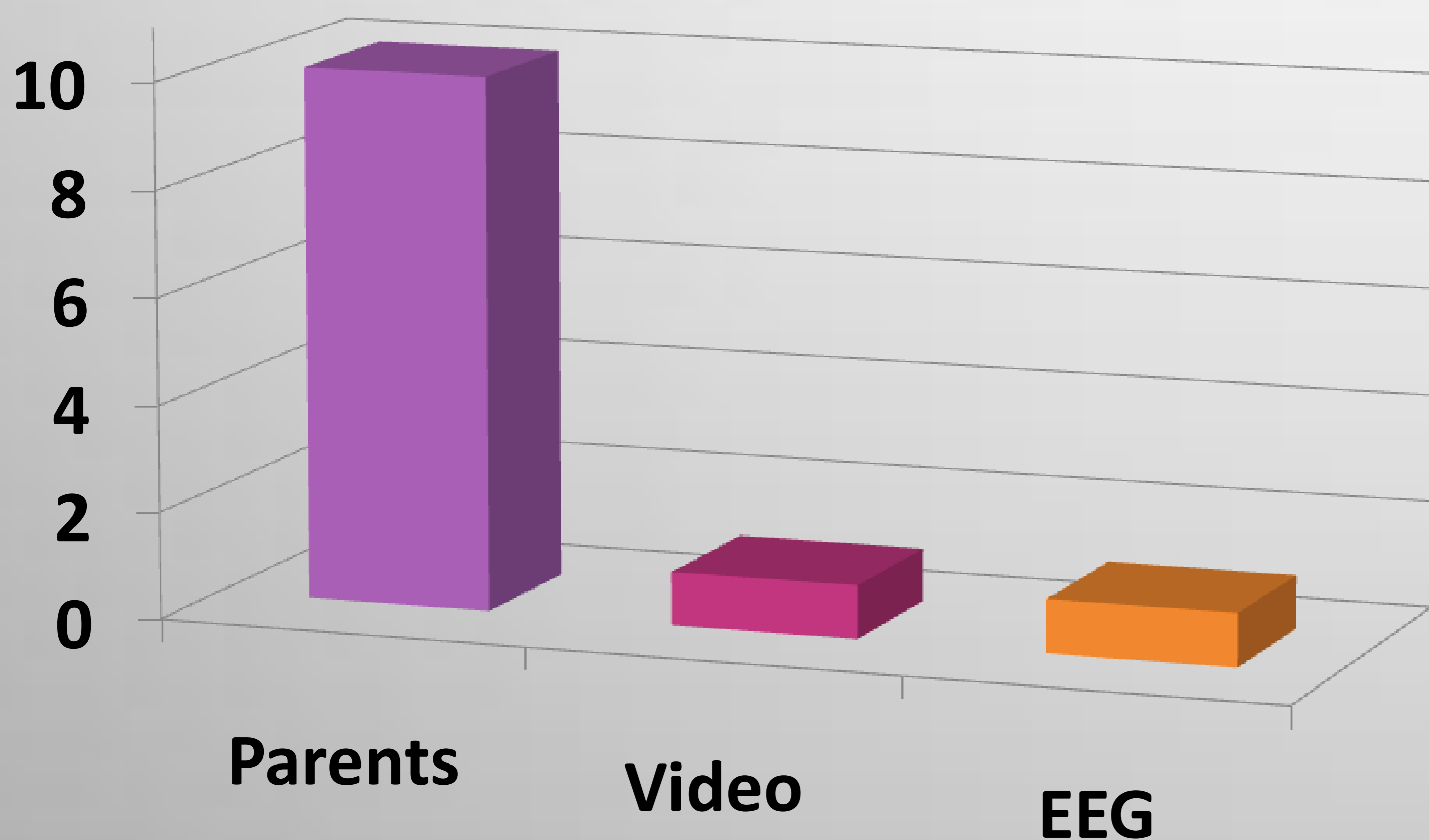


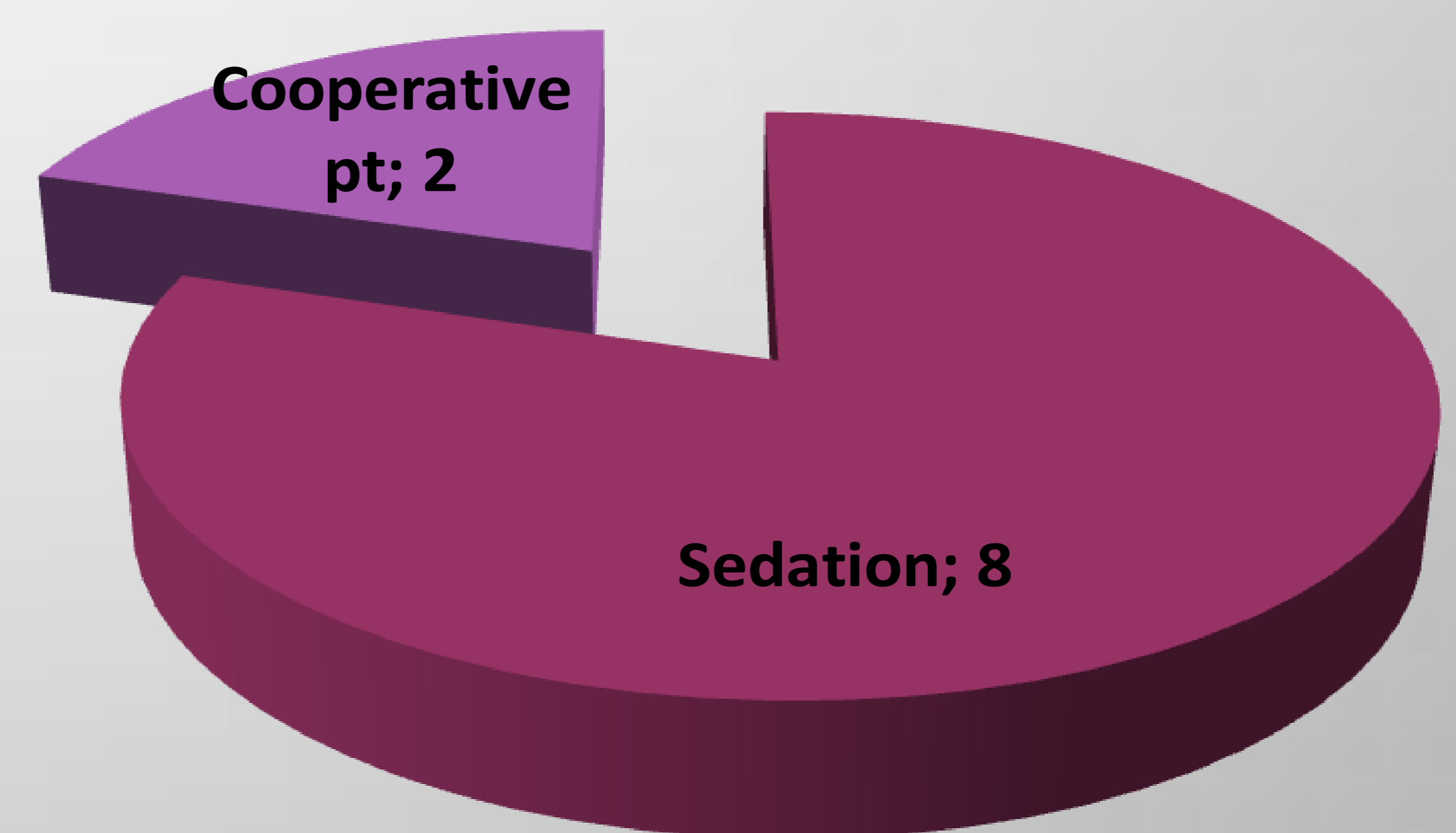
Image 1 - Positioning of the patient

Results: All files were reviewed concerning pt information on procedure performance: pt preparation both pre-arrival and pre-injection, pt monitoring for seizures before injection (with EEG), pt sedation, differences on injected activity and data acquisition parameters. For 8 pt (80%) we needed anaesthesiology intervention and at 2 cooperative pt (20%) there were no need for sedation. All pt were monitored under parental surveillance, 1 pt with additional video recording and 1 pt with EEG.

Pre-injection Monitoring



Anaesthesia



Conclusion: With this review, we were able to enhanced our learning curve at this very specific procedure.

Patients performed a low-dose CT scan, for attenuation correction; thus, the absorbed dose was reduced by lowering tube current and voltage.

Although EEG monitoring is the most acute method to monitoring seizures, we prefer parental surveillance rather than video recording, since parents are familiarized with their children seizures.

One of our main conclusions is that we need to improve our acquisition protocol, with particular regards to the start time acquisition, in order to make different patients or repeated scans data comparable.

We also found it critical to request cooperation between departments, namely anaesthesiology and neurophysiology.

*Varrone A., Asenbaum S., Borghat T., Boojij J., Nobili F., Nagren K., et al. EANM procedure guidelines for PET brain imaging using [^{18}F]FDG, version 2. Eur J Nucl Med Mol Imaging 2009