



VASCO DA GAMA UNIVERSITY SCHOOL

VETERINARY MEDICINE MASTER'S DEGREE

A GUIDE FOR FERRET LYMPHOMA

Daniela Sofia Neves Soares

Coimbra, April 2015



VASCO DA GAMA UNIVERSITY SCHOOL

VETERINARY MEDICINE MASTER'S DEGREE

A GUIDE FOR FERRET LYMPHOMA

Coimbra, April 2015

Author

Daniela Sofia Neves Soares

Supervisors

Prof. Dr.^a Anália do Carmo

Dr.^a Ana Luísa Vieira

Abstract

Ferrets popularity as pets is increasing in North America and Europe and appear more frequently in veterinary practice. Therefore, it is important to study this specie in order to provide advanced medical care.

After insulinoma and adrenocortical neoplasia, lymphoma is the third more common neoplasia in domestic ferrets, and this condition appears to be increasing in frequency. Lymphoma can be described as a proliferation of neoplastic lymphoid cells, and can occur in ferrets of all ages and in practically all organ systems. Despite various theories, the exact etiology of lymphoma remains unknown.

Although the increased incidence of lymphoma, there are still difficulties in obtaining an accurate diagnose of this neoplasia, lack of uniformity in its classification, and protocols to ensure an appropriate treatment.

This article aims to present guide that gathers the information published about lymphoma in ferrets, and to provide an orientation on the diagnosis and treatment of ferrets with this neoplasia.

Keywords: Chemotherapy; Ferret; Lymphoma; Oncology; Radiation therapy.

Resumo

Os furões são cada vez mais populares como animais de companhia na América do Norte e Europa, surgindo mais frequentemente na prática veterinária. Portanto, é cada vez mais importante conhecer esta espécie e estar apto a prestar cuidados médicos avançados.

Depois do insulínoma e da neoplasia adrenocortical, o linfoma é a terceira neoplasia mais comum nos furões domésticos, estando a sua frequência a aumentar. O linfoma pode ser descrito como uma proliferação de células linfóides neoplásicas, e pode ocorrer em todas as faixas etárias e em praticamente todos os sistemas de órgãos. Apesar das várias teorias, a verdadeira etiologia do linfoma permanece desconhecida.

Apesar da elevada incidência do linfoma, há ainda dificuldades em obter um diagnóstico preciso desta neoplasia, falta de uniformidade na sua classificação, e de protocolos que assegurem um tratamento apropriado.

Este artigo tem como objectivo apresentar um guia que reúna a informação publicada acerca de linfoma em furões, e fornecer uma orientação no diagnóstico e tratamento de furões com esta neoplasia.

Palavras-chave: Furão; Linfoma; Oncologia, Quimioterapia, Radioterapia.

Index

1. Introduction	1
2. Lymphoma in ferrets	1
a. Etiology	1
b. Classification	2
3. Diagnosis	5
a. Clinical signs	5
b. Differential diagnosis	9
c. Complementary exams	10
i. Hematology and serum biochemistry	10
ii. Imagiology	11
iii. Cytology/biopsy/immunohistochemistry	12
4. Treatment	13
a. Surgical	13
b. Chemotherapy	13
c. Radiation therapy	18
d. Ancillary treatment	18
5. Prognosis	20
6. Future directions	20
7. Conclusions	21
8. Acknowledges	22
9. References	23

Figures index

Figure 1. Clinical signs of mediastinal lymphoma

Figure 2. Clinical signs of multicentric lymphoma

Figure 3. Clinical signs of gastrointestinal lymphoma

Figure 4. Clinical signs of nonepitheliotropic and epitheliotropic cutaneous lymphoma

Figure 5. Clinical signs of leukemia

Figure 6. Clinical signs of extranodal lymphomas

Figure 7. L-COP protocol for ferret lymphoma

Figure 8. L-VCAMP protocol for ferret lymphoma

Figure 9. Noninvasive protocol for ferret lymphoma

Tables index

Table 1. Staging system of ferret lymphoma

Table 2. Grading system of ferret lymphoma

List of abbreviations

ADV	Aleutian disease parvovirus
FeLV	Feline leukemia virus
MALT	Mucosa-associated lymphoid tissue
RBC	Red blood cell
CD	Cluster of differentiation
PCR	Polymerase chain reaction
COP	Cyclophosphamide, Vincristine, Prednisone
CHOP	Cyclophosphamide, Doxorubicin, Vincristine, Prednisone
L-COP	L-Asparaginase, Cyclophosphamide, Vincristine, Prednisone
L-VCAMP	L-asparaginase, Vincristine, Cyclophosphamide, Doxorubicin, Methotrexate, Prednisone

1. Introduction

The domestic ferret (*Mustela putorius furo*) belongs to the family *Mustelidae* of the order *Carnivora*¹ and is considered an obligate carnivore² with a life expectancy of 5 to 8 years.³⁷ The most probable ancestor of ferrets is the European polecat (*Mustela putorius*). However, ferrets may also be related to the steppe polecat (*Mustela eversmannii*). They are thought to have been domesticated 2000 years ago but there are references to the domestic use of ferrets since 63 BC.³ Nevertheless, most of the changes resulting from the domestication have been behavioral, with few or no biological changes.⁴ The ferrets were used to hunt rodents and rabbits (ferreting), to transport cables through long lengths of conduit, to entertain (ferret-legging), as animal models in biomedical research and, more recently, ferrets were also considered pets.³ The popularity of ferrets as pets is increasing, especially in North America and Europe,⁵ which turns their presence in veterinary clinics more frequent,⁶ and requires a knowledge of diseases associated with these animals to provide advanced medical care.

2. Lymphoma in ferrets

Ferrets are susceptible to a variety of diseases throughout their lives, being the development of neoplasia one of the main common conditions. After insulinoma and adrenocortical neoplasia, the lymphoma is the most common neoplasia in domestic ferrets,⁷⁻¹⁰ and it is their most frequent hematopoietic neoplasia.^{7,10} This condition appears to be increasing in frequency, probably due to the growing popularity of ferrets as pets, to their increased longevity, to the improved diagnostic testing, and to the increased disease reporting.^{11,12} The fact is that lymphoma represents 10% to 15% of all neoplastic presentations in ferrets from the United States and Europe,¹² and it can occur in ferrets of all ages and in practically all organ systems.¹³ Lymphoma can infiltrate several organs, such as lymph nodes, thymus, lungs, spleen, liver, intestines, kidneys, and bone marrow. Other less common locations may include stomach, pancreas, nervous system, orbit and skin.^{7,14,15}

a) Etiology

Lymphoma can be described as a malignant proliferation of neoplastic lymphoid cells.^{7,14} The proliferation of these malignant cells originates palpable masses and disrupt the normal architecture of the tissue.¹⁴ Despite various theories, the exact etiology of lymphoma remains unknown.^{7,12} Clusters outbreaks of lymphoma in young and adult ferrets reported in colonies and private homes suggest an infectious etiology, as well as genetic predisposition and environmental factors like carcinogen exposure, such as herbicides and pesticides.^{7,13,14} In fact, a previous study reported that some virus, such as the aleutian disease parvovirus (ADV), the feline leukemia virus (FeLV) and a ferret retrovirus, may contribute to the development of lymphoma.¹⁴ Although these results support the association

between virus infection (ADV, FeLV) and lymphoproliferative disease in ferrets, there are also recent studies reporting that ferret's lymphoma may occur without these two virus infection.^{7,14,16} Regarding the retroviral cause, there is a study demonstrating an horizontal transmission of lymphoma by inoculating recipient ferrets with cells from a ferret with lymphoma. The presence of reverse transcriptase activity and retrovirus-like particles in cultivated cells from the inoculated ferrets suggested a retroviral cause,¹⁷ but no specific virus has been identified.¹³

Other studies identified an association between gastric lymphoma and gastrointestinal infection by *Helicobacter mustelae*,⁷ and cases of *H. mustelae*-associated gastric adenocarcinoma.¹⁸ In fact, Hess *et al*⁷ showed that chronic infection due to *H. mustelae* bacterium resulted in extensive lymphoproliferative responses in the gastric mucosa. Additionally, Fox *et al.*,¹⁹ reported that primary gastric lymphomas may develop in ferrets naturally infected by *H. mustelae*. The study of gastric mucosa-associated lymphoid tissue (MALT) suggested that this Gram-negative bacterium may play an important role in the development of lymphoma.¹⁸ The genome of *H. mustelae* was sequenced in order to detect genetic alterations that might explain the association between the ulcerogenic and the carcinogenic activity induced by this bacterium,²⁰ but specific genes associated to gastric lymphoma have not yet been identified.¹⁴

b) Classification

Previously, the ferret lymphoma was simply classified according to age at onset, cell type, and organ system affected.⁷ Therefore, lymphoma was commonly divided into lymphoblastic type or juvenile, lymphocytic type or adult/chronic^{7,21} and into an immunoblastic polymorphous type. The lymphoblastic type seems to affect predominantly young ferrets (under 2 years of age), with acute onset of clinical signs, and is characterized by the presence of large, immature and atypical lymphoblasts. The lymphocytic type is seen in ferrets older than 3 years of age, and has a chronic development, being characterized by the presence of mature and well differentiated neoplastic lymphocytes. The immunoblastic polymorphous type is more unusual, can occur in all ages, and is characterized by the presence of large atypical lymphocytes, lymphoblasts, immunoblasts, and small lymphocytes.^{7,14}

As in others pathologies, it is essential to establish a standardized classification of ferret lymphoma that allows the systematization of all the information about lymphoma cases. This classification should take into account the macroscopic and microscopic properties, the cellular and the molecular alterations that characterize these tumours,^{12,14} and should have prognostic value.¹⁶ A recent proposal for ferret lymphoma classification enables an effective categorization of ferret lymphoma, and allows the creation of a database of tumour classification and respective response to treatment.^{12,14} The main points of this classification include staging, grading and immunophenotyping, which were considered the main points to achieve the description of the lymphoma.^{12,14,16}

The staging process aims a clinical description of the disease, and must contain information about anatomical site, number of lesions, location of the lesions relative to the diaphragm, information about

nodal *versus* extranodal lesions, and involvement of the blood or bone marrow.^{14,16} Thereby, this recent lymphoma classification proposed the following staging system (table 1),¹² wherein the stage is obtained by conjugating a letter (anatomic site) with a stage number (location of lesions relative to the diaphragm, nodal *versus* extranodal lesions, and involvement of the blood or bone marrow). In addition to these, it is also possible to consider the existence or absence of clinical signs.

Table 1. Staging system of ferret lymphoma

Anatomic site	A	Generalized/multicentric
	B	Alimentary/gastrointestinal
	C	Thymic/mediastinal
	D	Cutaneous
	E	Leukemia (true)
	F	Others/extranodal (e.g. solitary renal, splenic, periorbital or neural tumours)
Stage	1	Single anatomic lesion (nodal or extra-nodal)
	2	Single lesion with regional lymph node involvement limited to one side of the diaphragm
	3	Lesions on both sides of the diaphragm including intra-abdominal or gastrointestinal locations
	4	Multiple sites on both sides of the diaphragm are affected with or without the visceral organs
	5	Manifestation in the blood and involvement of bone marrow and/or other organ systems
Clinical signs	a)	Without clinical signs
	b)	With systemic signs

Adapted from Mayer J, Burgess K: An update on ferret lymphoma: a proposal for a standardized classification on ferret lymphoma. *Journal of Exotic Pet Medicine* 21:343-346, 2012

The grading procedure (table 2) involves an histologic evaluation,^{11,12} i.e. a description of tissue architecture, cell morphology (amount of cytoplasm, nuclear size and morphology, nucleoli, presence of necrosis, fibrosis, or inflammation), and mitotic indices that allow to classify the lymphoma in low, intermediate or high grade.^{11,16} Lymphocytes with nuclei under 1.5 x red blood cell (RBC) diameters are categorized as “small”, 1.5 to 2.0 x RBC diameters as “medium”, and over 2.0 x RBC diameters as “large”. The description of cell morphology should lead to a classification of the type of cells that predominate, as well as if the population is monomorphic or polymorphic. According to mitotic index, a lymphoma with an average of less than 5 mitotic figures in 10 fields at 40 x magnifications is

considered “low grade”, between 6 and 19 mitotic figures lymphoma is considered “intermediate grade”, and above 20 mitotic figures is considered “high grade”.¹¹ According to this system, it seems that young ferrets are more likely to have high-grade lymphoma, while older ferrets can present either high- or low-grade lymphoma.¹⁴

Table 2. Grading system of ferret lymphoma

Cell morphology	Size	Small < 1,5 x RBC diameters
		Medium 1,5 – 2,0 x RBC diameters
		Large > 2,0 x RBC diameters
	Type of cells	Lymphocytic
		Lymphoblastic
		Immunoblastic
	Population	Monomorphic
		Polymorphic
	Mitotic index	Low grade
Intermediate grade		6 – 19 mitotic figures
High grade		> 20 mitotic figures

Lastly, the immunophenotyping, which defines the tumour as B-cell or T-cell lymphoma, can be achieved through the analysis of the expression of CD3 (Cluster of Differentiation) and of CD79 α by immunohistochemistry or flow cytometry.^{8,11,12,14,16,22,23} CD3 is considered a T-cell marker, and CD79 α is a B-cell marker.^{11,13,14,23} There is a study that reported a larger mean survival time in ferrets with B-cell lymphoma than in ferrets with T-cell lymphoma. Despite being a small study, this can be the beginning of a database that correlates the phenotype of the lymphoma with prognosis.¹⁵

This classification is very simple when compared with the World Health Organization classification that divides human lymphoma in non-Hodgkin lymphoma (B-cell and T-cell lymphoma) and Hodgkin lymphoma, each one with subdivisions, or even when compared with the canine lymphoma classification, also based on the World Health Organization classification.²⁴ The classification according Hodgkin and non-Hodgkin tumours is based on the presence of the Reed-Sternberg cells. These cells in nearly all Hodgkin lymphomas derive from B cells, and only rarely from T cells. They are very large with abundant pale cytoplasm and two or more oval lobulated nuclei containing large nucleoli.²⁵ The simplicity of the lymphoma classification in ferrets could be due to the lack of a systematic analysis of the existing cases. Even though, in some adult ferrets lymphoma it was seen a high proliferative immunoblastic polymorphous lymphoma with Reed-Sternberg-like cells, similar to

those observed in Hodgkin's-like lymphoma.¹⁴ Furthermore, it is also described a clinical case of Hodgkin's-like lymphoma in a ferret associated to a hyperesosinophilic syndrome.²⁶ Nevertheless, the classification of the lymphoma in ferrets does not take in consideration the existence of the Reed-Sternberg cells.

3. Diagnosis

a. Clinical signs

There are no pathognomonic clinical signs for ferret lymphoma and the clinical presentation can be very unspecific.^{14,16} Ferrets with lymphoma may present with anorexia, lethargy, and weight loss. The occurrence of these clinical signs can be intermittent and the diagnosis can be obtained unintentionally during routine visit, or evaluation for another disease process in ferrets clinically asymptomatic. In some cases, multiple palpable masses can be found during the physical examination.^{10,14,16,27} The presence of enlarged lymph nodes without pyrexia may suggest neoplasia.²⁸

Considering that lymphoma may affect multiple organs, clinical signs will depend on which organ(s) is(are) affected. If lymphoma is mediastinal (figure 1), the most probable clinical presentation will include exercise intolerance and respiratory distress, with coughing, dyspnea, tachypnea, and possibly cyanosis. Difficulty in swallowing and regurgitation may also be observed.^{14,27} These clinical signs are normally the result of thoracic masses and/or pleural effusion, which may muffle heart sounds.²⁷ This type of lymphoma has typically an acute presentation.¹⁴

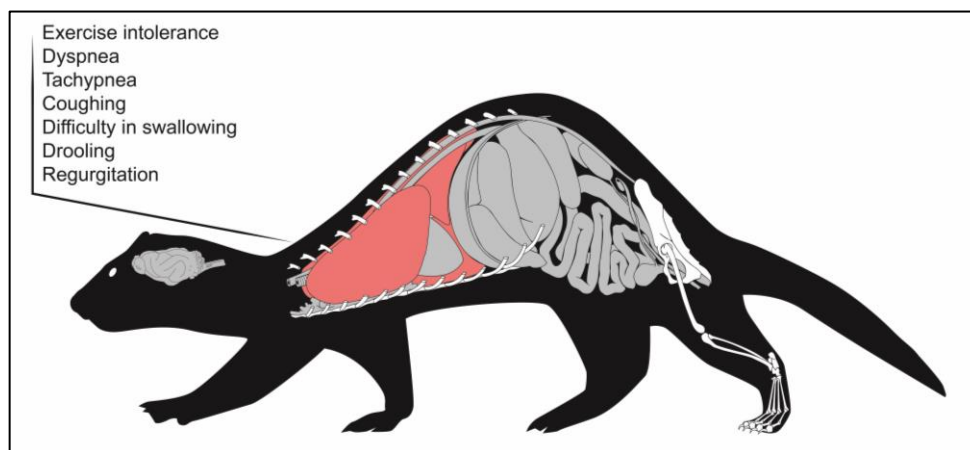


Figure 1. Clinical signs of mediastinal lymphoma

Multicentric lymphoma (figure 2) is characterized by the infiltration of lymph nodes and visceral organs.^{14,27} Initially, the ferret can be asymptomatic,²⁷ but with the disease progression may develop generalized lymphadenomegaly, abdominal masses, hepatomegaly, splenomegaly, or even ascites.^{14,27} The enlarged lymph nodes tend to be painless, irregular, and movable.²⁷

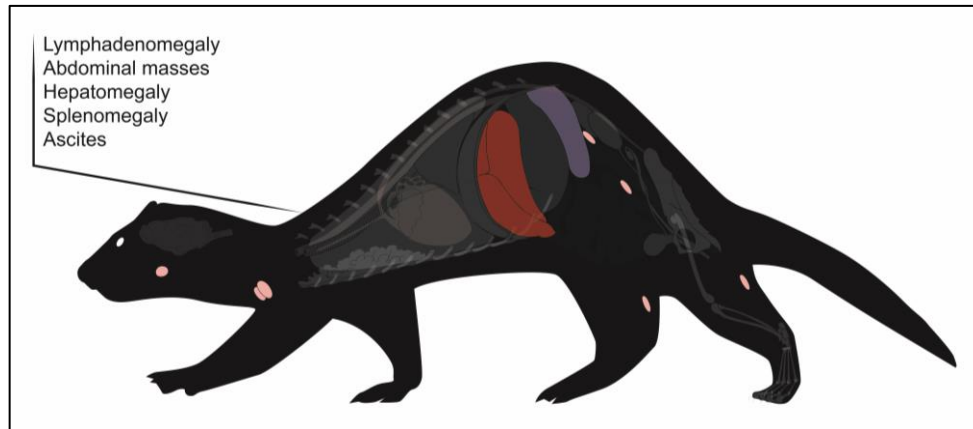


Figure 2. Clinical signs of multicentric lymphoma

If the infiltrated system organ is the gastrointestinal tract (figure 3), the clinical history can include anorexia, weight loss, lethargy, and abdominal discomfort. When it is a gastric lymphoma, the clinical signs can be very nonspecific, but if there is ulceration, the ferret can present melena and, in severe cases, pale mucous membranes. If the tumours location is the pyloric antrum, it can occur an obstruction of gastric emptying, and consequently vomiting. On the other hand, if lymphoma affects small and large intestines, diarrhea could occur. If there is intestinal infiltration of lymphoma or sublumbar lymphadenopathy, the ferret can also present tenesmus due to intestinal straining, or even obstruction.^{7,13,14,27}

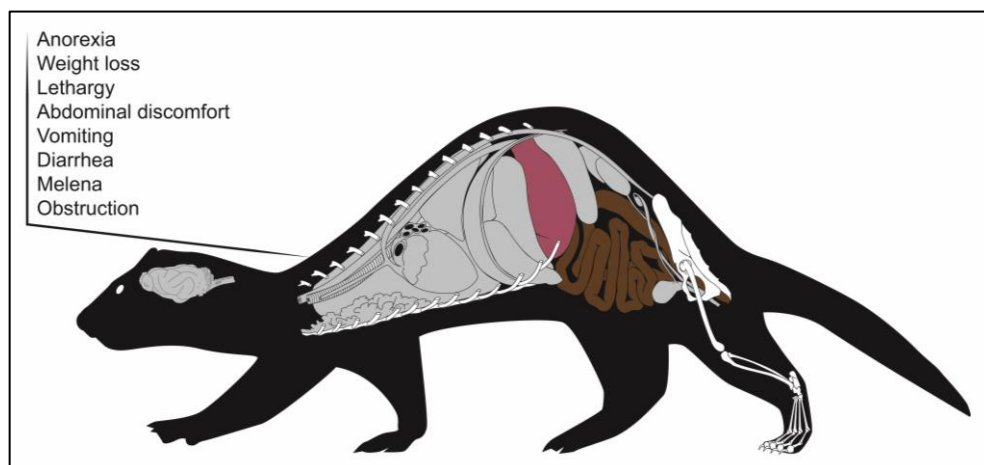


Figure 3. Clinical signs of gastrointestinal lymphoma

Nonepitheliotropic cutaneous lymphoma (figure 4) in ferrets is characterized by lymphatic dissemination.²⁹ The cutaneous lymphoma is uncommon in ferrets, and it is usually seen as a single or multiple masses or plaques on the skin, generally in the extremities that become swollen and hyperemic.^{7,27} The lesions tend to be firm and spherical, with dermal thickening, and the large nodules may ulcerate and form crusts.¹⁴

The epitheliotropic malignant lymphoma (figure 4) is a neoplasm of T lymphocytes, and normally arises with diffuse generalized alopecia, erythema, erosions, crusts, and ulcerated plaques. It seems to have predilection for the epithelium.²⁹ This type of lymphoma is not very frequent, but a previous study reported a case of mycosis fungoides, a cutaneous epitheliotropic T-cell lymphoma. This cutaneous epitheliotropic T-cell lymphoma was characterized by crusting, scaling, and erythema, and presented an infiltration of the epidermis by neoplastic lymphocytes that could extend into the dermis and hair follicles.⁷ This condition may be pruritic, with dermal thickening, and ulceration.^{14,27} A preputial lymphoma has also been reported as an ulcerated mass around the prepuce.³⁰

Ferrets with lymphocytic leukemia (figure 5) are usually very lethargic, anorexic or inappetent, debilitated, and may be febrile.¹³ When the bone marrow is affected, it can occur anemia, and the ferret may also present pale mucous membranes.²⁷

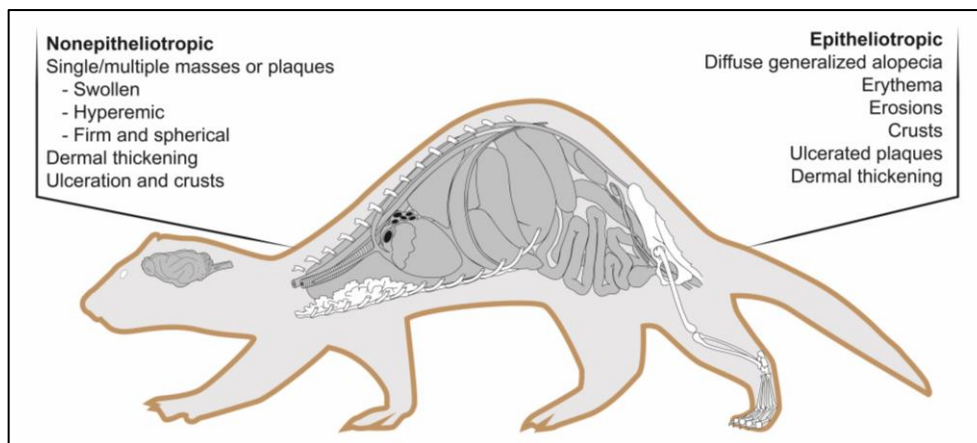


Figure 4. Clinical signs of nonepitheliotropic and epitheliotropic cutaneous lymphoma

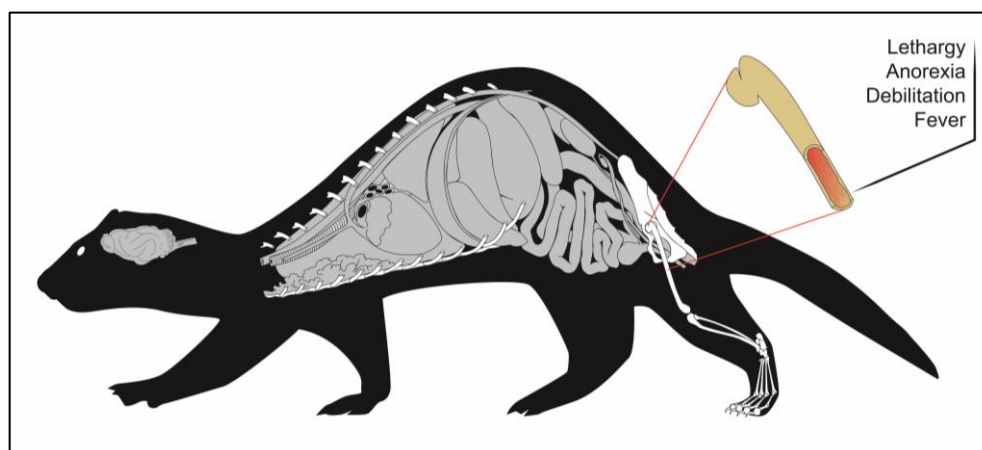


Figure 5. Clinical signs of leukemia

Extranodal lymphomas (figure 6) may affect other structures as solitary tumours, such as periorbital lymphoma, neural lymphoma, bone lymphoma, hepatic and splenic lymphoma, renal

lymphoma, and cardiac lymphoma. In case of periorbital lymphoma, the ferret can have facial deformity, and globe protusion.²⁷ The orbital and retro-orbital lymphoma are rarely seen in ferrets, and can course with unilateral or bilateral exophthalmos, protrusion of the nictitans, lagophthalmos, and exposure keratitis.^{7,14} There is also a case report of infiltrative lymphoplasmacytic keratitis in a 2-years-old ferret with multicentric lymphoma.³¹

In neural lymphoma, the clinical signs can include dementia, seizures, and paralysis.²⁷ There is a report of a ferret with a diffuse central nervous system lymphoma characterized by the involvement of the meninges, the choroid plexus, the brain, and the spinal cord.¹⁰ If the location of the lymphoma is the spinal cord, ferrets can present a fast progressing paraparesis.^{7,14,27} In fact, Hanley *et al.*³² reported a T cell lymphoma in the lumbar spine of a ferret that was paraparetic and with neurologic alterations consistent with lesion in L4 to S3 spinal cord segments. However, primary spinal lymphoma is rare. Normally, it is a consequence of the release of neoplastic lymphocytes from the bone marrow to the peripheral circulation, and occurs predominantly in juvenile ferrets with mediastinal lymphoma.⁷

Additionally, lymphoma can affect the bone structure, which may be associated with lameness and paresis.¹⁴ It has been described a clinical case of myelo-osteolytic plasmablastic lymphoma of the femur in a ferret that presented lameness of the right hind limb and pain during palpation.³³ There are also described clinical cases of lymphoma in the tibia. When there is skeletal involvement, the lymphoma can cause aggressive osseous lesions that have a predominantly lytic-destructive pattern, and cortical disruption.^{10,14}

Other lymphoma locations include the hepatic and splenic forms that can cause icterus, anemia, abdominal distention, and discomfort due to the development of splenomegaly, and renal lymphoma with renomegaly and signs of renal failure. Lastly, it can also occur cardiac lymphomas that are associated to the development of arrhythmias.^{13,27} The most common extranodal lymphomas are the splenic, the renal, and the hepatic.¹⁴

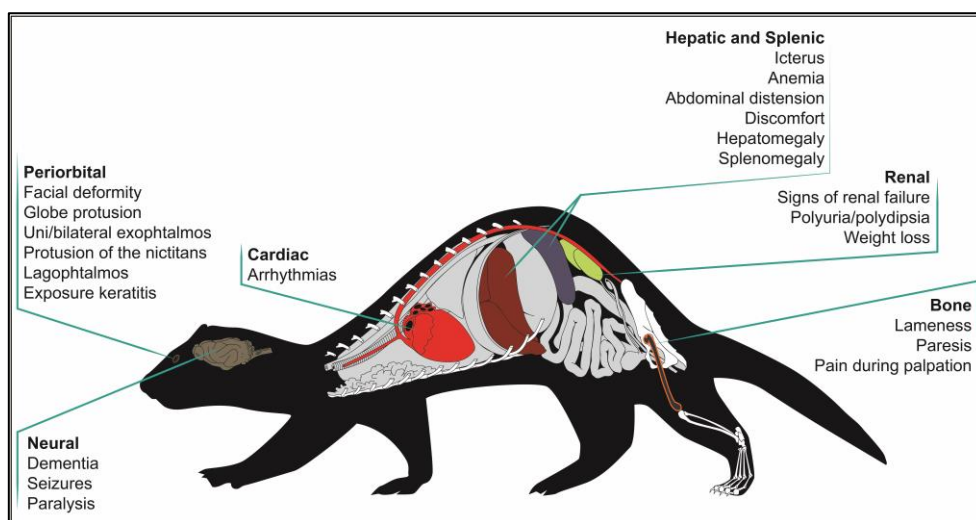


Figure 6. Clinical signs of extranodal lymphomas

Although the association between disease presentation and age of the ferret is not completely demonstrated,¹⁶ there are some types of lymphomas that occur tendentially in certain ages. Mediastinal lymphoma is more common under 1 year of age, and may occur until 5 years of age, leukemia tends to occur between 1 and 3 years of age, multicentric lymphoma is more frequent between 4 and 7 years of age, and solitary lymphomas occur mainly between 6 and 7 years of age.¹⁴ Moreover, Antinoff *et al*¹³ reports that approximately 71% of ferret lymphomas diagnosed in his practice were affecting the abdomen, 33% were affecting the peripheral lymph nodes, and only 17% were located in the thorax.

Finally, ferrets with lymphoma are immunocompromised, and therefore they become vulnerable to opportunistic infections and may develop secondary infections by *Actinomyces* sp., *Cryptococcus* sp., severe periodontal disease, and septicemia.¹⁴ There are also reports of mycobacterial infections in ferrets with lymphoma which has been associated to the immunosuppression.^{34,35} There is a case report of demodectic mange also associated with lymphoma in a ferret. *Demodex* sp. are commensals in the hair follicles and sebaceous glands, and can multiply with a immunological deficiency condition.³⁶

b. Differential diagnosis

Due to the lack of pathognomonic signs, several differential diagnoses must be investigated. Considering that one of the most frequent clinical signs is lymphadenomegaly, it is important to differentiate it from other conditions, namely subcutaneous fat that surrounds the peripheral lymph nodes especially in obese ferrets, and reactive lymph nodes.²⁷ The gastric lymph nodes are frequently reactive to any gastrointestinal process, whereby it is important to differentiate between lymphadenopathy and reactive nodules due to chronic gastrointestinal inflammatory or infiltrative disease, such as *Helicobacter mustelae* gastritis, lymphoplasmacytic gastroenteritis, eosinophilic gastroenteritis, ferret coronavirus, or epizootic catarrhal enteritis.^{13,27} In addition, it is also important to consider that, when the mesenteric lymph nodes are the only affected area, hyperplasia is more likely than neoplasia.²⁷

Splenomegaly, that can sometimes lead to suspicions of lymphoma, should be differentiate from the splenomegaly that occurs gradually with age and is apparently normal in ferrets, being extramedullary hematopoiesis the most common cause of an enlarged spleen in ferrets.^{7,27,28} Therefore, cytological evaluation of an aspirate of the spleen should be cautiously interpreted, since bizarre-looking lymphocytes found on spleen aspirates with polymorphic lymphomas may sometimes be confused with megakaryocytes seen in hematopoiesis, or multinucleated giant cells seen in granulomas.¹⁴

When the ferret presents gastrointestinal clinical signs suggesting an alimentary lymphoma, it is necessary to discard other differential diagnoses with similar presentation, such as foreign body ingestion, intestinal ulceration, epizootic catarrhal enteritis, inflammatory bowel disease,

intussusception, or other gastrointestinal tumours,²⁷ such as pyloric adenocarcinoma, leiomyoma, and leiomyosarcoma.¹³

The mediastinal form of lymphoma with pleural effusion may also be confused clinically with congestive heart failure, pneumonia, chylothorax, hemothorax, or thymoma.^{14,27}

The cutaneous lesions associated to lymphoma may be related to other processes, such as mast cell tumours or other cutaneous neoplasms, such as sebaceous epitheliomas, and cutaneous hemangiomas, or chronic inflammatory disease.^{27,29}

If the ferret present an aggressive bone lesion, it is important to differentiate it from other neoplastic diseases, such as osteosarcoma, fibrosarcoma, chondrosarcoma, primary soft tissue tumours with bone invasion, and infectious diseases.³³

c. Complementary exams

i. Hematology and serum biochemistry

Considering the nonspecific clinical signs and the extensive list of differential diagnoses, it is important to evaluate hematologic and biochemical alterations. The first step should be blood collection. The cranial vena cava may be used to collect blood, but usually needs sedation to avoid vessel laceration.³⁷ However, it must be considered that some anesthetics, such as isoflurane, may induce splenic sequestration of red blood cells, inducing an erroneous interpretation of the hematologic parameters.¹⁴ For this reason, a previous study pointed that the most accessible and convenient site to obtain a blood sample is the jugular vein,³⁷ which can be easily used in awake ferrets.¹⁴

To avoid hemodynamic imbalance, a safe blood sample volume shall not exceed 7.5% to 10% of whole blood volume (whole blood volume is 5% to 6% of body weight), and a smaller volume in geriatric, anemic, hypoproteinemic, or ill ferrets (0.5% of body weight).³⁷

Although the diagnosis of lymphoma should not be based just on hematologic parameters, it is common present some alterations,¹⁴ such as a mild nonregenerative anemia (under 45%)^{7,11,14,16,27} that may be severe in ferrets with leukemia.²⁷

Bone marrow involvement can lead to leukocytosis or leukopenia,¹³ with lymphocytosis or lymphopenia. Young ferrets with mediastinal lymphoma tend to have atypical lymphocytosis that may vary between 10 000 and 70 000 cells/ μ L.^{7,14} On the other hand, older ferrets may present a normal lymphocyte count, or even lymphopenia.⁷ In fact, lymphocytosis is considered prodromal, and as the disease progresses it may give rise to lymphopenia.¹⁴ Neutropenia and thrombocytopenia are unusual findings, at least in an initial phase.^{16,27} Considering that lymphopenia and anemia can also be the consequence of chronic stress or viral infection,⁷ and lymphocytosis could be chronic and associated to a smoldering infection, the diagnostic of lymphoma needs more than a complete blood count.¹⁶

The study of the serum biochemistry alterations, according to the organ system affected, may also give important information.^{13,14,16} When the lymphoma affects the liver, high alanine aminotransferase and alkaline phosphatase activity is common.^{7,13,14,27} If the kidney is involved, the

impaired kidney function can lead to azotemia.^{7,13,14} Occasionally, ferrets presenting T-cell lymphoma may develop hyperproteinemia, hyperglobulinemia, and hypercalcemia, although these are rare findings.^{7,13,14,16,27} Hypoalbuminemia can also occur in association to small intestinal lymphoma.¹⁶ Hypercalcemia and hypoglycemia are paraneoplastic syndromes occasionally seen, but rare.^{7,13,14,16} Urinalysis is usually normal, unless there is a renal failure.²⁷

ii. Imagiology

Radiographs can be useful, but should never be considered diagnostic.¹⁶ In ferrets with mediastinal lymphoma, radiographs may exhibit signs of pleural effusion, sternal or tracheobronchial lymphadenomegaly, widened mediastinum and thoracic masses.^{7,13,14,16,27} Mediastinal masses are normally radiodense masses in the cranial thorax, and cause dorsocaudally deviation of the heart and lungs.¹⁴ In a study of 14 ferrets with lymphoma, the most common thoracic finding was mild pleural effusion.¹⁰

Sublumbar or mesenteric lymphadenomegaly may be identified by abdominal radiography,²⁷ as well as hepatomegaly, renomegaly, and splenomegaly.^{13,16,27} Radiographs can equally be useful to detect intestinal masses or abdominal effusion,²⁷ and to evaluate bone lesions that in lymphoma tend to be lytic with bone dissolution.¹⁴

However, it is important to be aware that the absence of radiographic changes does not discard the possibility of lymphoma, as well as their presence does not ensure the existence of lymphoma.¹⁶

When spinal lymphoma is suspected, it can be still relevant to perform a myelography,¹³ or a computed tomography that can show bone lysis and the presence of masses.³²

Ultrasonography seems to be the most valuable imaging method to evaluate ferrets with lymphoma.^{16,7} Considering that lymphadenopathies and masses are normally hypoechoic,¹⁰ ultrasonography allows the evaluation of abdominal and mesenteric lymph nodes,¹⁶ the detection of mesenteric or sublumbar lymphadenomegaly, nodules,²⁷ as well as the existence of peritoneal effusion.¹⁰

In ultrasonography of the mesenteric lymph nodes, it is important to moderate the pressure in their search because excessive pressure can displace the lymph node dorsally, and cause confusion with the adrenal glands. According to an ultrasonography study performed in 28 healthy ferrets, the mean dimensions of the mesenteric lymph nodes (+/- standard deviation) were 12.6 (+/- 2.6) mm in length by 7.6 (+/- 2.0) mm in width.³⁸

By ultrasonography it is also possible to assess abdominal organs as the liver, spleen, kidney, and mediastinum, in order to evaluate alterations on their size and structure, which could be associated to an infiltrative disease.^{7,13,16,27} The gastrointestinal tract can also be evaluated in order to detect enlarged lymph nodes and masses.²⁷

Thereby, ultrasonography allows the study of lymphadenopathies and masses, and the achievement of a guided fine needle aspirate of affected areas, organs, and lymph nodes, procedure that could be determinant in the diagnosis of lymphoma.^{7,14,21,27} Nevertheless, considering that some organs may have no abnormalities, or only present a small modification in echogenicity and still be

infiltrated, ultrasonography should be considered only a complementary method in the diagnosis of lymphoma.¹³

iii. Cytology/biopsy/immunohistochemistry

In order to achieve a more accurate diagnostic, it is possible to obtain a fine needle aspirate from lymphadenopathies and to perform a cytological evaluation. If a lymphoma is present, the cytological analysis may evidence the presence of monomorphic and atypical lymphoid cells, without components of peripheral blood. Otherwise, if the population of cells is variable in cell size and type, or if there are other types of white blood cells, it is probably not a lymphoma.¹⁶ It is also important to take in consideration that cytology using the fine needle aspirate, even though being a useful noninvasive and precocious method of diagnostic for lymphoma in ferrets,¹¹ is associated to the occurrence of false-negative results.^{12,13,21,27}

Therefore, to confirm the diagnostic, it is necessary to perform an histopathological analysis using tissue from incisional or excisional biopsies.^{7,10,12-14,21,27,28,39} The samples can be harvested from lymph nodes, bone marrow, liver, or spleen,⁷ as well as from masses or from effusions.⁴⁰

In the case of popliteal lymph node, due to its accessibility, it is possible to perform a nodectomy.^{21,27,28} The nodectomy can be easily done by finding the lymph node that is close to the surface, and probably enclosed by fat, and dissecting it out.²⁸

The histopathological analysis of the biopsy may evidence the existence of a monomorphic population of neoplastic lymphocytes,^{7,14,16,27} with pronounced nuclei, protuberant nucleoli, and small amount of cytoplasm,¹⁶ that destroys the architecture of the affected tissue, and replaces the normal parenchyma,^{7,14,27} as well as an increased number of cells in mitosis.¹⁶

Since hyperplastic lymph nodes can also present alterations of their architecture, sometimes it can be difficult to distinguish malignant lymphoma from a simple benign proliferation of lymphocytes based on the histopathological analysis.^{14,41,42} In these situations, it is important to use molecular methods, such as polymerase chain reaction (PCR), in order to evaluate the existence of clonality among cells. Assuming that clonality defines malignancy, since all malignant cells provide from one single malignant clone, the presence of a polyclonal population may indicate a reactive lymphocytosis.^{41,42} In addition, considering that cells from lymphoma often demonstrate altered expression of antigens, it is also possible to detect by flow cytometric immunophenotyping, the existence of aberrant antigen expression.^{12,18,43}

Bone marrow aspiration and biopsy are indicated when complete blood counts give the information of a nonregenerative anemia, leukopenia, thrombocytopenia, or when there are signs of circulation of neoplastic cells in the peripheral blood.^{14,27,40} Besides, the analysis of bone marrow may give knowledge of the evolution of the disease.¹⁴ This procedure involves the use of a 20-gauge, 1.5-in spinal needle, or a core bone biopsy, and can be made on proximal femur, medial to the greater trochanter, with advancement and rotation movements.^{14,16} In case of lymphocytic leukemia, it is usually found hypercellularity and a monomorphic population of neoplastic lymphocytes, with replacement of normal bone marrow components.^{7,16}

In a spleen aspirate of a ferret with lymphoma, it is also expected to find an uniform population of abnormal lymphocytes and mitotic figures, but the presence of red blood cells precursors, megakaryocytes, or a large amount of peripheral blood is more suspicious of extramedullary hematopoiesis.¹⁶

4. Treatment

After reaching a definitive diagnosis, the next step will be the choice of the most adequate treatment. There are many possibilities for the treatment of lymphoma, such as surgery, chemotherapy, radiation therapy, or a combination of two or more types of therapy^{14,15,32,33} The treatment should be chosen according to remission rates, effectiveness, and adverse effects, as well as ferret's age, tumour location, and concurrent disease.^{7,16}

a. Surgical indications

If there is a solitary abdominal or cutaneous tumour easily accessible without the compromise of main vessels or nerves, or focal masses that are possible to remove without impair the involved organs function, surgery is considered the first line treatment since it may allow the removal of the tumour.^{7,14,15,27,33,44} Furthermore, surgery is also the first option when tumour induces intestinal obstruction.²⁷ Even when lymphoma affects the bone, it can be useful to perform surgery. In fact, in myelo-osteolytic plasmablastic lymphoma in the femur, a caudal hemipelvectomy could be the adequate treatment.³³ Splenectomy may also be a possibility when the spleen is infiltrated in such a way that occupies half of the abdominal cavity.^{7,14,15} However, before performing a splenectomy, it is advisable to analyze a bone marrow aspirate to ensure that the extramedullary hematopoietic function achieved by spleen is not essential.⁷ Nevertheless, it may also be benefic to associate other modalities of treatment, such as chemotherapy, to prevent potential postoperative development of micrometastasis.⁴⁵

b. Chemotherapy options and protocols

The treatment of lymphoma in ferrets is often based in chemotherapeutic drugs,³³ being this neoplasia considered one of the most responsive to chemotherapy.¹³ Ferrets have a good tolerance to continued treatments,²⁸ with good response and minor adverse effects.¹³ Chemotherapy can be used as adjuvant therapy to treat lymphoma systemically after surgical removal of a solitary mass, as neoadjuvant therapy in an attempt to reduce tumour size before surgery, or sometimes as the only therapy.⁴⁵ In any case, chemotherapy aims to reduce the proliferation ability of the tumour cells and to increase the tumour cell death through apoptosis, in order to prevent tumour growth and metastasis, and to extend the lifetime with quality.^{15,45}

There are numerous protocols suggested for the treatment of ferret lymphoma. The choice of the protocol is dependent on the costs, accessibility of medication, and easiness of administration,¹⁶ but

should also take into account the age of the ferret,^{7,15} type and location of lymphoma, and concurrent pathologies.^{7,13,15} Special attention must be given when more than 50% of bone marrow is compromised,^{7,40} or when the patient has concomitant pathologies, such as insulinoma or hyperadrenocorticism, which is common in ferrets.^{14,27} In spite of the chemotherapy advantages, it is crucial to balance the benefits and the risks. This is why the veterinarian should perform a complete evaluation of the ferret before initiate the chemotherapy protocol, including a complete blood count, serum biochemistry, radiographs, ultrasonography, cytology of fine needle aspirates, and analysis of bone marrow aspirate.^{7,28,40} Ferrets medicated for a long time with corticosteroids, which is common in patients with insulinoma or inflammatory bowel disease, are more likely to develop multidrug resistance and, therefore, are poor candidates for chemotherapy.^{7,13-16,27,40}

Whenever the chemotherapy protocol involves intravenous administrations, it is essential to place an intravenous catheter, and sedate the patient.^{7,13,27,28,33,40} This may avoid the risk of extravasation, especially when using irritants substances that can cause necrosis.^{7,13,33} It is also important to ensure patency before administering the chemotherapeutic agents by flushing heparinized saline,^{28,40} except when the drug is doxorubicin, that requires the use of non-heparinized saline,²⁸ since it precipitates when contacts with heparin.⁴⁰ Recently, vascular access ports were used as an alternative to the conventional intravenous catheter.^{7,13-15,27,32,46} Vascular access ports are subcutaneous implants that enable recurrent administration of intravenous drugs in the jugular vein, in a more safe process, with much less stress for the ferret, and without the necessity of sedation for each administration.^{13,14,46}

Chemotherapy can be based on the use of a single drug, or in a combination of drugs.^{13,16} However, better results are usually obtained when several drugs with different mechanisms of action are combined, in order to achieve the maximum tumour destruction.^{15,16} There are numerous published protocols of chemotherapy to the treatment of ferret lymphoma, many of them extrapolated from dog and cat. However, in ferrets there is little feedback of results, which turn difficult the comparison of results.^{7,15,16} With chemotherapy, the highest reported survival in ferrets is about 11 to 23 months.^{7,33} Ammersbach *et al*¹¹ has determined in his study that the mean survival time in ferrets treated with chemotherapy was 4.3 months in T-cell lymphoma cases, and 8.8 months in B-cell lymphoma cases, but more studies are still needed, especially with more uniformity in diagnosis and treatment.

The first chemotherapy protocol reported in ferret lymphoma included L-asparaginase, prednisone and cyclophosphamide.¹⁵ L-asparaginase is an enzyme that causes depletion of L-asparagine, thereby preventing the protein synthesis and causing death of the tumour cells which lack asparagine synthetase.⁴⁷ Prednisone is particularly useful in hematopoietic tumours due to its effect of cytotoxicity. The mechanism of action of this corticosteroid involves binding to glucocorticoids receptors of hematological cells to induce apoptosis.^{45,48} Cyclophosphamide is an alkylating agent that promotes DNA cross-link, preventing its replication and cell division.^{45,49} This protocol resulted in complete remission of lymphoma after 21 weeks of treatment in the case report.¹⁵

The COP (cyclophosphamide, vincristine and prednisone) protocol, used in dogs and cats, was extrapolated to the treatment of lymphoma in ferrets with satisfactory results.^{14-16,27,28,40,50} The effect of

cytotoxicity of vincristine, a vinca alkaloid, is linked to its ability to prevent the formation of the mitotic spindle.^{45,49} Afterward, it was suggested a modified COP protocol, the L-COP protocol (figure 7), that added the administration of L-asparaginase three days before initiating the COP protocol.^{13,15,27} This alteration can be useful in cases of peripheral lymphadenomegaly.²⁷ Antinoff *et al*¹³ described improvement in clinical signs and quality of life in 85% of the ferrets treated with this protocol.

The CHOP (cyclophosphamide, doxorubicin, vincristine and prednisone) protocol, also adapted from the treatment of dogs and cats, offers a more complete approach by adding doxorubicin.¹⁶ Doxorubicin is an antitumour antibiotic that has multiples mechanisms of cytotoxicity, including DNA damages by alkylation, and inhibition of topoisomerase II which impedes DNA replication.^{45,49}

Another chemotherapy protocol (figure 8) was recommended by Rosenthal,⁵¹ adding methotrexate which is an antimetabolite that replaces natural metabolites, and inhibits cell division.^{45,49} This protocol includes vincristine, L-asparaginase, prednisone, cyclophosphamide, doxorubicin, and methotrexate (L-VCAMP protocol).⁵¹

However, even being recommended intravenous chemotherapy for ferrets,³³ sometimes it is difficult to implement these protocols. Some owners do not accept the use of the invasive and aggressive techniques which may turn impractical to submit weekly the ferret to the risks of sedation or accidental extravasation of chemotherapeutical agents.^{21,33} In response to the need for a noninvasive protocol that would simplify chemotherapy, a non-intravenous protocol (figure 9) was developed particularly for ferrets.^{14-16,21,28,33} This protocol uses prednisone, L-asparaginase, cyclophosphamide, cytarabine, methotrexate, chlorambucil, and procarbazine.^{14-16,28} Cytarabine, as methotrexate, is an antimetabolite that inhibits the synthesis of DNA during the S phase of the cell cycle. Chlorambucil is an alkylating agent and its cytotoxicity is related to the bifunctional alkylating capacity, which origins DNA cross-link and impedes replication.^{45,49} Procarbazine is also an alkylating agent that generates toxic metabolites to inhibit DNA and RNA synthesis, and cause DNA methylation.⁴⁵

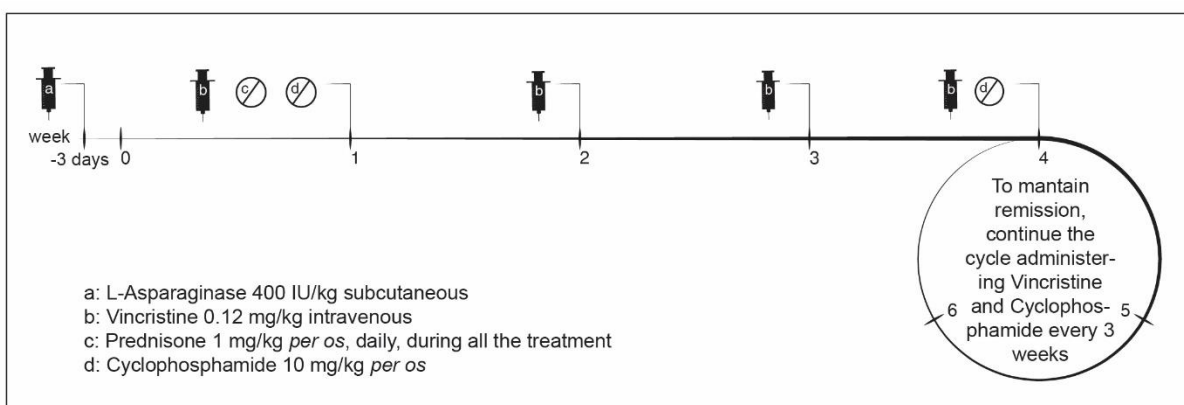


Figure 7. L-COP protocol for ferret lymphoma

Adapted from Antinoff N, Hahn K: Ferret oncology: diseases, diagnostics, and therapeutics. *Vet Clin North Am Exot Anim Pract* 7:579-625, 2004.

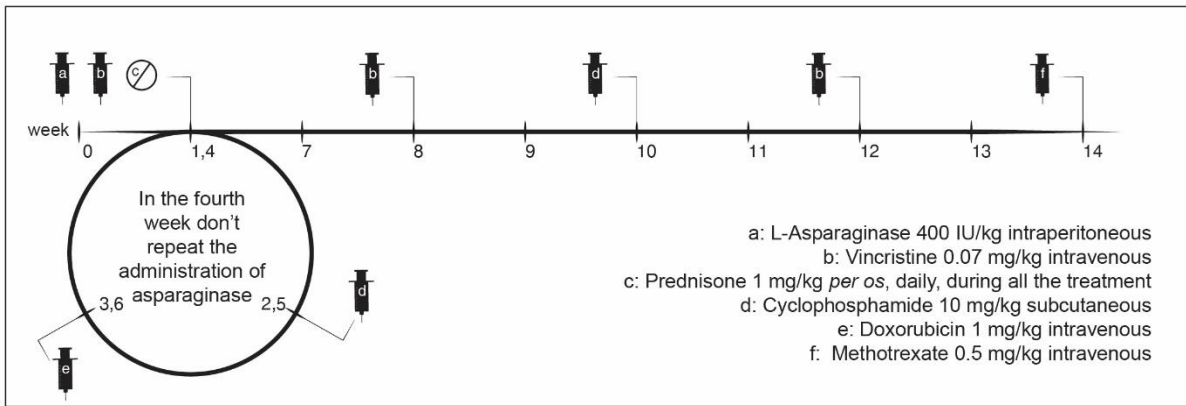


Figure 8. L-VCAMP protocol for ferret lymphoma

Adapted from Rosenthal K: Ferrets. *Vet Clin North Am Small Anim Pract* 24:1-23, 1994.

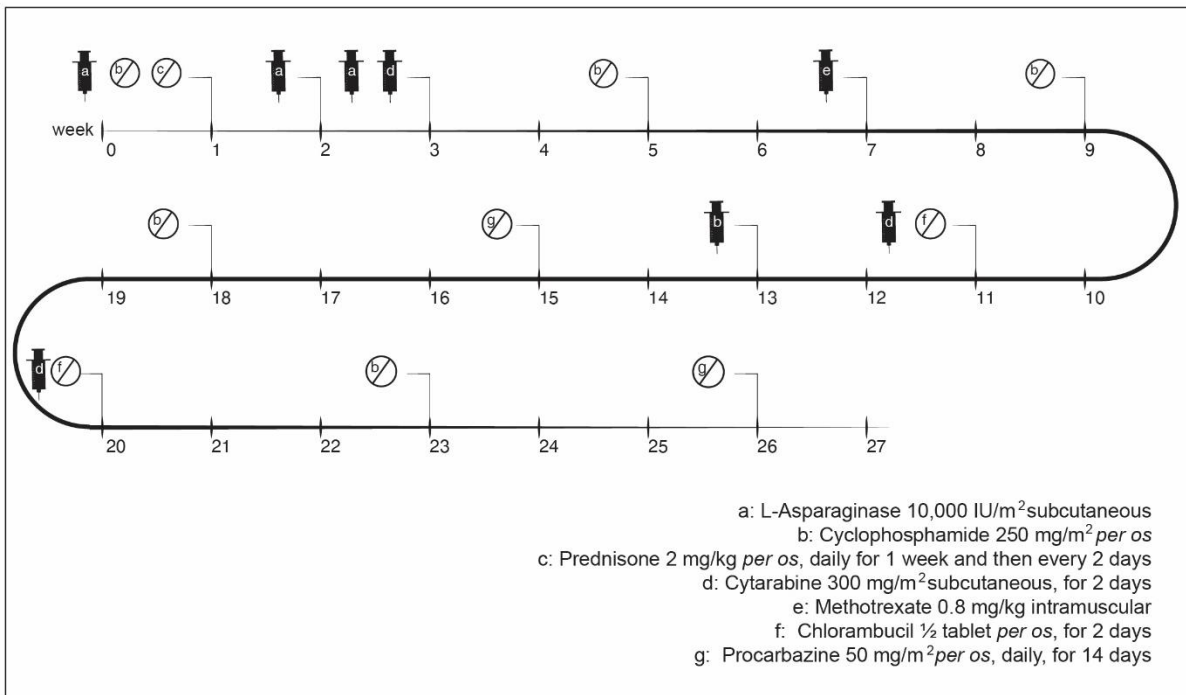


Figure 9. Noninvasive protocol for ferret lymphoma

Adapted from Mayer J, Erdman S, Fox J: *Diseases of the Hematopoietic System*, in Fox J, Marini R (eds): *Biology and Diseases of the Ferret* (ed 3), Ames, IA, Wiley-Blackwell, pp 311-327, 2014

Unfortunately, the treatment of ferret lymphoma is not curative; it only can provide a clinical remission. The size reduction of the tumour, improvement of clinical signs, and normal complete blood count values may indicate a clinical remission.^{15,40} However, biopsies may still present persistence of lymphoma.^{14,40} Remission duration may be very variable, from months to years. Complete blood counts should be made every 1 to 3 months to achieve an early detection of relapses.^{14,15,40}

When the ferret relapses after achieving remission, it is possible to attempt a rescue protocol, which can be obtained through the combination of doxorubicin with prednisone, or through the use of other method of treatment, such as radiotherapy.^{13,16,27}

In ferrets in which chemotherapy is contraindicated by the associated risks, it may be preferable to opt by a palliative treatment with prednisone alone, avoiding more aggressive drugs. This option can also be considered when the owners are not willing to allow chemotherapy, either because they can't afford or because they are against the use of these drugs. Lymphoma responds well to the treatment with corticosteroids, which decrease tumour size, help to control clinical signs and improve quality of life at short term.^{7,13,14,16,27,32,40} Besides, ferrets tolerate well the use of high-dose corticosteroids, without gastrointestinal side effects.⁷ The main problem of using this type of treatment is, as previously mentioned, multidrug resistance development, which complicates posterior treatments with chemotherapeutic agents.^{7,16,27,40,45} It may also be useful to combine prednisone with cyclophosphamide at lower doses, or with longer pauses, in order to minimize adverse effects.^{13,16}

Chemotherapy is associated to numerous side effects, which can be immediate (24 to 48 hours after the treatment), acute (a few days after) or chronic (weeks to years after). In any case, the owners should be previously informed. Immediate side effects include hypersensitivity reactions.⁴⁵ Therefore, before the treatment with L-asparaginase and doxorubicin, it is advisable to administrate diphenhydramine (0.5 to 2 mg/kg intramuscular) to avoid anaphylactic effects.^{13,27}

Other secondary effects of chemotherapy may include lethargy, fever, anorexia, vomiting and diarrhea, mild alopecia (frequently beginning with whiskers loss), and weakness.^{7,13,15,16,27,28,40} The ferret can also present dyspnea and, less frequently, collapse.^{7,28,40} These signals of toxicity may happen a few days after the treatment,^{28,40} and for this reason it is important to separate administrations, in order to conclude which is the causative chemotherapy agent, and reduce the dose in 20%.¹⁶

Beyond these side effects, corticosteroids can induce polyuria, polydipsia, and weight gain,¹³ doxorubicin has cumulative and dose-related cardiotoxic effects,^{27,45} and cyclophosphamide was associated with the development of cystitis in one ferret.¹³

However, the most significant adverse effect of chemotherapy is myelosuppression, with subsequent leukopenia (often neutropenia), which predispose ferret to severe secondary infections and sepsis.^{7,13-16,27,33} Therefore, up to 24 hours before each administration of chemotherapeutic agents, it is imperative to perform a complete blood count to ensure acceptable values of white blood cells and packed cell volume.^{7,13,15,16,27,28,33,40} If leukocyte count is below 1000/ μ L,¹⁶ neutrophil count below 1000/ μ L,^{16,27} or packed cell volume below 30%,^{27,40} complete blood count should be repeated every 3 or 4 days and chemotherapy should be delayed until the values return to normal.^{13,16,27,28,40} Cases of severe neutropenia and fever are oncologic emergencies, and supportive care may be necessary with intravenous antibiotics administration and fluid therapy.^{13,15,16,28} Drugs that stimulate white blood cells production may also be useful.²⁸ It is similarly important to perform serum biochemistries to evaluate renal and hepatic functions, which can be affected or worsened by these drugs.^{7,14}

Lastly, it is important to remember that ferrets treated with chemotherapy should suspend all the vaccinations for the rest of their life, to avoid relapses by stimulating the immune system.¹⁶

c. Radiation therapy

Hematopoietic tumours are the most sensitive to radiation therapy.⁵² Being lymphoma highly radiosensitive,^{16,52} adjuvant radiotherapy assumes a significant role in the treatment of this tumour.⁵³ Radiation therapy may be useful firstly to reduce large masses in thorax causing dyspnea, or abdominal and intestinal masses causing obstruction,^{13,16} wherein only one dose can significantly reduce the mass.¹⁶ Nonetheless, it is preferable to apply multiple treatments and, depending on case, it may be used up to 21 treatments in 6 weeks.^{13,16}

It may also be recommended as adjunct therapy,²⁷ or as rescue therapy.^{13,16} The combination of radiation therapy with doxorubicin has once resulted in 23 months of survival.¹⁵ Nevertheless, this treatment is responsible by different periods of remissions in ferret lymphoma.¹⁴ It has also been suggested that radiation therapy could successfully treat multidrug resistant lymphoma.²⁸

Half-body radiotherapy has been used,^{13,15} and in one case it was achieved a total of 12 months of remission with two treatments,¹⁵ but this method can present severe adverse effects. Local radiation therapy is safer and effective.¹³

Adverse effects of radiation therapy can be grouped into two types: acute effects that tend to occur with low doses per treatment, and appear soon after the radiotherapy, and delayed effects that are more associated with higher doses, and usually start 12 months after the treatment.^{52,53} Acute toxicity is usually self-limiting, and involves mainly dermatitis, mucositis, alopecia, humid desquamation, and conjunctivitis.⁵²⁻⁵⁴ The more important caution is to avoid self-trauma, to provide pain management,⁵³ and in some cases it may be necessary to use antibiotics and anti-inflammatory drugs.^{52,54} Late toxicity effects can be difficult to treat,^{53,54} and may include vascular damages, fibrosis, bone necrosis, and myelopathy.⁵²⁻⁵⁴

d. Ancillary therapy

Concerning supportive care in oncology, the provision of an adequate nutrition is very important to avoid cancer cachexia.^{7,16,27,40} Ferret weight should always be monitored.²⁸ As an obligate carnivore, ferret diet should be based on animal protein and fat, and should be low in carbohydrates,² which will also increase the possibility of remission by improving the immune status. Additionally, the presence of omega-3 fatty acids seems to be important in inhibition of the proliferation of tumour cells.^{13,16} If the ferret continues to lose weight, it can also be necessary to encourage him to eat a high-caloric and protein enriched supplement.^{7,13,16,27,28,40} Caution must be taken with anorexic ferrets because they can develop hepatic lipidosis and hypoglycemia. It may be needed assist-feeding with syringe or even by a gastric tube.²

Another very important ancillary therapy is pain management. Pain control is particularly important in oncologic patients, because pain can affect the survival, and also interferes with the life quality of the animal. Moreover, pain may be derived from the tumour itself, but may also be caused by the treatment (surgery, chemotherapy, or radiotherapy). Pain may vary depending on the tumour location and the animal, thus one the best ways to find out if the tumour is causing pain is through palpation, and evaluating the activity and behavior of the patient.⁵⁵ Thereby, it becomes essential to know how to recognize signs of discomfort and pain in ferrets.

A ferret with pain may vocalize with squeals and screams, cry and whimper. The absence of play patterns and decreased activity can also be used as indicators of discomfort, stress, and pain.^{56,57} Other signs of pain in ferrets may include anorexia, weight loss, apathy, hiding behaviour, abnormal aggression, absence of grooming behavior, bruxism, tail piloerection, and trembling.^{1,56,57}

The key to an effective pain management in oncologic patients is multimodal analgesia, providing different drugs with an additive or synergistic effect. This will allow decreasing doses of each analgesic, and consequently minimize side effects.^{55,57} Guidelines to cancer pain treatment were created by the World Health Organization, and include the use of nonsteroidal anti-inflammatory drugs, opioid drugs, and adjuvant drugs, such as N-methyl D-aspartate antagonists.⁵⁵ Nonsteroidal anti-inflammatory drugs, such as meloxicam and carprofen, are widely used in ferrets, and therefore considered safe analgesics in this specie. The use of opioids, such as buprenorphine, hydromorphone, oxymorphone, and tramadol, has also been reported in ferrets. In order to assess the necessity of adding more drugs or dose adjustment, it is very important to perform repeated evaluations of the level of pain that the patient presents.⁵⁷

Following nutrition and pain management, other supportive cares may be required. After chemotherapy, the ferret possibly will need gastrointestinal protectants, histamine H₂-receptor antagonists, and antiemetics to control the gastrointestinal side effects of this treatment. It is advisable to use antiemetics that act on the central nervous system, where is the chemoreceptor trigger zone, such as metoclopramide or maropitant.^{13,15,16} Ferrets that become dehydrated should receive fluid therapy, either intravenously or subcutaneously.^{7,27} In case of anemia, erythropoietin could be used, as well as blood transfusions in severe cases.¹³

The use of antioxidants and herbal therapies has been widely mentioned and used in ferret lymphoma.^{7,13,15,28,32,40} Regarding the use of free radical scavengers during chemotherapy,¹⁶ a review of 33 articles concluded that the use of antioxidants along with chemotherapy does not appear to affect its efficacy and, on contrary, seems to increase the response to treatment and survival in human patients.⁵⁸ Vitamin C (50 to 100 mg/kg orally every 12 hours) has been used in ferrets with lymphoma.^{15,28,32,40} Vitamin E is most often used in radiotherapy patients because of its favorable action on skin.¹³ Pau d'Arco (3 to 5 drops orally every 12 hours) is an herbal product commonly used as a natural antimicrobial that aids the immune system.^{7,13,15,28,32,40} Other natural therapies, such as essiac and pycnogenol has been mentioned, nevertheless the lack of studies cannot prove their efficacy in cancer treatment, or security in combined use with conventional therapies.⁷ Finally,

retinoids such as isotretinoin (2 mg/kg orally every 24 hours), despite not being curative, seem to have a satisfactory effect as a palliative treatment of cutaneous epitheliotropic lymphoma in ferrets^{13,27,29,59}

Acupuncture, with or without electrical stimulation, has also been widely mentioned. Electroacupuncture inhibits pain by activating nerve fibers, and causing liberation of endogenous opioid in the local of the inflammation.⁶⁰ There are numerous studies in humans demonstrating analgesia induced by electroacupuncture, nevertheless there is lack of studies proving the analgesic efficacy of acupuncture in veterinary medicine.⁵⁵ A recent study has utilized photoacoustic tomography on mice to assess and monitor the effects of acupuncture, and this could be a start to reveal the exact mechanism of actuation and to measure its effects.⁶¹

5. Prognosis

Not being possible to achieve a cure, the prognosis of a ferret with lymphoma tends to be poor.^{7,39} The worst prognostics are related to lymphomas with multicentric distribution,⁴⁰ young ferrets with lymphoblastic lymphoma,⁷ and acute onset, in which the response to the treatment is poor.^{15,50} When the primary tumour is located in gastrointestinal tract, liver, lymph nodes, bone marrow, central nervous system, or in multiple organs, the ferrets are less treatment-responsive as well.^{7,14,15,27} As previously mentioned, there is also a relation between the phenotype and prognosis, wherein T-cell lymphomas tend to have a worst prognosis.¹²

Oppositely, older ferrets with chronic onset of lymphoma and with lymphocytic form, maybe for the slower growth of the tumour, seem to present a better prognosis,^{7,40,50} as well as ferrets with mediastinal, splenic, and cutaneous lymphoma.²⁷

Above all, it is very important to explain to the owners that, although treatment is not curative, during therapy and remission time the quality of life is usually good, and the survival rate is increased when compared to that in non-treated ferrets.^{13,27} Moreover, it is important to consider that, for an animal with a life expectancy of 5 to 8 years,³⁷ 2 years of survival may be nearly or more than a quarter of lifetime.

6. Future directions

As earlier mentioned, a correct diagnosis of lymphoma can be difficult to achieve, especially when the results from cytology and histopathology are inconclusive or doubtful. Besides the previously cited molecular methods to distinguish benign proliferation of lymphocytes from lymphoma, there are other methods applied in human medicine that may be promising in veterinary oncology. Methods such as detection of chromosomal abnormalities and gene expression profiling would allow differentiating reactive and neoplastic lymphocytosis, and could be promisingly used in veterinary oncology, and allow a more specific and accurate diagnostic. Since lymphomas are associated with chromosomal structural alterations, the detection of these abnormalities by cytogenetic techniques can improve the

lymphoma diagnosis and contribute to the establishment of a more adequate therapeutic strategy, and of an accurate prognosis.⁴¹

7. Conclusions

Lymphoma is one of the most common neoplasias in domestic ferrets,⁷⁻¹⁰ and it is their most frequent malignant neoplasia.^{7,10} However, the data regarding the cellular and molecular characterization of lymphoma is scarce, which may limit the establishment of an adequate treatment protocol, and of the prognosis. Until the moment, the selection of the treatment is made according to each case necessities and expectations, which may limit the survival rate.¹⁶ Therefore, more studies are needed to implement appropriate treatment protocols that take in consideration the stage, the grade, and the immunophenotype of the tumour, as well as the characteristics of each patient.

The achievement of new studies that include a large number of lymphomas treated with different protocols should be encouraged, in order to increase the survival time after lymphoma diagnosis.

8. Acknowledges

I would like to express my sincere acknowledges to all of those who somehow made contributions to this dissertation. My sincerely gratitude to my supervisors, Prof. Dr.^a Anália do Carmo and Dr.^a Ana Luísa Vieira, for all the support during this long process. My deepest acknowledges to Prof. Dr.^a Anália do Carmo for all the patience, constant dedication and availability, and to Dr.^a Ana Luísa Vieira for all the advices and recommendations.

I am also grateful to all the team of Centro Veterinário Conimbricense, especially to Prof. Dr. Nuno Cardoso, Dr.^a Andreia Freire and Dr. Pedro Silva, for receiving me so well, and always share their knowledge.

I would also like to extend my sincerest acknowledgments to all the team of Hospital Veterinario El Bosque, especially to Dr. Antonio Rodríguez, for all the hospitality and availability.

My sincere thanks to all my friends and colleagues for helping and supporting me during this process, and especially to Inês, who have accompanied me throughout almost all my life, for all her precious friendship.

My deepest gratitude to all my family, especially to my mother Rosa for her unconditional love, friendship, patience, for being my examples of strength and perseverance, and for always believe in me.

Last but not least, I am very grateful to my boyfriend Francisco Semião, who made important contributions by creating the artwork of this article, and for all the comprehension, support, and love.

Thanks to them all for make this dissertation possible.

9. References

1. Bixler H, Ellis C: Ferret care and husbandry. *Vet Clin North Am Exot Anim Pract* 7:227-255, 2004
2. Johnson-Delaney CA: Ferret nutrition. *Vet Clin North Am Exot Anim Pract* 17:449-470, 2014
3. Fox J: Taxonomy, History, and Use, in Fox J, Marini R (eds): *Biology and Diseases of the Ferret*, Ames, IA, Wiley-Blackwell, pp 5-16, 2014
4. Church B: Ferret Biology, Natural History, and Behavior, in *Proceedings of the North American Veterinary Conference*, Vol 21. Orlando, Florida, pp 1636 – 1639, 2007
5. Castanheira de Matos R, Morrissey J: Common procedures in the pet ferret. *Vet Clin North Am Exot Anim Pract* 9:347-365, 2006
6. Wenker C, Christen C: Ferrets in veterinary practice. *Schweiz Arch Tierheilkd* 144:575-584, 2002
7. Hess L: Ferret Lymphoma: The Old and the New. *Seminars in Avian and Exotic Pet Medicine* 14:199-204, 2005
8. Onuma M, Kondo H, Ono S, *et al*: Cytomorphological and immunohistochemical features of lymphoma in ferrets. *J Vet Med Sci* 70:893-898, 2008
9. Gupta A, Gumber S, Schnellbacher R, *et al*: Malignant B-cell lymphoma with Mott cell differentiation in a ferret (*Mustela putorius furo*). *J Vet Diagn Invest* 22:469-473, 2010
10. Suran JN, Wyre NR: Imaging findings in 14 domestic ferrets (*Mustela putorius furo*) with lymphoma. *Vet Radiol Ultrasound* 54:522-531, 2013
11. Ammersbach M, Delay J, Caswell JL, *et al*: Laboratory findings, histopathology, and immunophenotype of lymphoma in domestic ferrets. *Vet Pathol* 45:663-673, 2008
12. Mayer J, Burgess K: An update on ferret lymphoma: a proposal for a standardized classification on ferret lymphoma. *Journal of Exotic Pet Medicine* 21:343-346, 2012
13. Antinoff N, Hahn K: Ferret oncology: diseases, diagnostics, and therapeutics. *Vet Clin North Am Exot Anim Pract* 7:579-625, 2004
14. Mayer J, Erdman S, Fox J: Diseases of the Hematopoietic System, in Fox J, Marini R (eds): *Biology and Diseases of the Ferret* (ed 3), Ames, IA, Wiley-Blackwell, pp 311-327, 2014
15. Fisher PG, Lennox A: Therapeutic Options for Ferret Lymphoma: A Review. *Journal of Exotic Mammal Medicine and Surgery* 1:1-5, 2003
16. Antinoff N, Williams B: Neoplasia, in Quesenberry K, Carpenter J (eds): *Ferrets, Rabbits, and Rodents: Clinical Medicine and Surgery* (ed 3), St. Louis, MO, Elsevier/Saunders, pp 106-115, 2012
17. Erdman SE, Reimann KA, Moore FM, *et al*: Transmission of a chronic lymphoproliferative syndrome in ferrets. *Lab Invest* 72:539-546, 1995
18. Erdman SE, Correa P, Coleman LA, *et al*: *Helicobacter mustelae*-associated gastric MALT lymphoma in ferrets. *Am J Pathol* 151:273-280, 1997
19. Fox JG, Marini RP: *Helicobacter mustelae* Infection in Ferrets: Pathogenesis, Epizootiology, Diagnosis, and Treatment. *Seminars in Avian and Exotic Pet Medicine* 10:36-44, 2001

20. O'Toole PW, Snelling WJ, Canchaya C, *et al*: Comparative genomics and proteomics of *Helicobacter mustelae*, an ulcerogenic and carcinogenic gastric pathogen. *BMC Genomics* 11:164, 2010
21. Mayer J: Update on Ferret Lymphoma, in Proceedings of the The North American Veterinary Conference, Vol 20. Orlando, Florida, pp 1748 – 1749, 2006
22. Coleman LA, Erdman SE, Schrenzel MD, *et al*: Immunophenotypic characterization of lymphomas from the mediastinum of young ferrets. *Am J Vet Res* 59:1281-1286, 1998
23. Hammer AS, Williams B, Dietz HH, *et al*: High-throughput immunophenotyping of 43 ferret lymphomas using tissue microarray technology. *Vet Pathol* 44:196-203, 2007
24. Valli VE, San Myint M, Barthel A, *et al*: Classification of canine malignant lymphomas according to the World Health Organization criteria. *Vet Pathol* 48:198-211, 2011
25. Kuppers R, Hansmann ML: The Hodgkin and Reed/Sternberg cell. *Int J Biochem Cell Biol* 37:511-517, 2005
26. Blomme EA, Foy SH, Chappell KH, *et al*: Hypereosinophilic syndrome with Hodgkin's-like lymphoma in a ferret. *J Comp Pathol* 120:211-217, 1999
27. Oglesbee B: Lymphosarcoma, in Oglesbee B (ed): *Blackwell's Five-Minute Veterinary Consult Small Mammal* (ed 2), Ames, IA, Wiley-Blackwell, pp 141-143, 2011
28. Lewington J: General neoplasia, in Lewington J (ed): *Ferret Husbandry, Medicine and Surgery* (ed 2), Philadelphia, PA, Elsevier/Saunders, pp 319-327, 2007
29. Kanfer S, Reavill DR: Cutaneous neoplasia in ferrets, rabbits, and guinea pigs. *Vet Clin North Am Exot Anim Pract* 16:579-598, 2013
30. Parker GA, Picut CA: Histopathologic features and post-surgical sequelae of 57 cutaneous neoplasms in ferrets (*Mustela putorius furo*). *Vet Pathol* 30:499-504, 1993
31. Miller PE: Ferret Ophthalmology. *Seminars in Avian and Exotic Pet Medicine* 6:146-151, 1997
32. Hanley CS, Wilson GH, Frank P, *et al*: T cell lymphoma in the lumbar spine of a domestic ferret (*Mustela putorius furo*). *Vet Rec* 155:329-332, 2004
33. Eshar D, Wyre NR, Griessmayr P, *et al*: Diagnosis and treatment of myelo-osteolytic plasmablastic lymphoma of the femur in a domestic ferret. *J Am Vet Med Assoc* 237:407-414, 2010
34. Nakata M, Miwa Y, Tsuboi M, *et al*: Mycobacteriosis in a domestic ferret (*Mustela putorius furo*). *J Vet Med Sci* 76:705-709, 2014
35. Saunders GK, Thomsen BV: Lymphoma and Mycobacterium avium infection in a ferret (*Mustela putorius furo*). *J Vet Diagn Invest* 18:513-515, 2006
36. Beaufriere H, Neta M, Smith DA, *et al*: Demodectic Mange Associated With Lymphoma in a Ferret. *Journal of Exotic Pet Medicine* 18:57-61, 2009
37. Smith SA, Zimmerman K, Moore DM: Hematology of the Domestic Ferret (*Mustela putorius furo*). *Vet Clin North Am Exot Anim Pract* 18:1-8, 2015
38. Paul-Murphy J, O'Brien RT, Spaeth A, *et al*: Ultrasonography and fine needle aspirate cytology of the mesenteric lymph node in normal domestic ferrets (*Mustela putorius furo*). *Vet Radiol Ultrasound* 40:308-310, 1999

39. Zaffarano B: Ferrets: Examination and Standards of Care. *Journal of Exotic Pet Medicine* 19:73-81, 2010
40. Wolf T: Ferrets, in Mitchell M, Tully T (eds): *Manual of Exotic Pet Practice*, Vol. St. Louis, MO, Elsevier/Saunders, pp 364-367, 2009
41. Avery A, Olver C, Khanna C, *et al*: Molecular diagnostics, in Withrow S, Vail D, Page R (eds): *Withrow & MacEwen's Small Animal Clinical Oncology* (ed 5), St. Louis, MO, Elsevier/Saunders, pp 133-135, 2013
42. Avery PR, Avery AC: Molecular methods to distinguish reactive and neoplastic lymphocyte expansions and their importance in transitional neoplastic states. *Vet Clin Pathol* 33:196-207, 2004
43. Craig FE, Foon KA: Flow cytometric immunophenotyping for hematologic neoplasms. *Blood* 111:3941-3967, 2008
44. Li X, Fox G, Erdman SE, *et al*: Cutaneous lymphoma in a ferret (*Mustela putorius furo*). *Vet Pathol* 32:55-56, 1995
45. Gustafson DL, Page RL: Cancer chemotherapy, in Withrow S, Vail D, Page R (eds): *Withrow & MacEwen's Small Animal Clinical Oncology* (ed 5), St Louis, MO, Elsevier/Saunders, pp 157-179, 2013
46. Powers LV: Techniques for Drug Delivery in Small Mammals. *Journal of Exotic Pet Medicine* 15:201-209, 2006
47. Keating MJ, Holmes R, Lerner S, *et al*: L-asparaginase and PEG asparaginase-past, present, and future. *Leuk Lymphoma* 10 Suppl:153-157, 1993
48. Greenstein S, Ghias K, Krett NL, *et al*: Mechanisms of glucocorticoid-mediated apoptosis in hematological malignancies. *Clin Cancer Res* 8:1681-1694, 2002
49. Couto C: Practical chemotherapy, in Nelson R, Couto C (eds): *Small Animal Internal Medicine* (ed 4), St. Louis, MO, Mosby/Elsevier, pp 1156-1157, 2009
50. Erdman SE, Moore FM, Rose R, *et al*: Malignant lymphoma in ferrets: clinical and pathological findings in 19 cases. *J Comp Pathol* 106:37-47, 1992
51. Rosenthal K: Ferrets. *Vet Clin North Am Small Anim Pract* 24:1-23, 1994
52. Mauldin GN, Shiomitsu K: Principles and Practice of Radiation Therapy in Exotic and Avian Species. *Seminars in Avian and Exotic Pet Medicine* 14:168-174, 2005
53. LaRue S, Gordon I: Radiation therapy, in Withrow S, Vail D, Page R (eds): *Withrow and MacEwen's Small Animal Clinical Oncology* (ed 5), St Louis, MO, Elsevier/Saunders, pp 180-197, 2013
54. McEntee MC: Principles of adjunct radiotherapy and chemotherapy. *Vet Clin North Am Small Anim Pract* 25:133-148, 1995
55. Duncan B, Lascelles X: Supportive Care for the Cancer Patient, in Withrow S, Vail D, Page R (eds): *Withrow & MacEwen's Small Animal Clinical Oncology* (ed 5), St Louis, MO, Elsevier/Saunders, pp 245-259, 2013
56. Vinke CM, Schoemaker NJ: The welfare of ferrets (*Mustela putorius furo* T) A review on the housing and management of pet ferrets. *Applied Animal Behaviour Scienc* 139:155-168, 2012

57. Van Oostrom H, Schoemaker NJ, Uilenreef JJ: Pain management in ferrets. *Vet Clin North Am Exot Anim Pract* 14:105-116, 2011
58. Block KI, Koch AC, Mead MN, *et al*: Impact of antioxidant supplementation on chemotherapeutic toxicity: a systematic review of the evidence from randomized controlled trials. *Int J Cancer* 123:1227-1239, 2008
59. Rosenbaum MR, Affolter VK, Osborne AL, *et al*: Cutaneous epitheliotropic lymphoma in a ferret. *J Am Vet Med Assoc* 209:1441-1444, 1996
60. Zhang R, Lao L, Ren K, *et al*: Mechanisms of acupuncture-electroacupuncture on persistent pain. *Anesthesiology* 120:482-503, 2014
61. Li T, Xu X, Chen B, *et al*: Photoacoustic imaging of acupuncture effect in small animals. *Biomed Opt Express* 6:433-442, 2015