



Case 1279

Peritoneal pseudocysts

M. Monteiro, T. Cunha, I Duarte, I. Cabral

Section: Genital (Female) Imaging

Published: 2002, Jan. 7

Patient: 45 year(s), female

Clinical Summary

A pelvic mass was detected on routine gynaecological examination in this obese, asymptomatic patient. The patient had undergone left hemicolectomy for colon adenocarcinoma 6 years previously

Clinical History and Imaging Procedures

A pelvic mass was detected on routine gynaecological examination in this obese, asymptomatic patient. The patient had undergone left hemicolectomy for colon adenocarcinoma (pT3N1M0) 6 years previously, complicated by a subphrenic abscess. The patient was re-operated 2 weeks later for drainage, being clinically well since then. Laboratory tests were negative, including tests for tumour markers CA-125, CA-19.9 and CEA. Imaging work-up consisted of suprapubic and transvaginal sonography, helical CT and MRI.

Discussion

Peritoneal pseudocysts (PP), also known as peritoneal inclusion cysts, are benign space-occupying lesions resulting from the accumulation, within peritoneal adhesions, of fluid physiologically released by active ovaries. They appear in pre-menopausal women with a history of peritoneal inflammation, usually secondary to abdominal or pelvic surgery, trauma, bowel or pelvic inflammatory diseases or endometriosis. PP can be clinically silent or cause pelvic mass and discomfort.

Differential diagnosis may include hydrosalpinx, primary para-ovarian cysts and ovarian tumours. Extensive adhesions can form irregular thick septations and complex cystic masses difficult to differentiate from malignant ovarian neoplasms. PP should be suspected in the right clinical setting. A confident diagnosis avoids unnecessary surgical resection, which has a recurrence risk of 30-50%.

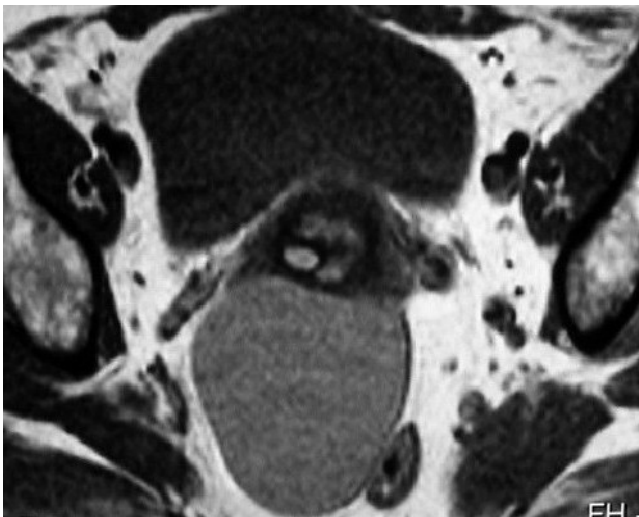
Preoperative diagnosis depends on the presence of a normal ipsilateral ovary and surrounding loculated fluid conforming to the shape of the peritoneal cavity. As opposed to cystic ovarian tumours, which are usually round or ovoid walled masses, PP have irregular shapes reflecting the invagination of surrounding structures into the collection in the absence of a true wall. These aspects are better depicted on MRI, owing to its high contrast resolution of soft tissues and multiplanar imaging capacities. On PP, nodular mesothelial tissue can be seen projecting into the lumen, in a classic cogwheel appearance. Adhesions may extend across the entire width of the fluid collection, forming complex multicystic adnexal masses adherent to the surface of the ovary but without involvement of the ovarian parenchyma. PP can have a slow growth as more fluid is secreted. Collections can assume a serous, gelatinous or haemorrhagic nature, with distinct signal intensities on MRI and different echogenicity on sonography. If needed, conservative treatment of PP is possible with oral contraceptives, analgesics or transvaginal or CT-guided fluid aspiration.

Final Diagnosis

Peritoneal pseudocysts - laparotomy confirmed serous fluid collections within adhesions. Pathological diagnosis: hyperplastic peritoneal reaction.

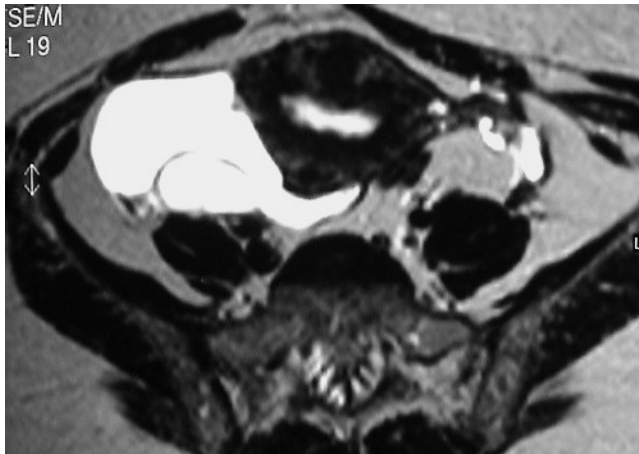
Figures

Figure 1 T1-weighted MR axial image of the pelvis

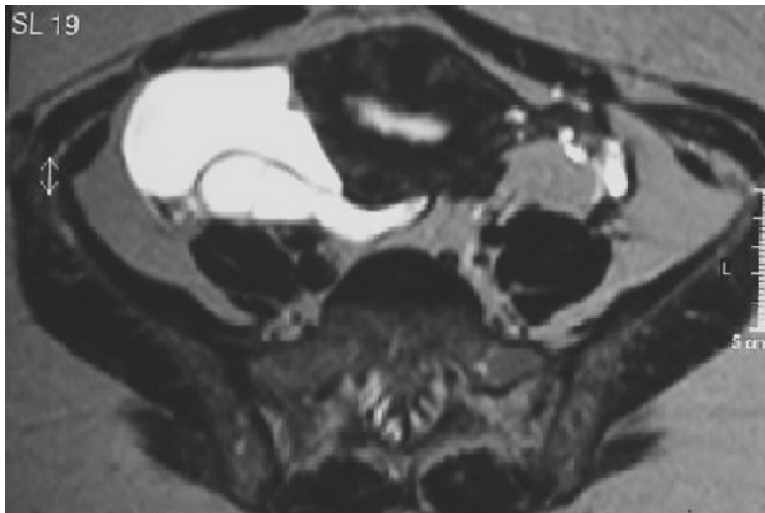


A homogeneous intermediate intensity signal mass, with perfectly regular contour, is seen causing anterior displacement of the uterine cervix and left lateroposterior displacement of the rectum.

Figure 2 T2-weighted MR axial images of the pelvis

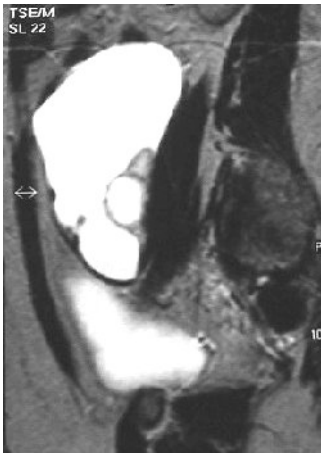

Right hyperintense cystic mass with thin internal septa, conforming to the uterine posterolateral wall (with a subserous posterior fibroid). The left ovary is also seen.

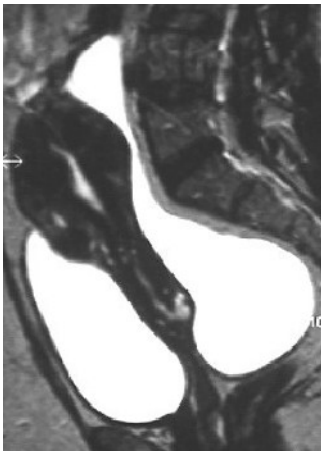


At an inferior level the right ovary is seen posteriorly compressed and slightly deformed by a cystic mass with high intensity signal equal to ovarian follicles.

Figure 3 T2-weighted MR sagittal image of the pelvis

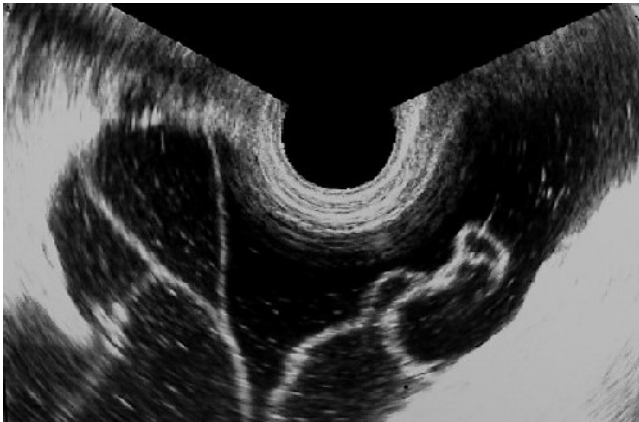


The right ovary is seen with a follicular cyst, slightly compressed by a cystic mass with high intensity signal, equal to the ovarian follicles.



The large, homogeneous mass with irregular shape, conforming to the posterior wall of the uterus without invasion, is highly suggestive of fluid collection in pouch of Douglas.

Figure 4 Transvaginal sonogram of the right pelvis



A cystic space-occupying lesion with thin internal septations and low echogenic content is seen.

References

- [1] Jain KA. Imaging of peritoneal inclusion cysts. Am J Roentgenol. 2000 Jun;174(6):1559-63.
- [2] Kurachi H, Murakami T, Nakamura H, Hori Shinichi, Miyake A, Kozuka T, Tanizawa O. Imaging of peritoneal pseudocysts: value of MR imaging compared with sonography and CT. Am J Roentgenol 1993 Sept;160(3):589-91.

[3] Kim JS, Lee HJ, Woo SK, Lee TS. Peritoneal inclusion cysts and their relationship to the ovaries: evaluation with sonography. Radiology 1997 Aug;204(2):481-4.

[4] Hoffer FA, Kozakewich H, Colodny A, Goldstein DP. Peritoneal inclusion cysts: ovarian fluid in peritoneal adhesions. Radiology 1988 Oct;169(1):189-91.

[5] Inman DS, Lambert AW, Wilkins DC. Multicystic peritoneal inclusion cyst: the use of CT guided drainage for symptom control. Ann R Coll Surg Engl 2000 May;82(3):196-7.

Citation

M. Monteiro, T. Cunha, I Duarte, I. Cabral (2002, Jan. 7)

Peritoneal pseudocysts {Online}

URL: <http://www.eurorad.org/case.php?id=1279>