



**Escola Superior  
de Tecnologia  
da Saúde**

Politécnico de Coimbra

Cristiana Sofia Antunes dos Santos

**DETECTING SEIZURE PATTERNS:  
A SYSTEMATIC REVIEW OF SIMULTANEOUS SCALP AND  
STEREO-ELECTROENCEPHALOGRAM (EEG)**

VOLUME 1

Dissertation submitted as part of the Master's in Clinical Physiology –  
Specialisation in Applied Electroencephalography, supervised by Professor  
Joana Isabel Rodrigues Soares and presented to the Coimbra Health School  
of the Polytechnic University of Coimbra

September 2024

# Acknowledgments

This journey, filled with challenges and discoveries, was not undertaken alone. Every step, every obstacle overcome, was made possible by the support and presence of special people who walked beside me, lighting the way and making the path lighter and more meaningful.

I extend my deepest gratitude to my advisors, whose patience, knowledge, and dedication guided me along this path. Your guidance was crucial for the development of this work, and I am eternally grateful for the lessons you taught and for the opportunity to learn from you.

To my family, who have been my unwavering foundation and have always believed in me, offering unconditional support and unquestionable love. Your encouragement was essential in helping me reach this point.

To my friends, who, even in the most difficult moments, provided words of affection, motivation, and encouragement. Your friendship made the journey easier and the achievements even more rewarding. You will always have a special place in my heart.

I must also acknowledge the teachers who, throughout my academic journey, contributed significantly to my education. Your classes and guidance were fundamental in bringing me to this moment.

This work reflects the countless hands, minds, and hearts that have supported me throughout this journey. We did it.

# Abstract

**Purpose:** To investigate methodologies for detecting seizure patterns using simultaneous scalp EEG (scEEG) and stereo-EEG (SEEG) recordings. By leveraging these advanced electroencephalographic techniques, we aim to address challenges in drug-resistant epilepsy management and ultimately improve the quality of life for affected individuals.

**Methods:** The study protocol was registered in PROSPERO and adhered to PRISMA guidelines. We conducted a comprehensive search across Scopus, PubMed, and Web of Science, focusing on studies in Portuguese or English, involving patients with drug-resistant epilepsy who underwent simultaneous scEEG and SEEG. Studies without data, systematic reviews, conference abstracts, case reports, and those featuring only scEEG and electrocorticography were excluded. The review systematically assessed seizure patterns detected in simultaneous scEEG and SEEG recordings.

**Results:** The search initially identified 9,750 studies, of which sixteen were potentially eligible after screening and were selected for full-text review. Of these sixteen, eight studies met the inclusion criteria and were included in the review, all retrospective observational, with half conducted in the US and half in Europe. These studies analysed 250 patients, focusing on several aspects of simultaneous scEEG and SEEG recordings, including seizure patterns and latency between detection methods.

**Conclusions:** This review highlights the potential of combining scEEG and SEEG to enhance seizure pattern analysis in drug-resistant epilepsy. The simultaneous use of both modalities offers complementary insights into seizure onset and propagation, improving the localization of epileptogenic zones. SEEG is effective in detecting deep brain patterns, while scEEG provides broad cortical data that guides SEEG placement. Despite these benefits, the limited number of studies and methodological inconsistencies pose challenges. Future research should standardize methods, increase sample sizes, and integrate other co-registration techniques to further improve diagnostic accuracy and surgical planning.

**Keywords:** electroencephalogram; stereo-EEG; scalp-EEG; epileptic discharges.

## Resumo

**Objetivo:** Investigar as metodologias para detetar padrões de crises epiléticas, utilizando registos simultâneos de EEG de escalpe (scEEG) e stereo-EEG (SEEG). Ao aplicar estas técnicas avançadas de eletroencefalografia, visamos abordar desafios na gestão da epilepsia farmacorresistente e, em última análise, melhorar a qualidade de vida dos indivíduos afetados.

**Métodos:** O protocolo do estudo foi registado no PROSPERO e seguiu as diretrizes PRISMA. Realizámos uma pesquisa abrangente nas bases de dados *Scopus*, *PubMed* e *Web of Science*, com foco em estudos em português ou inglês que envolvessem pacientes com epilepsia farmacorresistente que tenham realizado, simultaneamente, scEEG e SEEG. Foram excluídos estudos sem dados, revisões sistemáticas, resumos de conferências, relatos de caso(s) clínico(s) e todos os que apresentassem apenas scEEG e eletrocorticografia em simultâneo. A revisão avaliou sistematicamente os padrões de crises detetados em registos simultâneos de scEEG e SEEG.

**Resultados:** A pesquisa identificou inicialmente 9.750 estudos, dos quais dezasseis foram considerados potencialmente elegíveis, após a triagem, sendo selecionados para revisão do texto integral. Destes dezasseis, oito estudos cumpriram os critérios de inclusão e foram incluídos na revisão: todos observacionais retrospectivos, metade deles realizados nos Estados Unidos da América e metade na Europa. Estes estudos analisaram 250 pacientes, destacando vários aspetos dos registos simultâneos de scEEG e SEEG, incluindo padrões de crises e latência entre métodos de deteção.

**Conclusões:** Esta revisão destaca o potencial da combinação de scEEG e SEEG para melhorar a análise dos padrões de crise epilética na epilepsia farmacorresistente. A utilização simultânea de ambas as modalidades fornece informações complementares sobre o início e a propagação das crises, melhorando a localização das zonas epileptogénicas. O SEEG é eficaz na deteção de padrões ictais em zonas profundas do cérebro, enquanto o scEEG fornece dados corticais amplos que orientam a implantação do SEEG. Apesar destes benefícios, o número limitado de estudos e as inconsistências metodológicas representam

desafios. Futuras investigações devem padronizar métodos, aumentar o tamanho das amostras e integrar outras técnicas de correção para melhorar a precisão do diagnóstico e o planeamento cirúrgico.

**Palavras-Chave:** eletroencefalograma; stereo-EEG; EEG de escalpe; descargas epiléticas.

# Abbreviations

ASM – Antiseizure Medication

DRE - Drug-Resistant Epilepsy

EEG – Electroencephalography / Electroencephalogram

ESI – Electrical Source Imaging

EZ - Epileptogenic Zone

fMRI - Functional Magnetic Resonance Imaging

GRADE - Grading of Recommendations Assessment, Development, and Evaluation

ICA - Independent Component Analysis

ILAE – International League Against Epilepsy

IZ – Irritative Zone

MEG – Magnetoencephalography

MRI - Magnetic Resonance Imaging

PET - Positron Emission Tomography

PRISMA - Preferred Reporting Items for Systematic Reviews and Meta-Analyses

scEEG – Scalp Electroencephalography / Scalp Electroencephalogram

SEEG – Stereoelectroencephalography / Stereoelectroencephalogram

SOP - Seizure-Onset Patterns

SOZ – Seizure Onset Zone

SP – Seizure Patterns

SPECT - Single-Photon Emission Computed Tomography

s-PGES - Early Phase of Postictal Generalized EEG Suppression

TLE – Temporal Lobe Epilepsy

## Tables

**Table I:** Search strategy for each database.

**Table II:** Baseline characteristics of the studies included in the systematic review.

**Table III:** Characteristics of the electroencephalography recordings used in the studies included in the review.

# Figures

**Figure 1:** Flowchart illustrating the research and study selection process for the systematic review in accordance with PRISMA guidelines.

# Table of Contents

Introduction .....	1
Methods.....	7
Review Questions .....	7
Data Sources .....	7
Search Strategy .....	8
Inclusion and Exclusion Criteria .....	9
Study Selection and Data Extraction .....	9
Quality Assessment .....	9
Results.....	11
Study Selection .....	11
(I) Quality Assessment .....	14
(II) Baseline Characteristics .....	14
(III) Methodological Specifications.....	16
(IV) Electroencephalogram Patterns .....	16
(V) Latency between seizure onsets.....	17
(VI) Treatment details.....	17
Discussion .....	19
The Value of Integrating Scalp and Stereo-EEG Recordings .....	19
Electroencephalographic Patterns in scalp EEG and in Stereo-EEG .....	20
The Complementary Role of SEEG in scEEG Analysis .....	22
The Complementary Role of scEEG in Guiding SEEG Explorations.....	23
Alternative Co-Registration Techniques .....	24

Methodical Considerations and Limitations .....	25
Conclusions and Future Directions .....	27
References .....	29

# Introduction

Epilepsy is a complex neurological disorder that affects millions of people worldwide, characterized by recurrent, unprovoked seizures caused by abnormal and unpredictable electrical activity in the brain (Fisher et al., 2014; Hirtz et al., 2007). These seizures can lead to a range of physical and cognitive manifestations, which have profound effects on patients' quality of life, social interactions, and mental health (Fisher et al., 2014). The World Health Organization estimates that approximately 50 million people worldwide are affected by epilepsy, making it one of the most common neurological conditions (World Health Organization, 2019).

Despite the availability of several treatments, including antiseizure medications (ASMs) and surgical interventions, controlling seizures remains a significant challenge for many patients. Approximately one-third of individuals with epilepsy do not achieve satisfactory seizure control, even after trying two or more ASMs at optimal doses (Picot et al., 2008). The International League Against Epilepsy (ILAE) defines drug-resistant epilepsy (DRE) as the failure of adequate trials of two well-tolerated and appropriately chosen ASMs, whether used as monotherapy or in combination, to achieve sustained seizure freedom (Kwan et al., 2010).

DRE is a particular challenging subset of epilepsy that requires a detailed understanding of seizure dynamics and patterns to improve treatment outcomes and to facilitate the development of targeted therapies. Traditional diagnostic methods, while providing valuable information, often lack the specificity required to discern the nuanced onset patterns of seizures (Grech et al., 2008). This gap in knowledge has driven the pursuit of advanced techniques for seizure detection and characterization.

Electroencephalography (EEG) has long been the standard method for monitoring brain activity and identifying seizure events (Grech et al., 2008). This pivotal role in neuroscience can be traced back to 1924, when Hans Berger made the first EEG recording on the human scalp (Niedermeyer & Lopes da Silva, 1993). By using simple radio equipment to amplify the brain's electrical signals, Berger created a paper record

of these signals and showed that EEG could reliably reflect different states of brain activity, such as transitions from relaxation to alertness, sleep, or oxygen deprivation (Niedermeyer & Lopes da Silva, 1993). This groundbreaking work established the foundation for the ongoing research and the broad range of EEG applications we use today.

EEG is a non-invasive technique that records electrical activity from the scalp using metal electrodes and conductive media. It offers several advantages, such as high temporal resolution, allowing for precise tracking of rapid changes in brain activity, and the ability to detect abnormal electrical patterns associated with seizures and various neurological disorders. Additionally, EEG is relatively cost-effective compared to other imaging modalities (Grech et al., 2008).

However, EEG has certain limitations. Its spatial resolution is relatively poor compared to imaging techniques like magnetic resonance imaging (MRI) or computed tomography scans, which can result in less precise localization of brain activity sources. Moreover, EEG recordings are susceptible to external noise and artifacts, which can complicate result interpretation. Furthermore, due to the brain's layered structure and the placement of electrodes, EEG may not always detect subtle or deep brain activity, limiting its diagnostic utility for certain neurological conditions (Grech et al., 2008).

To minimise the impact of EEG limitations, several methods have been developed, including Electrical Source Imaging (ESI), High-Resolution EEG, and High-Density EEG. These techniques enhance both spatial and temporal resolution, allowing for more precise localisation of brain activity. ESI uses advanced algorithms to estimate the source of electrical signals in the brain (Zorzos et al., 2021); High-Resolution EEG improves the signal-to-noise ratio, revealing finer cortical details (Michel, 2019); and High-Density EEG employs a larger array of electrodes, increasing spatial sampling and thus providing a more detailed map of brain activity across the scalp (Lantz et al., 2003). These techniques represent significant advancements in neurophysiology, contributing to a better understanding of neural dynamics and enhancing clinical assessments.

In cases of drug-resistant focal epilepsy, where ongoing use of ASMs fails to improve quality of life or reduce seizure frequency, surgery becomes a crucial treatment

option. The main goal of epilepsy surgery is to remove the epileptogenic zone (EZ)—the area identified as the source of epileptic activity—while preserving non-epileptic tissue and areas with essential neuropsychological and neurological functions to achieve seizure freedom (Jehi, 2018; Rosenow, 2001).

Throughout this process, several crucial regions beyond the EZ are meticulously evaluated: i) the Irritative Zone (IZ), which is the cortical area responsible for generating interictal spikes; ii) the Seizure-Onset Zone (SOZ), where clinical seizures initially occur; iii) the Symptomatogenic Zone, which, when activated, produces the initial ictal symptoms or signs; iv) the Epileptogenic Lesion, a macroscopic lesion that either directly causes seizures (e.g., cortical dysplasia) or induces secondary hyperexcitability in the surrounding cortex; v) the Functional Deficit Zone, the area of the cortex exhibiting abnormal function during the interictal period. By carefully assessing and addressing these zones, the goal is to achieve seizure freedom while minimizing impact on essential brain functions. This approach requires a thorough presurgical evaluation, typically beginning with non-invasive methods (Jehi, 2018; Rosenow, 2001).

The non-invasive evaluation usually includes MRI, video-EEG, and neuropsychological assessment (Rosenow, 2001). Other non-invasive methods, such as positron emission tomography (PET), single-photon emission computed tomography (SPECT), magnetoencephalography (MEG), Wada tests, and functional magnetic resonance imaging (fMRI), are often used but do not directly measure seizure activity or accurately distinguish seizures (Rosenow, 2001). In many cases, intracranial or intracerebral investigations using electrocorticography or stereo-EEG are required to precisely locate and delineate the area to be operated on and to map functional regions of the brain (Rosenow, 2001).

Electrocorticography involves implanting subdural grids or strip electrodes on the surface of the cerebral cortex, whereas SEEG involves the stereotaxic implantation of deep electrodes directly into deep brain structures. SEEG plays a particularly important role in epilepsy surgery because it detects signals from deeper brain structures, providing enhanced spatial accuracy in identifying the SOZ. This improved accuracy aids in detecting subtle seizure dynamics and onset patterns, leading to a more comprehensive

understanding of individual seizure characteristics (Bartolomei et al., 2018; Khoo et al., 2020).

In recent years, the integration of simultaneous scalp EEG and stereo-EEG has emerged as a promising approach to improve seizure detection (Abramovici et al., 2018; Altenmüller et al., 2016; Antony et al., 2019; Barborica et al., 2021; Casale et al., 2022; Ferrand et al., 2023; Iachim et al., 2021; Vossler et al., 2017). By combining the strengths of both modalities, researchers are paving the way for more accurate and reliable identification of SOZ. Scalp EEG offers a broad overview of brain activity, while stereo-EEG provides detailed insights from electrodes placed directly within the brain, enabling clearer delineation of seizure *foci* and more precise localization of deep epileptic activity.

The first clinical use of combined scalp, subdural, and depth recordings was conducted by Abraham and Marsan in 1958, focusing on patients with temporal lobe epilepsy (Abraham & Ajmone Marsan, 1958). Their work revealed that the amplitude of cortical spikes influences their detection by scalp EEG electrodes, at least to some extent. They suggested that it is the size of the activated cortical area, rather than the shape or duration of the cortical discharge, that affects the presence and amplitude of the corresponding signals recorded by scalp EEG.

Simultaneous recording with scalp and intracranial electrodes is not a routine practice. However, there has been increasing interest in the seizure patterns (SP) observed through scalp EEG and SEEG over recent decades. Despite this growing interest, the relationship between these two SP has been investigated in only a limited number of studies (Ebersole & Pacia, 1996; Ferrand et al., 2023; Lieb et al., 1976; Pacia & Ebersole, 1997; Tanaka et al., 2018). An investigation focused on patients with MRI-visible lesions found that seizure-onset patterns (SOP) detected on scalp EEG can offer valuable insights into the SEEG SOP, the underlying lesion, and the depth of the EZ location (Tanaka et al., 2018).

The simultaneous use of scalp and stereo-EEG recordings not only improves the precise characterization of seizure types but also enhances our understanding of

individual seizure dynamics. In this study, we aim to explore the methodologies used to detect SPs with this combined approach and how it advances our comprehension of epilepsy's pathophysiology. Additionally, we will discuss the potential implications for clinical practice, including enhanced surgical planning and improved patient outcomes. Understanding seizure onset through these advanced EEG techniques is crucial for addressing the challenges of epilepsy management and ultimately improve the quality of life for those affected by the condition.



# Methods

The study protocol was registered with the international prospective register of systematic reviews (PROSPERO number CRD42024590432) and adhered to the Preferred Reporting Items for Systematic Reviews and Meta-analyses (PRISMA) guidelines (Moher et al., 2009; Page et al., 2021; PRISMA-P Group et al., 2015). The systematic review followed the Cochrane Handbook for Systematic Reviews of Interventions (Higgins et al., 2023). Ethical committee approval was not required for this work, as it constitutes a systematic review without patient involvement.

## Review Questions

The aims of this review were to: i) assess the correlation between seizure onset patterns observed in simultaneously recorded scalp EEG and stereo-EEG; ii) compare the seizure detection latency between scalp EEG and concurrent stereo-EEG; iii) evaluate the effectiveness of recording both scalp EEG and stereo-EEG simultaneously; and iv) identify consistent electroencephalographic patterns in scalp EEG and examine their intracerebral correlates. We structured our question using the Participants, Intervention, Comparison, Outcome (PICO) framework as follows: “Does simultaneous recording of scalp EEG and stereo-EEG enhance the determination of seizure patterns?”

In this context, we defined: P as patients with drug-resistant epilepsy [as per ILAE criteria (Kwan et al., 2010)] who underwent simultaneous scalp and stereo-EEG; I as the simultaneous recording of both scalp and stereo-EEG; C as the comparison between patterns observed in scalp EEG and those in stereo-EEG; and O as the improved correlation and detection of seizure patterns.

## Data Sources

A comprehensive search was carried out across multiple electronic databases, including Scopus, PubMed/MEDLINE, and Web of Science. The search covered studies from their inception to the submission date, with the primary objective of identifying published research on stereotaxic electroencephalography and simultaneous scalp electroencephalography in drug-resistant epilepsy.

## Search Strategy

Two reviewers (CS and JIS) collaborated to develop a highly sensitive search strategy for gathering eligible literature. To balance machine-assisted screening with a human-driven systematic evidence review, we implemented a comprehensive approach involving blind assessments and a structured conflict resolution process. During the initial collection and review phase, Rayyan.ai (Ouzzani et al., 2016) was employed for efficient article screening, utilising machine learning to prioritise results. Conflicting assessments were resolved using Rayyan’s conflict resolution feature, followed by a collaborative discussion between both reviewers. Consensus criteria were established during these discussions.

The keywords used in the search included variations of 'stereotaxic' or 'invasive' and 'EEG', combined with terms related to seizures or ictal patterns. Further details, including the breakdown of keywords used in each database and the resulting hit counts, are presented in Table I. The primary focus was on extracting data related to stereotaxic EEG and scalp EEG in connection with seizures or electroencephalographic patterns. The database search was also complemented with a manual search of the reference lists of selected articles.

**Table I:** Search strategy for each database.

Database	Search expression	Hit count
Pubmed®	((“Stereotaxic Techniques” [Mesh] OR stereotaxic OR stereotactic OR stereo* OR stereoelectroencephalogr* OR invasive OR deep*) AND (“Electroencephalography” [Mesh] OR EEG OR electroencephalogr*) AND (“Seizures” [Mesh] OR seizure* OR convulsi* OR ictal))	4735
Scopus	(‘stereotaxic techniques’ OR stereotaxic OR stereotactic OR stereo* OR stereoelectroencephalogr* OR invasive OR deep*) AND (‘electroencephalography’ OR EEG OR electroencephalogr*) AND (‘seizures’ OR seizure* OR convulsi* OR ictal)	764
Web of Science™	(“stereotaxic techniques” OR stereotaxic OR stereotactic OR stereo* OR stereoelectroencephalogr* OR invasive OR deep*) AND (“electroencephalography” OR EEG OR electroencephalogr*) AND (“seizures” OR seizure* OR convulsi* OR ictal)	4251

## **Inclusion and Exclusion Criteria**

We included studies in Portuguese or English that involved patients with drug-resistant epilepsy who underwent simultaneous scalp EEG and stereo-EEG, regardless of the year of publication. Studies without available data, as well as review articles (due to the lack of primary data), conference abstracts, case reports, short communications, and studies involving only simultaneous scalp-EEG and electrocorticography (grids and strips, without depth electrodes), were excluded.

## **Study Selection and Data Extraction**

Initially, two reviewers (CS and JIS) screened the titles and abstracts of all studies identified by the search strategy. Papers were deemed eligible if they met the inclusion criteria at this stage. Articles that mentioned only intracranial EEG or scalp EEG in isolation (not simultaneously) were excluded. After the initial screening, the eligible studies proceeded to full-text review, which was conducted independently by both reviewers (CS and JIS). Disagreements were resolved through consensus. For each eligible article, we extracted key details such as the title, first author, publication year, country, cohort size, gender distribution, age, presurgical evaluation, epilepsy topography, and the types of intracranial EEG and scalp EEG recordings used (e.g., SEEG, combinations of grids/strips and depth electrodes, and scalp electrode positions).

## **Quality Assessment**

The quality of the studies included in this review was evaluated using the Grading of Recommendations Assessment, Development, and Evaluation (GRADE) system (Shao et al., 2023). This system provides a framework for rating the quality of evidence based on factors such as study design, risk of bias, inconsistency, indirectness, and imprecision. We used a quality score scale ranging from 1 to 5, with higher values indicating better quality. This rigorous approach ensures a comprehensive evaluation of the quality and reliability of the evidence, allowing us to draw conclusions based on the most robust and credible information available.



# Results

## Study Selection

The database search initially identified 9,750 studies. After removing 3,579 duplicates through both automated and manual methods, 6,171 articles remained for title and abstract screening. Of these, 6,155 were excluded for not meeting the eligibility criteria. The main reasons for exclusion at this stage involved studies that were irrelevant to the review's purpose, animal studies, those focused on paediatric populations, study designs such as review articles and case reports, and publications in languages other than Portuguese or English. Sixteen articles were considered potentially eligible and underwent full-text review. Among these, two were case reports, one lacked sufficient methodological detail, and five did not involve simultaneous scEEG and SEEG. Consequently, eight studies were included in the systematic review (Abramovici et al., 2018; Altenmüller et al., 2016; Antony et al., 2019; Barborica et al., 2021; Casale et al., 2022; Ferrand et al., 2023; Iachim et al., 2021; Vossler et al., 2017).

Figure 1 illustrates the article selection process, following PRISMA guidelines (Moher et al., 2009; Page et al., 2021; PRISMA-P Group et al., 2015). All eight included studies were retrospective observational studies, with half conducted in the United States and the other half in Europe.

The data from the included studies were categorised into six parts: (I) Quality Assessment, (II) Baseline Characteristics, (III) Methodological Specifications, (IV) Electroencephalogram Patterns, (V) Latency between Seizure Onsets and (VI) Treatment Details. The following sections provide a detailed discussion of the included studies within the context of these six categories. The characteristics and results of the included studies are presented in Tables II and III.

**Table II:** Baseline characteristics of the studies included in the review.

Authors	Year	Country	Design	Quality	Patients included (n)	Male [n (%)]	Age (years) (mean±SD)	Age at seizure onset (years) (mean±SD)	EEG recording	Temporal Lobe Epilepsy* [n (%)]	Pré-Surgical Non-Invasive Evaluation						
											MRI	Video-EEG	PET	Neuropsychological evaluation	SPECT	MEG	Wada Test
Iachim, E. et al.	2021	Belgium	Observational Retrospective	4	30	16 (53,3)	30,5±14,6	13,9±12,1	Interictal	19 (63)	Yes, 3T	ND	Yes	Yes	No	No	No
Barborica, A. et al.	2021	Romania	Observational Retrospective	4	8	5 (62,5)	30,9±10,1	20±14	Ictal	2 (25)	Yes	Yes	Yes	Yes	No	No	No
Abramovici, S. et al.	2018	Pennsylvania, USA	Observational Retrospective	3	13	4 (30,8)	ND	27,5±15,2	Ictal	7 (77,8) (Group I)	Yes	Yes	Yes	Yes	Yes	Yes	No
Ferrand, M. et al.	2023	France	Observational Retrospective	5	129	76 (58,9)	30,1±10,3	12,5±9,7	Ictal	72 (55,8)	Yes	Yes	Yes	Yes	No	No	No
Altenmüller, D. et al.	2016	Germany	Observational Retrospective	3	15	9 (60)	30,1±15,4	12,7±13,3	Postictal	9 (60)	Yes, 3T	Yes	No	Yes	No	No	No
Antony, A. et al.	2019	Pennsylvania, USA	Observational Retrospective	3	9	2 (22,2)	37,2±12,1	14±12,6	Ictal	9 (100)	Yes	Yes	Yes	Yes	Yes	Yes	No
Vossler, D. et al.	2017	Seattle, USA	Observational Retrospective	2	19	ND	ND	ND	Ictal	19 (100)	Yes	Yes	Yes	Yes	Yes	No	Yes
Casale, M. et al.	2022	New York, USA	Observational Retrospective	5	27	9 (33,3)	38,2±6,8	ND	Ictal	ND	Yes	Yes	Yes	Yes	No	No	Yes

\* Both temporal and extratemporal *foci* are considered extratemporal lobe epilepsy.

ND – Not-Described.

**Table III:** Characteristics of the electroencephalography recordings used in the studies included in the review.

Authors	Type of intracranial EEG	Deep electrodes (n)	Contacts of deep electrodes (n)	Scalp electrodes	Duration of simultaneous recordings (days) (n)	SEEG Patterns	scEEG Patterns	Latency between the seizure onsets	Epilepsy Surgery [n (%)]
Iachim, E. et al.	SEEG electrodes + Subdural grid or strip electrodes	5,3±1,6	22,6±10,6	10-20 IS (+6 additional electrodes in some cases)	6±2,8	"Pure" insular spikes or "diffusing" insular spikes. "Synchronous" or diffusing from other contacts to insula.	ND	NA	16 (53)
Barborica, A. et al.	SEEG electrodes	14,5±1,41	173,8±26,3	30,8±6,1	7 to 14	ND	ND	ND	ND
Abramovici, S. et al.	Subdural grids or SEEG electrodes	4 to 12	4 to 16	10-20 IS	6 to 14	ND	ND	17,5±16,1	7 (53,9)
Ferrand, M. et al.	SEEG electrodes	13,2±2,4	ND	24,7±1,9	ND	Short intracerebral seizures; Rather prolonged intracerebral seizures, with high-frequency discharges; Prolonged intracerebral seizures, characterized by slow rhythmic or fast low-voltage discharges; Intermediate duration intracerebral seizures characterized by high-frequency discharges; Prolonged duration intracerebral seizures characterized by high-frequency discharges; Intermediate duration intracerebral seizures characterized by high-frequency discharges.	"Normal EEG"; "Blurred EEG"; "Temporal discharge"; "Posterior discharge"; "Diffuse suppression"; "Frontal discharge".	ND	91 (70,5)
Altenmüller, D. et al.	SEEG electrodes or Subdural + SEEG electrodes or only subdural electrodes	2,3±1,1	67,3±60,9	10-20 IS	ND	Continuous local interictal activity; Suppressed EEG activity at all intracranial contacts in the early phase of s-PGES, but reemerging local brain activity before s-PGES dissolved; Persistent local ictal activity during s-PGES	Apparent Postictal generalized suppression	NA	12 (80)
Antony, A. et al.	SEEG electrodes + Subdural grids	6,9±2,7	6 to 12	21	9±3,2	ND	ND	11,4±9,5	9 (100)
Vossler, D. et al.	SEEG electrodes + Subdural strips	ND	ND	4 to 14 electrodes from 10-20 IS	ND	Decremental pattern; Beta or gamma frequency; Alpha frequency; Theta frequency; Delta frequency; Spikes; Spike train.	Rhythmic waves; Alpha frequency; Theta frequency; Delta frequency.	0 to 63	NA
Casale, M. et al.	SEEG electrodes	ND	6 to 14	19	ND	No modification; Diffuse slow activity; Focal polymorphic slow activity; Focal slow activity with mixed epileptiform potentials; Generalized spikes.	No modification.	17,3	ND

EEG – Electroencephalogram; IS – International System; NA - Non-Applicable; ND – Not-Described; scEEG – Scalp Electroencephalogram; SEEG – Stereo-electroencephalogram; s-PGES - apparent postictal generalized EEG suppression on scalp-EEG.

## **(I) Quality Assessment**

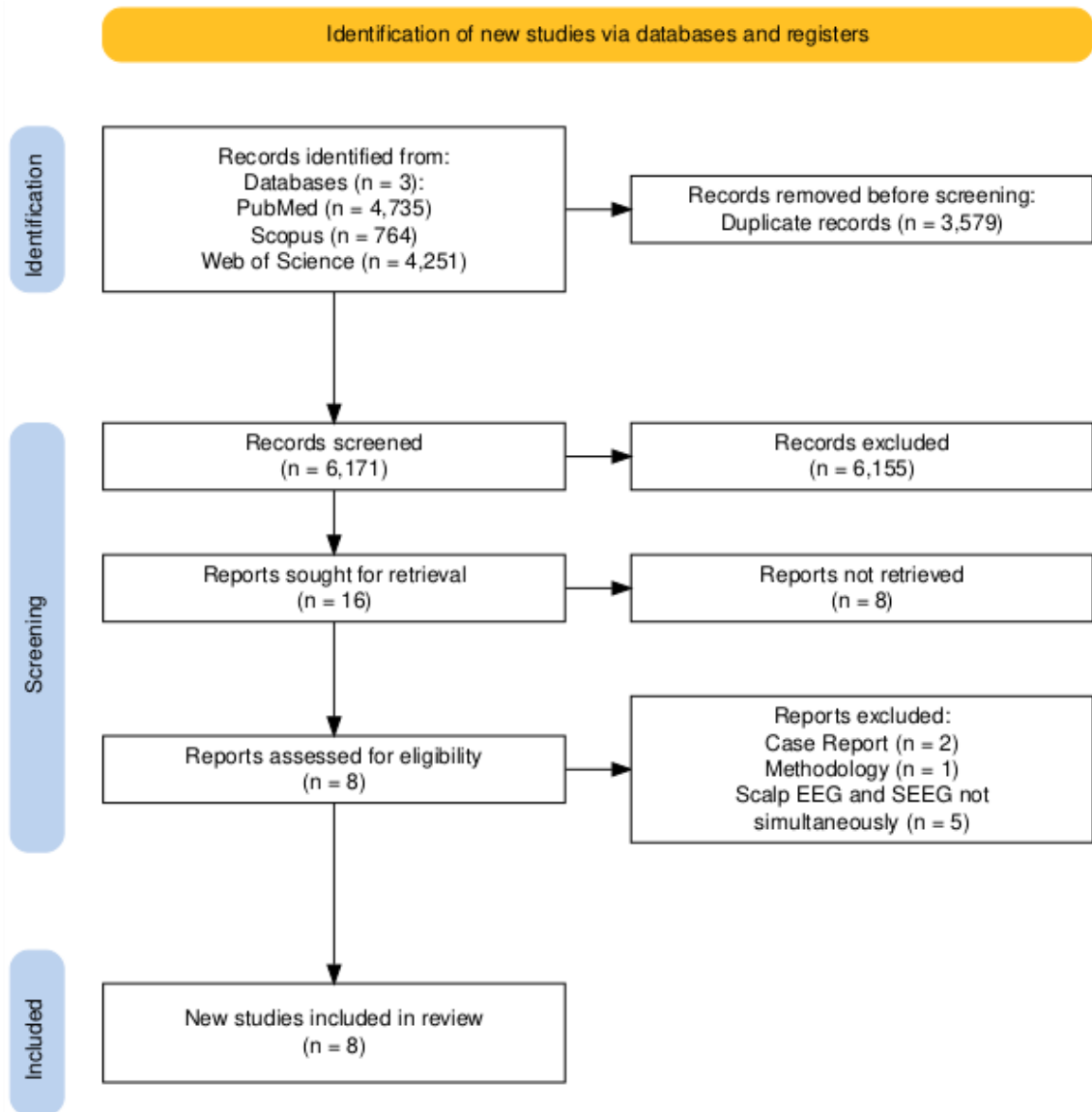
Using the GRADE system (Shao et al., 2023), we assessed the certainty of evidence of study outcomes on a quality score scale from 1 to 5, with higher values indicating better quality. Of the included studies, two (Casale et al., 2022; Ferrand et al., 2023) achieved a score of 5, representing 25% of the studies. Two studies (Barborica et al., 2021; Iachim et al., 2021) were rated with a score of 4, also accounting for 25%. Three studies (Abramovici et al., 2018; Altenmüller et al., 2016; Antony et al., 2019) received a score of 3, which corresponds to 37.5% of the studies. Finally, one study (Vossler et al., 2017) obtained a score of 2, making up 12.5% of the studies.

## **(II) Baseline Characteristics**

The eight studies included in this review were published between 2016 and 2023, analysing a total of 250 patients. The sample size varied across studies, ranging from 8 to 129 patients. In seven of the studies, the proportion of male participants ranged from 22,2% to 62,5%.

In six of the eight studies, the mean age of patients was between 30 and 38 years, while the age of seizure onset ranged from 12 to 27 years. All studies employed simultaneous scEEG and SEEG recordings, with six focusing on the ictal phase (Abramovici et al., 2018; Antony et al., 2019; Barborica et al., 2021; Casale et al., 2022; Ferrand et al., 2023; Vossler et al., 2017), one on the interictal phase (Iachim et al., 2021), and one on the postictal phase (Altenmüller et al., 2016).

Two studies specifically focused on Temporal Lobe Epilepsy (TLE) (Antony et al., 2019; Vossler et al., 2017), while four studies did not centre on TLE, but had more than half of their samples diagnosed with TLE (Abramovici et al., 2018; Altenmüller et al., 2016; Ferrand et al., 2023; Iachim et al., 2021). One study (Barborica et al., 2021) reported a predominance of extratemporal lobe epilepsy, accounting for 75% of its sample, while another study did not provide detailed information on epilepsy topography (Casale et al., 2022).



**Figure 1:** Flowchart illustrating the research and study selection process for the systematic review in accordance with PRISMA guidelines.

All studies included a thorough presurgical, non-invasive evaluation. MRI and neuropsychological assessments were conducted in every study, while video-EEG was included in seven [one study did not provide this information (Iachim et al., 2021)]. PET scans were performed in all but one study (Altenmüller et al., 2016). Additionally, three studies included SPECT (Abramovici et al., 2018; Antony et al., 2019; Vossler et al., 2017), and two incorporated supplementary methods such as MEG (Abramovici et al., 2018; Antony et al., 2019) and Wada tests (Casale et al., 2022; Vossler et al., 2017) to aid in the diagnostic and surgical planning process.

### **(III) Methodological Specifications**

Three of the eight studies included in this review exclusively employed deep electrodes (SEEG) (Barborica et al., 2021; Casale et al., 2022; Ferrand et al., 2023), while the remaining five used a combination of deep electrodes with subdural grids and/or subdural strips.

Six studies documented the number of deep electrodes used, which ranged from 2 to 14 per patient, with a total of 4 to 173 contacts. Scalp electrodes were consistently applied across studies using the standard 10-20 electrode montage, in accordance with the international 10-20 system. However, one study utilised only a subset of electrodes placed according to this system, rather than the full montage (Vossler et al., 2017). The duration of simultaneous scalp and stereo-EEG monitoring, reported in half of the included studies, ranged from 6 to 14 days, depending on the study and individual patient needs (Abramovici et al., 2018; Antony et al., 2019; Barborica et al., 2021; Iachim et al., 2021).

### **(IV) Electroencephalogram Patterns**

Five studies described SEEG patterns, with one focusing on the insula (Iachim et al., 2021), which identified pure or diffusing insular spikes, some showing synchrony or diffusion from other contacts to the insula. Other patterns were typically characterised by short or prolonged intracerebral seizures with high-frequency discharges, slow rhythmic discharges, or fast low-voltage discharges (Ferrand et al., 2023). Intermediate duration intracerebral seizures were marked by high-frequency discharges, while prolonged seizures showed either slow rhythmic or high-frequency discharges (Ferrand et al., 2023).

In the study focusing on the postictal phase of seizures (Altenmüller et al., 2016), continuous local interictal activity was noted, with suppressed EEG activity at all intracranial contacts during the early phase of postictal generalized EEG suppression seen on sEEG, followed by reemerging local brain activity before the suppression resolved. Persistent local ictal activity was also recorded during this period. Additional

patterns observed included decremental activity, beta or gamma frequencies, alpha frequencies, theta frequencies, delta frequencies, spikes, and spike trains (Vossler et al., 2017).

Another study identified SEEG patterns such as no modification, diffuse slow activity, focal polymorphic slow activity, focal slow activity with mixed epileptiform potentials, and generalized spikes, which correlated with unaltered scEEG (Casale et al., 2022).

Scalp EEG patterns, detailed in three of the eight included studies, were generally less specific. They were described as “Normal EEG” or unaltered EEG (based on the interictal pattern), “Blurred EEG,” “Temporal discharge,” “Posterior discharge,” “Diffuse suppression,” or “Frontal discharge” (Casale et al., 2022; Ferrand et al., 2023), as well as rhythmic waves, and frequencies such as alpha, theta, and delta (Vossler et al., 2017). In the study focusing on the postictal phase of seizures (Altenmüller et al., 2016), scalp EEG consistently showed apparent postictal generalized suppression, aligning with the study's objective.

#### **(V) Latency between seizure onsets**

Half of the included studies (Abramovici et al., 2018; Antony et al., 2019; Casale et al., 2022; Vossler et al., 2017) provided data on the average latency between seizure onset detected by scEEG and SEEG, illustrating the differences in timing and detection capabilities between the two EEG modalities. In all four studies, SEEG detected the seizure onset before scEEG, with latency ranging from 0 to 63 seconds.

#### **(VI) Treatment details**

Epilepsy surgery was performed in 53-100% of patients across five of the eight included studies (Abramovici et al., 2018; Altenmüller et al., 2016; Antony et al., 2019; Ferrand et al., 2023; Iachim et al., 2021).



## Discussion

Seizure patterns have been extensively studied, yet they are often analysed separately in intracerebral and scalp EEG, leaving critical aspects of seizure onset and propagation in DRE insufficiently understood. Although recent advances have aimed to improve seizure detection methodologies, significant gaps persist. This systematic review addresses these gaps by exploring the integration of simultaneous scEEG and SEEG recordings. This combined approach not only bridges clinical practice with advanced neurodiagnostic technology but also enhances the understanding and detection of complex seizure patterns.

In our systematic review of the published literature, we analysed scEEG and SEEG patterns recorded simultaneously during the ictal period, as well as during the interictal and postictal phases, in a cohort of 250 patients with DRE. We expected to be able to establish a link between electroencephalographic patterns observed in scEEG and those observed in SEEG, however, this objective was hampered by the lack of studies that use these modalities simultaneously.

### **The Value of Integrating Scalp and Stereo-EEG Recordings**

Simultaneous scEEG and SEEG recordings provide a more detailed understanding of both superficial and deep brain activities by capturing electrical signals across different layers of the brain. While scEEG monitors the cortical surface, offering a broad overview of brain activity, SEEG provides high-resolution data from deeper brain structures, such as the hippocampus and insula (Iachim et al., 2021; Vossler et al., 2017). This combination enables a comprehensive mapping of seizure onset and propagation, facilitating a more accurate localization of the epileptogenic zones and offering valuable insights into the complex interactions between cortical and subcortical regions during seizures (Abramovici et al., 2018; Altenmüller et al., 2016; Antony et al., 2019; Barborica et al., 2021; Casale et al., 2022; Ferrand et al., 2023; Iachim et al., 2021; Vossler et al., 2017).

A careful analysis of simultaneous scEEG and SEEG can effectively guide surgical decision-making, as studied by Abramovici et al. (2018). They examined three key features within the first seconds of seizure onset in both scEEG and SEEG: latency between seizure onset on both modalities, anatomical congruence between the scEEG and SEEG during the onset and spread of the seizure, and concordance of EEG patterns in scEEG and SEEG during seizure onset and spread. Their findings indicated that a lack of congruence in these EEG features could predict surgical outcomes. Specifically, patients with at least one of the three features showing a discrepancy were more likely to experience seizure recurrence after surgery (Abramovici et al., 2018).

### **Electroencephalographic Patterns in scalp EEG and in Stereo-EEG**

SEEG is instrumental in identifying specific interictal patterns, as well as the onset and propagation of ictal activity within deep brain structures. Iachim et al. (2021) focused on interictal epileptiform discharges originating from the insula, a region often challenging to detect with scEEG alone, due to its deep location and unique gyral organization. These discharges may only become apparent on scEEG when they spread to the adjacent neocortex. In their study, they examined the prevalence of 'pure' or 'diffusing' insular spikes, which, although not directly correlating with scEEG patterns, highlighted SEEG's capability to pinpoint seizure activity in deep regions like the insula (Iachim et al., 2021).

Ferrand et al. (2023) aimed to define homogeneous ictal scalp EEG profiles based on their initial ictal abnormalities and assess their localizing value using simultaneous scEEG and SEEG recordings. They identified several distinct scEEG patterns and correlated them with intracerebral localization of ictal activity, recorded by SEEG electrodes:

1. **Temporal Discharge Profile:** Characterized by theta or delta discharges on ipsilateral anterior temporal scalp electrodes, this profile indicated a preferential localization of seizures in the mesial temporal region. It showed a significant occurrence and a strong statistical correlation with prolonged intracerebral seizures.

2. Posterior Discharge Profile: Defined by posterior ipsilateral or contralateral rhythmic alpha discharges or slow waves, this profile was the most frequent scEEG correlate of occipital and parietal seizures, although it also suggested a preferential temporal localization.
3. Diffuse Suppression Profile: Characterized by bilateral and diffuse suppression of background activity on the scEEG, this profile was associated with mesial and particularly insulo-opercular seizure localizations, indicating more generalized seizure activity.
4. Frontal Discharge Profile: Identified by bilateral frontal rhythmic fast activity or preictal spikes, this profile corresponded to preferential ventrodorsal frontal intracerebral localizations, underscoring the importance of frontal lobe activity in seizure onset.
5. Normal and Blurred EEG Profiles: The 'normal EEG' profile, associated with short intracerebral seizures, did not show a specific localization at seizure onset. The 'blurred EEG' profile, marked by early muscle artifacts, also corresponded to no specific intracerebral localization, suggesting these patterns may offer limited information for precise localization.

This authors (Ferrand et al., 2023) also conducted a hierarchical cluster analysis, which identified six distinct profiles based on the initial abnormality in scEEG. Importantly, none of these profiles were associated with a specific intracerebral localization, underscoring the complexity of interpreting scEEG data for seizure localization. This highlights the advantage of combining scEEG with SEEG to achieve a more accurate assessment.

Other researchers (Casale et al., 2022) identified patterns using SEEG that were not detected with scEEG, including diffuse slow activity, focal polymorphic slow activity, focal slow activity with mixed epileptiform potentials, and generalized spikes. Vossler et al. (2017) found ictal SEEG patterns in patients with TLE such as decremental patterns, frequency-specific changes (beta, gamma, alpha, theta, delta), spikes, and spike trains. In contrast, scEEG only recorded rhythmic waves or alpha, theta, and delta frequencies. Although Vossler et al. did not directly compare these patterns, they emphasised SEEG's

capacity to capture a range of frequency-specific changes, which enhances the understanding of intracerebral seizure dynamics (Vossler et al., 2017).

During the postictal phase, SEEG is also very sensitive to subtle local epileptiform patterns that scEEG might overlook, particularly when scEEG displays apparent postictal generalized suppression. Altenmüller et al. (2016) demonstrated that SEEG detected continuous local interictal activity, whereas scEEG showed suppressed activity during the early phase of postictal generalized EEG suppression (s-PGES). Additionally, SEEG revealed the reemergence of local brain activity before the resolution of s-PGES, as well as persistent local ictal activity throughout s-PGES (Altenmüller et al., 2016).

### **The Complementary Role of SEEG in scEEG Analysis**

While scEEG captures broader cortical activity, SEEG provides intricate data from deep brain structures, revealing patterns that scEEG may overlook. For example, the detection of pure or diffusing insular spikes by SEEG emphasizes its role in identifying seizure onset in deep regions that scEEG might miss (Iachim et al., 2021). Additionally, SEEG's sensitivity to local interictal activity during the postictal phase (Altenmüller et al., 2016) contrasts with the generalized suppression seen in scEEG, showcasing the complementary nature of these recordings.

Another study has shown that focal aware seizures and subclinical seizures are less likely to be detected on scEEG compared to other types of seizures. In this investigation, the authors found that detection rates for focal aware seizures were 33% on scEEG versus 100% on SEEG, highlighting the limitations of scEEG in identifying certain types of seizures (Casale et al., 2022).

SEEG's ability to monitor frequency-specific changes and subtle patterns in deep structures enriches the broader overview provided by scEEG. This simultaneous monitoring allows for a more comprehensive understanding of seizure onset and propagation, facilitating accurate mapping of epileptogenic zones. Integrating SEEG's detailed insights with the generalized patterns from scEEG clearly enhances diagnostic accuracy and deepens the understanding of seizure dynamics (Abramovici et al., 2018;

Altenmüller et al., 2016; Antony et al., 2019; Barborica et al., 2021; Casale et al., 2022; Ferrand et al., 2023; Iachim et al., 2021; Vossler et al., 2017).

## **The Complementary Role of scEEG in Guiding SEEG Explorations**

Scalp EEG findings are fundamental in guiding SEEG explorations, as they offer a non-invasive overview of the brain's electrical activity. By detecting patterns such as interictal spikes, seizure onset zones, and regional abnormalities, scEEG aids in forming hypotheses about potential epileptogenic areas (Jehi, 2018). During the ictal phase, scEEG can predict intracerebral SOPs, identify the lesion generating the seizures, and even estimate the depth of the SOZ. This information is especially valuable in presurgical evaluations, where scEEG is primarily used to localize the SOZ (Jehi, 2018; Rosenow, 2001).

The insights provided by scEEG are crucial in planning SEEG electrode placement, enabling targeted, precise monitoring of suspected seizure *foci*. Additionally, scEEG findings help differentiate between focal and generalized epilepsy, informing the strategy for SEEG implantation and improving the chances of successful seizure localization. Notably, Iachim et al. (2021) discovered that the automated low-density ESI approach on scEEG yielded SEEG-concordant results in more than half of the analysed cases, with sensitivity and specificity rates of 53% and 55%, respectively. These findings are significant, considering the challenges involved in visually identifying operculo-insular spikes on scEEG (Iachim et al., 2021).

On the other hand, Barborica et al. (2021) suggest that the use of independent component analysis (ICA) in scEEG has the ability to capture ictal discharges and is particularly important in identifying the SOZ, and can provide information on whether the SOZ is neocortical or if it is located in mesial structures, which is essential for surgical planning (Barborica et al., 2021).

Antony et al. (2019) questioned whether scEEG adds localization value in predicting seizure onset contralateral to SEEG. Their study demonstrated that the simultaneous use of scEEG with SEEG significantly improved the accuracy of predicting contralateral seizure onset, achieving 92,3% accuracy compared to just 33,3% with SEEG

alone. This finding emphasizes the importance of incorporating scEEG into SEEG to enhance the localization of seizure onset areas (Antony et al., 2019).

## **Alternative Co-Registration Techniques**

Although simultaneous scEEG and SEEG recordings offer valuable insights, they should not be the sole basis for identifying the EZ. It is essential to incorporate ictal clinical signs, imaging data, and neuropsychological assessments to achieve a comprehensive understanding of seizure origin (Ferrand et al., 2023).

As has been said throughout this review, complementary techniques to scEEG, such as Electrical Source Imaging (ESI) and Independent Component Analysis (ICA), serve as valuable tools for epileptologists and can play a crucial role in the presurgical evaluation of focal epilepsy, especially in patients with suspected deep irritative zones (Barborica et al., 2021; Iachim et al., 2021). However, there are also other co-registration techniques available for these cases.

Other techniques, such as MRI-based co-registration and MEG co-registration, offer distinct advantages. MRI provides detailed anatomical information that, when combined with scEEG and SEEG, can help pinpoint the precise location of the epileptogenic zone (Jacobs et al., 2024; Jehi, 2018). Simultaneous magnetoencephalography (MEG) allows for more precise source localization and identification of deep sources not covered by SEEG (Gavaret et al., 2016; Jacobs et al., 2024). Additionally, simultaneous fMRI can highlight metabolic changes following epileptic activity and help elucidate the widespread network changes associated with interictal activity (Jacobs et al., 2024; Jehi, 2018). Some authors suggest that seizures associated with MRI lesions are statistically less likely to be detected on scEEG compared to those in patients with non-lesional MRI, indicating that the presence of lesions may influence the visibility of seizures in scalp recordings (Casale et al., 2022).

Integrating these diverse techniques can lead to a more robust and accurate assessment of the epileptogenic zone, ultimately improving surgical planning and patient outcomes.

## Methodical Considerations and Limitations

This review encountered several challenges, primarily stemming from the limited number of studies available on simultaneous scEEG and SEEG recordings. Additionally, there were small flaws within the studies themselves. All included studies were retrospective observational, representing a lower level of evidence compared to prospective observational studies or randomized and non-randomized clinical trials. Most of these studies also had very small sample sizes, reflecting the currently limited number of simultaneous scEEG and SEEG recordings conducted worldwide.

The included studies exhibited substantial methodological variability, further complicating comparisons. For example, scalp electrode placement differed across studies - some employed the full international 10-20 system, while others used only a subset of electrodes. Additionally, while many studies used deep SEEG electrodes, some also incorporated grids and subdural strips. In some cases, there was a lack of clarity regarding the number of deep electrodes or contacts used. Furthermore, about half of the studies did not reference the EEG patterns observed or directly compare them with scEEG patterns, adding to the inconsistency.

These methodological differences highlight a significant gap in this area of research. Developing standardized, reproducible protocols is crucial to enable meaningful comparisons and the generalization of results.



## Conclusions and Future Directions

This systematic review underscores the potential of simultaneous scEEG and SEEG recordings in advancing the understanding of seizure patterns in DRE. Despite the known strengths of both modalities, their combined application has not been extensively explored in clinical practice. The reviewed studies reveal that simultaneous scEEG and SEEG can offer complementary insights into seizure onset and propagation, facilitating a more nuanced identification of the epileptogenic zone. This integration bridges the gap between cortical and deep brain activity, enabling improved surgical planning and more precise localization of seizure *foci*.

The findings highlight that SEEG plays a crucial role in capturing subtle interictal and ictal patterns that scEEG might miss, particularly in deep brain structures like the insula and mesial temporal regions. Conversely, scEEG provides an essential overview that guides SEEG placement and can enhance the accuracy of detecting contralateral seizure onsets. This mutual complementarity demonstrates the value of utilizing both modalities to achieve a more comprehensive assessment of epileptic activity. However, significant limitations, such as the scarcity of simultaneous scEEG and SEEG studies, methodological inconsistencies, and small sample sizes, restrict the generalizability of these findings.

Future research should focus on addressing these limitations. Standardized methodologies are essential to facilitate reproducible results, such as uniform scalp electrode placement and consistent SEEG electrode usage. Moreover, larger prospective observational studies or clinical trials would provide a higher level of evidence, enabling a more reliable comparison of electroencephalographic patterns. Additionally, the integration of alternative co-registration techniques, including fMRI and MEG, should be explored in tandem with simultaneous scEEG and SEEG recordings. These complementary modalities could enhance source localization, particularly in deep brain regions, and offer valuable metabolic and network insights that are not detectable through EEG alone.

In conclusion, while the combined use of scEEG and SEEG holds significant promise for improving seizure localization and guiding therapeutic interventions in DRE, further research is necessary to establish standardized protocols and explore multi-modal approaches. This comprehensive strategy has the potential to refine presurgical evaluation and ultimately improve surgical outcomes for patients with DRE.

## References

References marked with an asterisk indicate studies included in the review.

- Abraham, K., & Ajmone Marsan, C. (1958). Patterns of cortical discharges and their relation to routine scalp electroencephalography. *Electroencephalography and Clinical Neurophysiology*, 10(3), 447–461. [https://doi.org/10.1016/0013-4694\(58\)90006-3](https://doi.org/10.1016/0013-4694(58)90006-3)
- \*Abramovici, S., Antony, A., Baldwin, M. E., Urban, A., Ghearing, G., Pan, J., Sun, T., Krafty, R. T., Richardson, R. M., & Bagic, A. (2018). Features of Simultaneous Scalp and Intracranial EEG That Predict Localization of Ictal Onset Zone. *Clinical EEG and Neuroscience*, 49(3), 206–212. <https://doi.org/10.1177/1550059417738688>
- \*Altenmüller, D.-M., Schulze-Bonhage, A., Elger, C. E., & Surges, R. (2016). Local brain activity persists during apparently generalized postictal EEG suppression. *Epilepsy & Behavior*, 62, 218–224. <https://doi.org/10.1016/j.yebeh.2016.07.008>
- \*Antony, A. R., Abramovici, S., Krafty, R. T., Pan, J., Richardson, R. M., Bagic, A., & Haneef, Z. (2019). Simultaneous scalp EEG improves seizure lateralization during unilateral intracranial EEG evaluation in temporal lobe epilepsy. *Seizure*, 64, 8–15. <https://doi.org/10.1016/j.seizure.2018.11.015>
- \*Barborica, A., Mindruta, I., Sheybani, L., Spinelli, L., Oane, I., Pistol, C., Donos, C., López-Madróna, V. J., Vulliemoz, S., & Bénar, C.-G. (2021). Extracting seizure onset from surface EEG with independent component analysis: Insights from simultaneous scalp and intracerebral EEG. *NeuroImage: Clinical*, 32, 102838. <https://doi.org/10.1016/j.nicl.2021.102838>

- Bartolomei, F., Nica, A., Valenti-Hirsch, M. P., Adam, C., & Denuelle, M. (2018). Interpretation of SEEG recordings. *Neurophysiologie Clinique*, 48(1), 53–57. <https://doi.org/10.1016/j.neucli.2017.11.010>
- \*Casale, M. J., Marcuse, L. V., Young, J. J., Jette, N., Panov, F. E., Bender, H. A., Saad, A. E., Ghotra, R. S., Ghatan, S., Singh, A., Yoo, J. Y., & Fields, M. C. (2022). The Sensitivity of Scalp EEG at Detecting Seizures—A Simultaneous Scalp and Stereo EEG Study. *Journal of Clinical Neurophysiology*, 39(1), 78–84. <https://doi.org/10.1097/WNP.0000000000000739>
- Ebersole, J. S., & Pacia, S. V. (1996). Localization of Temporal Lobe Foci by Ictal EEG Patterns. *Epilepsia*, 37(4), 386–399. <https://doi.org/10.1111/j.1528-1157.1996.tb00577.x>
- \*Ferrand, M., Baumann, C., Aron, O., Vignal, J.-P., Jonas, J., Tyvaert, L., Colnat-Coulbois, S., Koessler, L., & Maillard, L. (2023). Intracerebral Correlates of Scalp EEG Ictal Discharges Based on Simultaneous Stereo-EEG Recordings. *Neurology*, 100(20). <https://doi.org/10.1212/WNL.0000000000207135>
- Fisher, R. S., Acevedo, C., Arzimanoglou, A., Bogacz, A., Cross, J. H., Elger, C. E., Engel, J., Forsgren, L., French, J. A., Glynn, M., Hesdorffer, D. C., Lee, B. I., Mathern, G. W., Moshé, S. L., Perucca, E., Scheffer, I. E., Tomson, T., Watanabe, M., & Wiebe, S. (2014). ILAE Official Report: A practical clinical definition of epilepsy. *Epilepsia*, 55(4), 475–482. <https://doi.org/10.1111/epi.12550>
- Gavaret, M., Dubarry, A.-S., Carron, R., Bartolomei, F., Trébuchon, A., & Bénar, C.-G. (2016). Simultaneous SEEG-MEG-EEG recordings Overcome the SEEG limited

spatial sampling. *Epilepsy Research*, 128, 68–72.

<https://doi.org/10.1016/j.eplepsyres.2016.10.013>

Grech, R., Cassar, T., Muscat, J., Camilleri, K. P., Fabri, S. G., Zervakis, M., Xanthopoulos, P., Sakkalis, V., & Vanrumste, B. (2008). Review on solving the inverse problem in EEG source analysis. *Journal of NeuroEngineering and Rehabilitation*, 5(1), 25. <https://doi.org/10.1186/1743-0003-5-25>

Higgins, J., Thomas, J., Chandler, J., Cumpston, M., Li, T., Page, M., & Welch, V. (Eds.). (2023). *Cochrane Handbook for Systematic Reviews of Interventions* (Version 6.4 (updated August 2023)). Cochrane. [www.training.cochrane.org/handbook](http://www.training.cochrane.org/handbook)

Hirtz, D., Thurman, D. J., Gwinn-Hardy, K., Mohamed, M., Chaudhuri, A. R., & Zalutsky, R. (2007). How common are the “common” neurologic disorders? *Neurology*, 68(5), 326–337. <https://doi.org/10.1212/01.wnl.0000252807.38124.a3>

\*Iachim, E., Vespa, S., Baroumand, A. G., Danthine, V., Vrielynck, P., De Tourtchaninoff, M., Fierain, A., Ribeiro Vaz, J. G., Raftopoulos, C., Ferrao Santos, S., Van Mierlo, P., & El Tahry, R. (2021). Automated electrical source imaging with scalp EEG to define the insular irritative zone: Comparison with simultaneous intracranial EEG. *Clinical Neurophysiology*, 132(12), 2965–2978. <https://doi.org/10.1016/j.clinph.2021.09.004>

Jacobs, J., Klotz, K. A., Pizzo, F., & Federico, P. (2024). Beyond Stereo-EEG: Is It Worth Combining Stereo-EEG With Other Diagnostic Methods? *Journal of Clinical Neurophysiology*, 41(5), 444–449. <https://doi.org/10.1097/WNP.0000000000001086>

- Jehi, L. (2018). The Epileptogenic Zone: Concept and Definition. *Epilepsy Currents*, 18(1), 12–16. <https://doi.org/10.5698/1535-7597.18.1.12>
- Khoo, H. M., Hall, J. A., Dubeau, F., Tani, N., Oshino, S., Fujita, Y., Gotman, J., & Kishima, H. (2020). Technical Aspects of SEEG and Its Interpretation in the Delineation of the Epileptogenic Zone. *Neurologia Medico-Chirurgica*, 60(12), 565–580. <https://doi.org/10.2176/nmc.st.2020-0176>
- Kwan, P., Arzimanoglou, A., Berg, A. T., Brodie, M. J., Allen Hauser, W., Mathern, G., Moshé, S. L., Perucca, E., Wiebe, S., & French, J. (2010). Definition of drug resistant epilepsy: Consensus proposal by the ad hoc Task Force of the ILAE Commission on Therapeutic Strategies. *Epilepsia*, 51(6), 1069–1077. <https://doi.org/10.1111/j.1528-1167.2009.02397.x>
- Lantz, G., Grave De Peralta, R., Spinelli, L., Seeck, M., & Michel, C. M. (2003). Epileptic source localization with high density EEG: How many electrodes are needed? *Clinical Neurophysiology*, 114(1), 63–69. [https://doi.org/10.1016/S1388-2457\(02\)00337-1](https://doi.org/10.1016/S1388-2457(02)00337-1)
- Lieb, J. P., Walsh, G. O., Babb, T. L., Walter, R. D., Crandall, P. H., Tassinari, C. A., Portera, A., & Scheffner, D. (1976). A Comparison of EEG Seizure Patterns Recorded with Surface and Depth Electrodes in Patients with Temporal Lobe Epilepsy. *Epilepsia*, 17(2), 137–160. <https://doi.org/10.1111/j.1528-1157.1976.tb03392.x>
- Michel, C. M. (2019). High-resolution EEG. Em *Handbook of Clinical Neurology* (Vol. 160, pp. 185–201). Elsevier. <https://doi.org/10.1016/B978-0-444-64032-1.00012-6>

- Moher, D., Liberati, A., Tetzlaff, J., Altman, D. G., & The PRISMA Group. (2009). Preferred Reporting Items for Systematic Reviews and Meta-Analyses: The PRISMA Statement. *PLoS Medicine*, 6(7), e1000097.  
<https://doi.org/10.1371/journal.pmed.1000097>
- Niedermeyer, E., & Lopes da Silva, F. H. (1993). *Electroencephalography: Basic Principles, Clinical Applications, and Related Fields* (3rd ed.). Lippincott, Williams & Wilkins.
- Ouzzani, M., Hammady, H., Fedorowicz, Z., & Elmagarmid, A. (2016). Rayyan—A web and mobile app for systematic reviews. *Systematic Reviews*, 5(1), 210.  
<https://doi.org/10.1186/s13643-016-0384-4>
- Pacia, S. V., & Ebersole, J. S. (1997). Intracranial EEG Substrates of Scalp Ictal Patterns from Temporal Lobe Foci. *Epilepsia*, 38(6), 642–654.  
<https://doi.org/10.1111/j.1528-1157.1997.tb01233.x>
- Page, M. J., McKenzie, J. E., Bossuyt, P. M., Boutron, I., Hoffmann, T. C., Mulrow, C. D., Shamseer, L., Tetzlaff, J. M., Akl, E. A., Brennan, S. E., Chou, R., Glanville, J., Grimshaw, J. M., Hróbjartsson, A., Lalu, M. M., Li, T., Loder, E. W., Mayo-Wilson, E., McDonald, S., ... Moher, D. (2021). The PRISMA 2020 statement: An updated guideline for reporting systematic reviews. *BMJ*, n71.  
<https://doi.org/10.1136/bmj.n71>
- Picot, M., Baldy-Moulinier, M., Daurès, J., Dujols, P., & Crespel, A. (2008). The prevalence of epilepsy and pharmaco-resistant epilepsy in adults: A population-based study in a Western European country. *Epilepsia*, 49(7), 1230–1238.  
<https://doi.org/10.1111/j.1528-1167.2008.01579.x>

PRISMA-P Group, Moher, D., Shamseer, L., Clarke, M., Ghersi, D., Liberati, A., Petticrew, M., Shekelle, P., & Stewart, L. A. (2015). Preferred reporting items for systematic review and meta-analysis protocols (PRISMA-P) 2015 statement. *Systematic Reviews, 4*(1), 1. <https://doi.org/10.1186/2046-4053-4-1>

Rosenow, F. (2001). Presurgical evaluation of epilepsy. *Brain, 124*(9), 1683–1700. <https://doi.org/10.1093/brain/124.9.1683>

Shao, S.-C., Kuo, L.-T., Huang, Y.-T., Lai, P.-C., & Chi, C.-C. (2023). Using Grading of Recommendations Assessment, Development, and Evaluation (GRADE) to rate the certainty of evidence of study outcomes from systematic reviews: A quick tutorial. *Dermatologica Sinica, 41*(1), 3. <https://doi.org/10.4103/ds.DS-D-22-00154>

Tanaka, H., Khoo, H. M., Dubeau, F., & Gotman, J. (2018). Association between scalp and intracerebral electroencephalographic seizure-onset patterns: A study in different lesional pathological substrates. *Epilepsia, 59*(2), 420–430. <https://doi.org/10.1111/epi.13979>

\*Vossler, D. G., Kraemer, D. L., & Bell, A. J. (2017). The Hippocampus and Cortex Together Generate the Scalp EEG Ictal Discharge in Temporal Lobe Epilepsy. *Journal of Clinical Neurophysiology, 34*(5), 448–455. <https://doi.org/10.1097/WNP.0000000000000394>

World Health Organization. (2019). *Epilepsy: A Public Health Imperative*.

Zorzos, I., Kakkos, I., Ventouras, E. M., & Matsopoulos, G. K. (2021). Advances in Electrical Source Imaging: A Review of the Current Approaches, Applications and Challenges. *Signals*, 2(3), 378–391. <https://doi.org/10.3390/signals2030024>