



Contents lists available at ScienceDirect

American Journal of Emergency Medicine

journal homepage: www.elsevier.com/locate/ajemThe
American Journal of
Emergency Medicine

Correspondence

Benign acute childhood myositis: an alarming condition with an excellent prognosis! ☆

To the Editor,

Benign acute childhood myositis (BACM) causes difficulty to walk due to severe bilateral calf pain. We report the clinical and laboratory features of children admitted with BACM to a level II hospital's pediatric department, from January 2001 to December 2012 (12 years). Data were collected retrospectively from patient's clinical records. The purpose was to characterize BACM's clinical picture, providing greater awareness to its benign course and helping to differentiate it from more serious disorders.

Twenty-eight admissions were identified (2.5/1000 admissions), corresponding to 25 children (Table). There was a 4.6:1 male:female ratio (21 boys, 84%). Median age was 7 years (range, 4–10 years), and 82% were older than 5 years. Most cases were seen from 2008 to 2010 (n = 19, 67.9%) and during winter and spring (n = 20, 71.4%) (Figs. 1 and 2). All occurred at the early convalescent phase of an upper respiratory infection. History of recent trauma or vigorous exercise and family history of neuromuscular disorders were negative. On physical examination at the pediatric emergency department, all patients were unable to walk/bear weight. Bilateral gastrocnemius-soleus muscles were tender to mild palpation without other inflammatory signs. Lower extremity sensation was intact, with normal strength, tone, and deep tendon reflexes. Children were admitted for clinical and laboratory follow-up because of serious functional impairment (n = 24, 85.7%) or previous history of BACM/recurrence (n = 4). The following laboratory abnormalities were detected (Table): leukopenia (n = 10), neutropenia (n = 7), thrombocytopenia (n = 6), and mildly elevated C-reactive protein (CRP) (n = 2). All children presented a markedly elevated serum creatine kinase (CK); median admission value was 4181 U/L (range, 785–26863 U/L). In the 22 available aminotransferase results, aspartate transaminase (AST) was elevated in all, with a less increased alanine transaminase (ALT) level in 12 cases. Blood urea nitrogen, creatinine, electrolytes, and urinalysis were normal. Serologic tests were performed in 20 cases (71.4%), with 9 positive results (Table): *Mycoplasma pneumoniae* (n = 3), cytomegalovirus and influenza A (n = 2), and influenza B and adenovirus (n = 1).

Median admission period was 3 days (range, 1–7 days), and all children revealed clinical and laboratory improvement with supportive therapy (bed rest, intravenous hydration, and oral ibuprofen). No red to brown urine or renal/hydroelectrolytic abnormalities were seen. Children with recurrent episodes were reassessed at pediatric consultation 1 month after discharge, with full recovery and normal CK levels. The remaining patients were referred to their attending physician.

☆ Conflict of interest: None.

Benign acute childhood myositis is a rare disorder and continues to lead physicians into unnecessary workup when they are unfamiliar with its presentation [1–5]. Most commonly occur after influenza B and occasionally influenza A infection, but parainfluenza, adenovirus, herpes simplex, Epstein-Barr, Coxsackie, rotavirus, and *M pneumoniae* have also been implicated [1–3,5–10], as found in our study. As evidenced, key elements in the diagnosis are a preceding upper respiratory infection followed by the acute onset of typical myositis clinical findings, predominantly affecting gastrocnemius-soleus muscles. Further clinical features include school-aged boys and late winter–early spring predominance, elevated CK, and aminotransferase levels (especially AST) [1–10]. Transient hematological abnormalities (mild leukopenia, neutropenia, and thrombocytopenia) are also seen [1,3,8–10]. Erythrocyte sedimentation rate and CRP are usually normal but may be mildly elevated [1–3,5,6]. Patients with this typical clinical presentation can be treated as an outpatient [1,5]. However, as seen in our study, some children are admitted for hydration, observation, and serial CK levels to rule out any progression to rhabdomyolysis [1,6,8–10]. Recurrence is rare and has been demonstrated to be caused by different viruses or different influenza types [9]. In our study, 3 children had recurrent episodes with more than a year interval, and they totally recovered in between. If different etiologic agents were behind these episodes, it was not possible to assess. Treatment is supportive, and antivirals are unlikely to be beneficial [2–5]. The hallmark of BACM is its spontaneous and rapid clinical resolution within 1 week [1–5]. In this study, all children fully recovered within a week or less only with supportive measures. Higher CK levels were not associated with acute renal failure, progression to rhabdomyolysis, or other complications. Patients can be discharged if they have typical presentation, normal renal function, and follow-up to ensure complete resolution [2,10]. Further investigation is not indicated unless there is clinical concern for more serious disorders [1,6,8,10]. Findings not classically associated with BACM include myoglobinuria, recent trauma or vigorous exercise, family history of neuromuscular disorders, subacute or chronic progression, a new rash, frank muscle weakness, or abnormal neurologic findings. When such atypical features are present, other diagnosis as rhabdomyolysis, Guillain-Barré syndrome, primary inflammatory myositis, muscular dystrophy, or metabolic disease must be excluded [2,6,8,10].

Benign acute childhood myositis should be part of the broad differential diagnosis of a child unable to walk/bear weight. Although potentially alarming, it is self-limited with an excellent prognosis. Recognition of this rare clinical entity by the emergency physician is essential to prevent unnecessary invasive testing and hospital admission.

Table
Clinical and laboratory features of 25 children admitted with BACM

Child no.	Sex	Age (y)	Admission main criteria	WBC ($\times 10^9/L$)	ANC ($\times 10^9/L$)	Platelet count ($\times 10^9/L$)	CRP (mg/L)	Admission CK (UI/L)	AST (UI/L)	ALT (UI/L)	Serology (IgM +)	Hospital stay (d)
1	M	7	FI	8.5	N	N	N	4095	NA	NA	–	2
2	M	10	FI	3.0	1.341	N	N	4369	NA	NA	–	4
3	M	4	FI	8.1	N	N	N	4275	NA	NA	Influenza B	2
4	M	10	FI	2.6	0.754	N	N	6629	428	90	–	2
5	M	7	FI	4.8	N	N	N	5020	234	56	CMV	3
6	M	6	FI	5.2	N	N	N	10157	352	69	–	2
7	M	5	FI	4.6	N	N	N	7125	124	31	–	3
8	M	10	FI	4.6	N	N	N	2329	103	30	–	2
9	M	10	FI	4.4	N	145	N	6022	288	95	–	2
10	M	7	FI	4.2	1.218	N	N	1582	133	29	<i>M. pneum</i>	2
11	F	5	FI	2.4	0.823	145	N	4267	157	52	<i>M. pneum</i>	3
12	M	8	FI	3.8	N	N	N	1250	59	18	–	2
13	M	5	R 2 nd episode	5.3	N	N	25	6790	NA	NA	Influenza A	4
14	M	5	FI	6.3	N	N	N	6466	NA	NA	CMV	3
15	M	6	FI	5.7	N	N	52	3927	141	40	Adenovirus	5
16	M	7	FI	2.6	0.762	63	N	3156	NA	NA	<i>M. pneum</i>	7
17	M	10	R third episode	5.6	N	N	N	785	157	71	–	4
18	M	10	FI	3.1	1.240	N	N	2815	134	41	–	3
19	M	10	FI	5.5	N	N	N	2049	149	68	–	4
20	F	8	FI first episode	4.2	N	123	N	26863	907	21	–	2
21	M	8	FI	3.3	1.340	N	N	1455	79	32	–	2
22	F	6	FI	4.5	N	93	N	3298	117	35	–	3
23	F	9	R second episode	3.9	N	109	N	10979	387	94	Influenza A	5
24	M	7	FI	5.3	N	N	N	1064	158	17	–	2
25	M	8	FI first episode	5.2	N	N	N	21492	1070	203	–	6
26	F	8	FI	3.3	N	N	N	3271	91	29	–	1
27	M	5	FI	3.3	N	N	N	1851	106	37	–	2
28	M	9	R second episode	5.8	N	N	N	14453	451	108	–	7
Median abnormal values				3.2	1.218	116	38.5	4181	153	70		

Child 13, 19, and 23 presented recurrent episodes (child 13 had a previous episode out of the study period). Bold numbers indicate abnormal values. Reference range: CRP, less than 5 mg/L; CK, 31 to 152 UI/L; AST, less than 31 UI/L; ALT, less than 39 UI/L. Leukopenia: white blood cell count less than $4 \times 10^9/L$; neutropenia: absolute neutrophil count less than $1.5 \times 10^9/L$; thrombocytopenia: platelet count less than $150 \times 10^9/L$. Viral and bacterial identification was based on serologic tests with a positive immunoglobulin M result. Abbreviations: ANC, absolute neutrophil count; CMV, cytomegalovirus; F, female; FI, functional impairment; IgM, immunoglobulin M; M, male; *M. pneum*, *Mycoplasma pneumoniae*; n, absolute number; N, normal value; NA, not available; R, recurrence; WBC, white blood cell count.

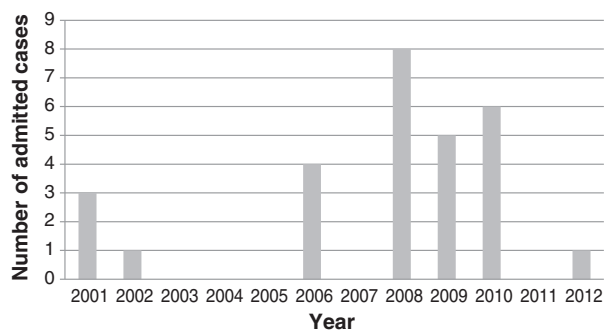


Fig. 1. Annual distribution of admitted cases with BACM. Most cases were seen from 2008 to 2010 (n = 19, 67.9%).

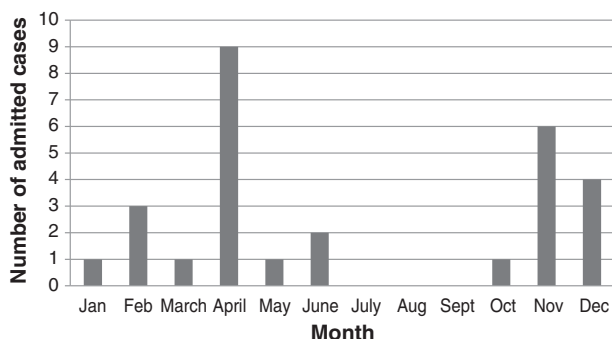


Fig. 2. Monthly distribution of admitted cases with BACM. Most cases were seen during winter and spring.

Joana Almeida Santos MD
Pediatric Department, Hospital Dona Estefânia
Centro Hospitalar Lisboa Central Lisbon, Portugal
E:mail address: joanaasantos@gmail.com

Carolina Albuquerque MD
David Lito MD
Florabela Cunha MD
Pediatric Department
Hospital de Vila Franca de Xira
Vila Franca de Xira, Portugal

E:mail addresses: carolinialbuquerque@gmail.com (C. Albuquerque),
dmlito@gmail.com (D. Lito), flor.cunha@gmail.com (F. Cunha)

<http://dx.doi.org/10.1016/j.ajem.2014.08.022>

References

- [1] Hall G, Schranz CI. Benign acute childhood myositis—a rare cause of abnormal gait. *Am J Emerg Med* 2014;32(2):193.e1–2.
- [2] Heiner JD, Ball VL. A child with benign acute childhood myositis after influenza. *J Emerg Med* 2010;39(3):316–9.
- [3] Koliou M, Hadjiloizou S, Ourani S, Demosthenous A, Hadjidemetriou A. A case of benign acute childhood myositis associated with influenza A (H1N1) virus infection. *Clin Microbiol Infect* 2010;16(2):193–5.
- [4] Neocleous C, Spanou C, Mpampalis E, Xatzigeorgiou S, Pavlidou C, Poulos E, et al. Unnecessary diagnostic investigations in benign acute childhood myositis: a case series report. *Scott Med J* 2012;57(3):182.
- [5] Rubín E, De la Rubia L, Pascual A, Domínguez J, Flores C. Benign acute myositis associated with H1N1 influenza A virus infection. *Eur J Pediatr* 2010;169(9):1159–61.
- [6] Agyeman P, Duppenhaler A, Heinger U, Aebi C. Influenza-associated myositis in children. *Infection* 2004;32(4):199–203.

- [7] Hu JJ, Kao CL, Lee PI, Chen CM, Lee CY, Lu CY, et al. Clinical features of influenza A and B in children and association with myositis. *J Microbiol Immunol Infect* 2004;37(2):95–8.
- [8] Jain S, Kolber MR. A stiff-legged gait: benign acute childhood myositis. *CMAJ* 2009; 181(10):711–3.
- [9] King BA. Benign acute childhood myositis as a cause of failure to weight bear. *J Paediatr Child Health* 2003;39(5):378–80.
- [10] Rennie LM, Hallam NF, Beattie TF. Benign acute childhood myositis in an accident and emergency setting. *Emerg Med J* 2005;22(10): 686–8.