

Case 10940

A pitfall case of endometrial serous adenocarcinoma

Lara Delgado¹, Teresa Margarida Cunha²

Section: Genital (Female) Imaging

Published: 2013, Jul. 10

Patient: 78 year(s), female

Authors' Institution

(1) Centro Hospitalar de Lisboa Ocidental, Lisbon, Portugal

(2) Instituto Português de Oncologia de Lisboa Francisco Gentil, Lisbon, Portugal

Email: lara_sofia_81@hotmail.com

Clinical History

A 78 year-old-woman presented with a 6 month history of metrorrhagia and pelvic pain. The past medical history was unknown. The patient was referred for a pelvic ultrasound examination and, subsequently, a pelvic magnetic resonance imaging (MRI) was performed.

Imaging Findings

A gynecological ultrasound (not showed) revealed two contiguous cystic lesions with 63 and 104 mm, with scattered internal echos. A solid component was observed as a vegetation on the the largest cyst. The uterus was not visualized.

Subsequently, the patient was referred for an MRI which showed, above the vaginal cuff, a fluid filled structure with folded configuration, with high signal intensity on T1 (Fig. 1) and on T2 (Fig. 2) weighted images (WI); the signal intensity remained high on fat-suppressed T1WI, revealing its either high protein or hemorrhagic content. Additionally scattered vegetations were seen with low

signal intensity on T1WI, intermediate signal intensity on T2WI and presenting homogeneous enhancement after Gadolinium-DTPA administration on fat-suppressed T1WI (Fig. 3).

Both ovaries were seen separate from the lesion without detectable abnormalities.

Discussion

Endometrial carcinoma is the fourth most common female cancer and the most common malignancy of the female reproductive tract [1]. Most cases are diagnosed after menopause with highest incidence around the seventh decade of life [2].

About 80% of all endometrial carcinomas are adenocarcinomas of the endometrioid type. Most of the endometrioid carcinomas are well to moderately differentiated and arise on a background of endometrial hyperplasia [2].

Serous carcinoma is the most aggressive type of non-endometrioid endometrial carcinomas [2].

In postmenopausal patients atrophy related to decrease in endocervical glands results in decreased secretion of mucus and represent a frequent cause of cervical stenosis, which when severe results in hydrometra, pyometra or hematometra [3].

In this case report the patient presents with a 6 month history of metrorrhagia and pelvic pain, and is referred for ultrasound examination and subsequently for MRI.

In the presence of a pelvic dilated tubular fluid-filled (high protein or hemorrhagic content) structure with folded configuration, incomplete septations and scattered solid vegetation, a fallopian tube or an endometrial malignant tumor should be considered as differential diagnose.

Tubal origin should be suspected in the presence of a dilated tubular adnexal structure with folded configuration separated from the ovaries, with relatively thin walls and thin longitudinally oriented folds along the interior of the tube [3]. The lesion was centrally located in the pelvis, just above the vaginal cuff between the bladder and the rectum. The inverted pear shape and the reduction in the diameter in the median zone (uterine isthmus) allow the identification of the uterus.

The MRI revealed distention of the endometrial cavity and cervical canal with hematometra and scattered foci of solid endometrial and cervical canal vegetations, without invasion of the outer half of the myometrium.

MRI is essential for the preoperative staging of endometrial cancer because it can accurately depict the depth of myometrial invasion, which is the most important morphological prognostic factor and correlates with tumor grade, presence of lymph node metastases, and the overall patient survival [4].

Cervical and endometrial and biopsy were performed revealing a serous adenocarcinoma.

Despite the aggressive behavior of the tumor, given the age of the patient three months later, total hysterectomy, bilateral pelvic adnexectomy, partial omentectomy and paraaortic and pelvic lymphadenectomy were performed. Histological evaluation revealed a multifocal endometrial tumor with invasion of the inner half of the myometrium without lymph node involvement.

Clinical history and good knowledge of anatomy are essential for correct interpretation of images.

Final Diagnosis

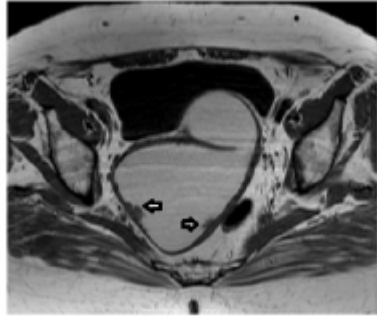
Serous adenocarcinoma of the endometrium.

Differential Diagnosis List

Endometrial Carcinoma, Primary Fallopian Tube Carcinoma

Figures

Figure 1 Figure 1 Pelvic MR



T1-weighted image on axial plane shows a high signal intensity fluid filled structure with folded configuration and with scattered low signal vegetations (arrows).

© Ramalho M, Department of Radiology, Hospital Garcia de Horta, Lisboa, Portugal

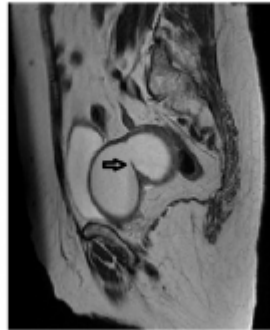
Area of Interest: Genital / Reproductive system female;

Imaging Technique: MR;

Procedure: Staging;

Special Focus: Tissue characterisation;

Figure 2 Figure 2 Pelvic MR



T2-weighted image on sagittal plane shows a high signal intensity fluid filled structure with folded configuration and an incomplete septation (arrow).

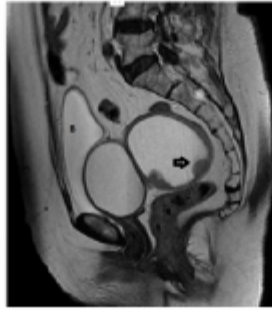
© Ramalho M, Departement of Radiology, Hospital Garcia de Horta, Lisboa, Portugal

Area of Interest: Genital / Reproductive system female;

Imaging Technique: MR;

Procedure: Staging;

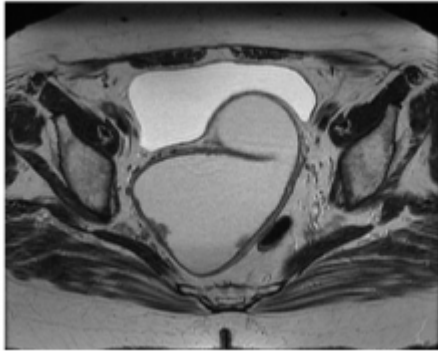
Special Focus: Tissue characterisation;



T2-WI on sagittal plane shows above the vaginal cuff between the bladder and the rectum a centrally located high signal intensity fluid filled structure with folded configuration with scattered intermediate signal intensity vegetations (arrow)

© Ramalho M, Department of Radiology, Hospital Garcia de Horta, Lisboa, Portugal

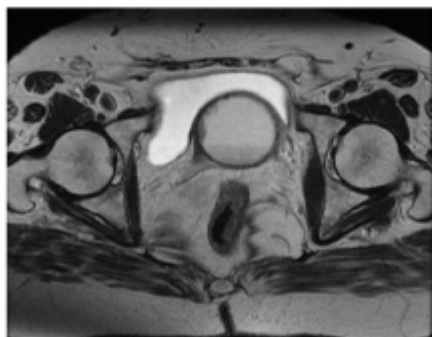
Area of Interest: Genital / Reproductive system female;
Imaging Technique: MR;
Procedure: Staging;
Special Focus: Tissue characterisation;



T2-weighted image on axial plane shows a high signal intensity fluid filled structure with folded configuration and with scattered intermediate signal vegetations.

© Ramalho M, Department of Radiology, Hospital Garcia de Horta, Lisboa, Portugal

Area of Interest: Genital / Reproductive system female;
Imaging Technique: MR;
Procedure: Diagnostic procedure;
Special Focus: Neoplasia;

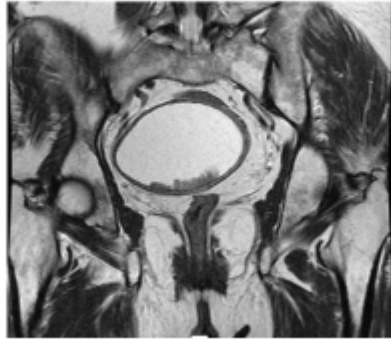

T2-weighted image on axial plane shows a cystic lesion, with intermediate signal intensity vegetations.

© Ramalho M, Department of Radiology, Hospital Garcia de Horta Lisboa, Portugal

Area of Interest: Genital / Reproductive system female;

Imaging Technique: MR;
Procedure: Diagnostic procedure;
Special Focus: Neoplasia;

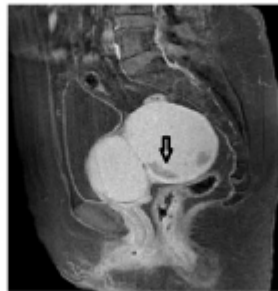

T2-weighted image on coronal plane shows a cystic lesion, with intermediate signal intensity vegetations.

© Ramalho M, Department of Radiology, Hospital Garcia de Horta, Lisboa, Portugal

Area of Interest: Genital / Reproductive system female;
Imaging Technique: MR;
Procedure: Diagnostic procedure;
Special Focus: Neoplasia;

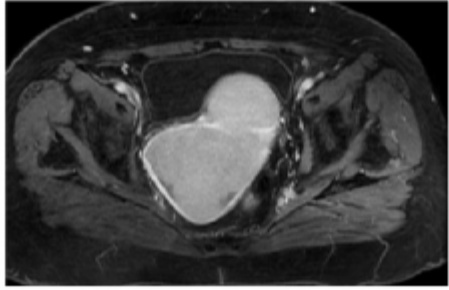
Figure 3 Figure 3 Pelvic MR



Fat-suppressed T1WI after gadolinium administration on sagittal plane shows the high signal intensity of the fluid filled structure showing either high protein or hemorrhagic content and the solid vegetations (arrow)

© Ramalho M, Department of Radiology, Hospital Garcia de Horta, Lisboa, Portugal

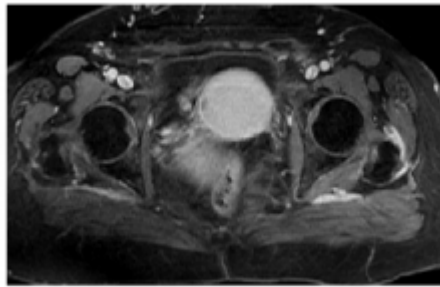
Area of Interest: Genital / Reproductive system female;
Imaging Technique: MR;
Procedure: Staging;
Special Focus: Tissue characterisation;



Fat-suppressed T1WI after gadolinium administration on axial plane shows the enhancement of the solid vegetations.

© Ramalho M, Departement of Radiology, Hospital Garcia de Horta, Lisboa, Portugal

Area of Interest: Genital / Reproductive system female;
Imaging Technique: MR;
Procedure: Diagnostic procedure;
Special Focus: Neoplasia;



Fat-suppressed T1WI after gadolinium administration on axial plane shows the enhancement of the solid vegetations.

© Ramalho M, Departement of Radiology, Hospital Garcia de Horta, Lisboa, Portugal

Area of Interest: Genital / Reproductive system female;
Imaging Technique: MR;
Procedure: Diagnostic procedure;
Special Focus: Neoplasia;

MeSH

Endometrium [A05.360.319.679.490]

The mucous membrane lining of the uterine cavity that is hormonally responsive during the MENSTRUAL CYCLE and PREGNANCY. The endometrium undergoes cyclic changes that characterize MENSTRUATION. After successful FERTILIZATION, it serves to sustain the developing EMBRYO.

Fallopian Tubes [A05.360.319.114.373]

A pair of highly specialized muscular canals extending from the UTERUS to its corresponding OVARY. They provide the means for OVUM collection, and the site for the final maturation of gametes and FERTILIZATION. The fallopian tube consists of an interstitium, an isthmus, an

ampulla, an infundibulum, and fimbriae. Its wall consists of three histologic layers: serous, muscular, and an internal mucosal layer lined with both ciliated and secretory cells.

Endometrial Neoplasms [C13.371.270.875.750]

Tumors or cancer of ENDOMETRIUM, the mucous lining of the UTERUS. These neoplasms can be benign or malignant. Their classification and grading are based on the various cell types and the percent of undifferentiated cells.

References

- [1] Sala E, Walkely S, Senior E, Lomas D (2007) MRI of Malignant Neoplasms of the Uterine Corpus and Cervix AJR Jun;188(6):1577-8
- [2] Hamm B, Forstner R, Baert A, Knauth M, Sartor K (2007) MR and CT of the Female Pelvis Springer-Verlag Berlin Heidelberg (101-102)
- [3] Hricak H, Akin O, Sala E, Ascher S, Levine Deborah, Reinhold C (2007) Diagnostic imaging Gynecology (3-2;8-6)
- [4] Beddy P, O'Neil A, Yamamoto A, Addley H, Reinhold C, Sala E (2012) Figo Staging System for Endometrial Cancer: Added Benefits of MR Imaging Radiographics Jan-Feb;32(1):241-54

Citation

Lara Delgado¹, Teresa Margarida Cunha² (2013, Jul. 10)

A pitfall case of endometrial serous adenocarcinoma {Online}

URL: <http://www.eurorad.org/case.php?id=10940>