



# Retinopathy of prematurity: contribution of inflammatory and genetic factors

Mariza Fevereiro-Martins<sup>1,2,3</sup> · Hercília Guimarães<sup>5</sup> · Carlos Marques-Neves<sup>1,4</sup> · Manuel Bicho<sup>1,2</sup>

Received: 16 July 2021 / Accepted: 16 February 2022

© The Author(s), under exclusive licence to Springer Science+Business Media, LLC, part of Springer Nature 2022

## Abstract

Retinopathy of prematurity (ROP) is a retinal vasoproliferative disorder that represents an important cause of childhood visual impairment and blindness. Although oxidative stress has long been implicated in ROP etiology, other prenatal and perinatal factors are also involved. This review focuses on current research involving inflammation and genetic factors in the pathogenesis of ROP. Increasing evidence suggests that perinatal inflammation or infection contributes to ROP pathogenesis. Cytokines and chemokines with a fundamental role in inflammatory responses and that significantly contributing to angiogenesis are analyzed. Microglia cells, the retinal-resident macrophages, are crucial for retinal homeostasis, however, under sustained pathological stimuli release exaggerated amounts of inflammatory mediators and can promote pathological neovascularization. Current modulation of angiogenic cytokines, such as treatment with antibodies to vascular endothelial growth factor (anti-VEGF), has shown efficacy in the treatment of ocular neovascularization; however, some patients are refractory to anti-VEGF agents, suggesting that other angiogenic or anti-angiogenic cytokines need to be identified. Much evidence suggests that genetic factors contribute to the phenotypic variability of ROP. Several studies have implicated the involvement of candidate genes from different signaling pathways in the development of ROP. However, a genetic component with a major impact on ROP has not yet been discovered. Most studies have limitations and did not replicate results. Future research involving bioinformatics, genomics, and proteomics may contribute to finding more genes associated with ROP and may allow discovering better solutions in the management and treatment of ROP.

**Keywords** Retinopathy of prematurity · Inflammation · Polymorphism · Genetic · Angiogenesis · Preterm infant

## Abbreviations

AA	Arachidonic acid	BV	Blood vessels
ADAM	“A” disintegrin and metalloproteinase	BW	Birth weight
ANGs	Angiopoietins	EC	Endothelial cells
BDNF	Brain-derived neurotrophic factor	eNOS	Endothelial nitric oxide synthase
bFGF	Basic fibroblast growth factor	ECM	Extracellular matrix
BH4	Tetrahydrobiopterin	EPAS1	Endothelial PAS Domain Protein 1
		EPO	Erythropoietin

✉ Mariza Fevereiro-Martins  
martins.mariza@campus.ul.pt

Hercília Guimarães  
herciliaguimaraes@gmail.com

Carlos Marques-Neves  
bombordo.seven@gmail.com

Manuel Bicho  
manuelbicho@medicina.ulisboa.pt

<sup>1</sup> Laboratório de Genética and Grupo Ecogenética e Saúde Humana, Instituto de Saúde Ambiental, Faculdade de Medicina, Universidade de Lisboa, Av. Professor Egas Moniz, Piso 1C, 1649-028 Lisboa, Portugal

<sup>2</sup> Instituto de Investigação Científica Bento da Rocha Cabral, Calçada Bento da Rocha Cabral 14, 1250-012 Lisboa, Portugal

<sup>3</sup> Departamento de Oftalmologia, Hospital Cuf Descobertas, Rua Mário Botas, 1998-018 Lisboa, Portugal

<sup>4</sup> Centro de Estudos das Ciências da Visão, Faculdade de Medicina, Universidade de Lisboa, Av. Professor Egas Moniz, Piso 1C, 1649-028 Lisboa, Portugal

<sup>5</sup> Departamento de Ginecologia- Obstetrícia e Pediatria, Faculdade de Medicina, Universidade do Porto, Alameda Prof. Hernâni Monteiro, 4200-319 Porto, Portugal

FEVR	Familial exudative vitreoretinopathy
GA	Gestational age
HIF	Hypoxia-inducible factor
HMOX-1	Heme oxygenase 1
ICAM-1	Intercellular adhesion molecule-1
IFN- $\gamma$	Interferon gamma
IGF-1	Insulin-like growth factor 1
IL	Interleukin
IL-1Ra	Interleukin 1 receptor antagonist
iNOS	Inducible nitric oxide synthase
I-TAC	Interferon-inducible T-cell alpha chemoattractant
LPS	Lipopolysaccharide
MCP-1	Monocyte chemotactic protein 1
MMPs	Matrix metalloproteinases
NGF	Nerve growth factor
NTs	Neurotrophins
OIR	Oxygen-induced retinopathy
OS	Oxidative stress
PC	Prostacyclin
PDGF	Platelet-derived growth factor
PGs	Prostaglandins
PLA2	Phospholipase A2
PLGF	Placental growth factor
PPAR $\gamma$	Proliferator-activated receptor gamma
PTI	Preterm infants
RANTES	Regulated on activation, normal T cell expressed and secreted
ROP	Retinopathy of prematurity
ROS	Reactive oxygen species
Sema3A	Semaphoring 3A
SNPs	Single-nucleotide polymorphisms
TA	Thromboxane
TGF- $\beta$	Transforming growth factor beta
TNF- $\alpha$	Tumor necrosis factor alpha
Trk	Tropomyosin kinase
VEGF	Vascular endothelial growth factor
VEGFR	Vascular endothelial growth factor receptor
Wk	Weeks

Retinopathy of prematurity (ROP) is a retinal vasoproliferative disorder that affects preterm infants (PTI) and represents an important cause of blindness and childhood visual impairment [1] in developed and developing countries [2, 3].

The development of the retinal vascularization begins around 16 weeks of gestation, proceeds centrifugally from the optical disc to the peripheral retina, and is completed approximately at term [4]. For this reason, the retina of PTI is incompletely vascularized, with a peripheral avascular area that depends on the immaturity of the newborn infant [4, 5].

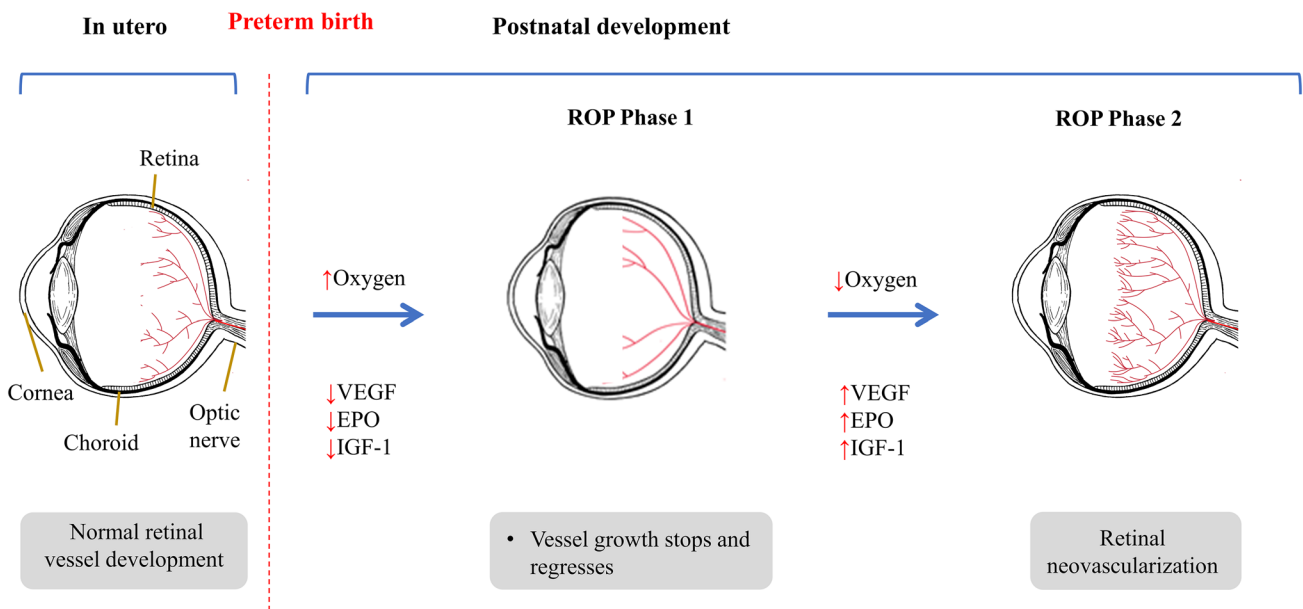
Clinical findings in PTI and studies in animal models of oxygen-induced retinopathy (OIR), of which the mouse OIR model (5 days of exposure to 75% oxygen after birth, followed by room air) is one of the most used [6], have shown that ROP has two phases (Fig. 1) [7]. The exposition of the immature retinal blood vessels (BV) to a relatively hyperoxic environment due to premature birth interrupts the vascular development [8]. This leads to microvascular retinal degeneration with an arrest in the vascularization of the peripheral retina (phase 1) [9]. The resulting retinal ischemia triggers the release of growth factors responsible for pathological angiogenesis (phase 2) [7, 10]. The new BV lead to the formation of a fibrovascular scar that may cause retinal detachment and vision loss [11]. It remains unclear why some PTI have a severe and rapidly progressive form of ROP, designated aggressive ROP (A-ROP) [12].

Retinopathy of prematurity is classified in five stages according to its severity [12]. In stage 1 a fine demarcation line is visible between the vascular and the avascular area of the retina [12]. This flat line can progress to a ridge that defines stage 2 [12]. These two first stages are considered initial or mild ROP and can regress spontaneously. In stage 3 there is pathological vessel proliferation over the ridge and into the vitreous, a feature of severe ROP [13]. The new abnormal vessels can bleed into the vitreous chamber, causing fibrosis and traction and thereby lead to a partial detachment of the retina that defines phase 4 [13]. This can evolve to stage 5, in which retina is totally detached [13].

In most studies over time the incidence of ROP is approximately 60% and of severe ROP (stages 3 to 5) is approximately 15% in PTI with birth weight (BW) of less than 1500 g [14, 15]. However, in a multicenter study conducted in the USA and Canada that included 7,483 with BW of less than 1501 g, the incidence of ROP was 43.1% and that of severe ROP was 12.4% [16] (Table 1). Severe ROP occurs mostly among PTI with birth weight less than 1251 g [16]. Globally, of the 14.9 million PTI in 2010, approximately 184,700 developed any stage of ROP, over 30,000 of whom became visually impaired as a consequence of ROP [17]. Sixty-five percent of the visually impaired due to ROP were born in middle-income regions [17].

Retinopathy of prematurity is considered a multifactorial disease that involves prenatal and postnatal factors [18]. Oxidative stress (OS) which can result from inflammation [19, 20] has long been implicated in the etiology of ROP [20, 21]. It is recognized that inflammatory processes can interfere with normal retinal vascularization and, more recently, are also considered important factors in the pathogenesis of ROP [20].

Genetic polymorphisms involve one of two or more sequence variants of a specific DNA sequence and occur with a population frequency of at least 1% [23]. Genetic



**Fig. 1** Development of retinopathy of prematurity. During fetal growth, retinal vascularization normally develops from the optic nerve in a centrifugal direction toward the periphery of the retina. Low oxygen tension in utero is the main stimulus for retinal vascular development, which is interrupted due to the increased bioavailability of oxygen caused by premature birth. ROP pathogenesis develops in two phases. In the first phase retinal vessel growth stops and regresses because the hyperoxic environment necessary to maintain adequate

levels of circulating oxygen for the survival of the preterm infant inhibits retinal vascularization (Phase 1). As the newborn grows and the metabolic requirements of retina increase, retina becomes hypoxic, inducing a compensatory, albeit devastating and aberrant, neovascularization driven by oxygen-regulated angiogenic factors (Phase 2). *EPO* erythropoietin; *IGF-1* insulin-like growth factor 1; *ROP* retinopathy of prematurity; *VEGF* vascular endothelial growth factor

polymorphisms can influence the activity of encoded enzymes and the susceptibility to develop complications induced by reactive oxygen species (ROS) provided by genes involved in the regulation of OS [1, 22]. Studies have shown associations of genetic polymorphisms in genes involved in the pro-oxidant and pro-inflammatory response to premature birth and diseases related to OS in PTI [23].

Although ROP is strongly associated with extreme prematurity [24], environmental factors have also been implicated in the development of ROP, mainly high oxygen supplementation after birth and fluctuations in oxygenation [25, 26], but also nutrition [27], factors related to the causes of preterm birth [28], use of maternal medications [29], maternal smoking [30], altitude [31], length of day during early gestation [32], and assisted conception [33, 34]. These perinatal factors may alter gene expression through DNA acetylation and methylation, supporting the supposition that epigenetic modifications by external factors may affect gene expression and render PTI susceptible to severe ROP or PTI genetically prone to ROP not to develop retinopathy [35].”

In addition to the contribution of environmental factors, a marked genetic predisposition to ROP is suggested from research based on the candidate gene approach, twin studies, experimental, and clinical studies. The observation that ROP in a subset of PTI progresses to a severe stage, while in

others with similar clinical characteristics regresses spontaneously is a strong indication of the genetic contribution to the etiology of ROP [36, 37].

Identifying susceptibility factors for ROP and a better comprehension of its pathogenesis is determinant for its proper prevention and treatment. It may also help to clarify the pathophysiology of other pediatric and adult neovascular retinal diseases. This review focuses on current research that involves inflammation and genetic factors in the pathogenesis of ROP.

### The role of inflammation as a stress response: mediators of immune and inflammatory response in ROP

Prenatal and postnatal systemic inflammation might predispose to ROP, and this sensitization effect may constitute a pre-stage of the disease [38]. Inflammatory stimuli such as chorioamnionitis [39] and neonatal bacteremia [40] have been suggested in several studies to be risk factors for ROP, possibly due to systemic inflammation [38]. Systemic inflammation in animal models has also been shown to disrupt the development of retinal BV and leads to aberrant retinal vascularization [41].

**Table 1** Summary table of epidemiological and genetic aspects in clinical and experimental studies in ROP

Clinical studies	Study design and participants	Findings	References
Objectives			
Analyze ROP incidence and/or determine <i>risk factors</i> for the development of ROP	Multicenter Trial of Cryotherapy for Retinopathy of Prematurity (CRYO-ROP) (1986–1987), 4099 PTI with BW < 1251 g from the USA	65.8% of PTI developed some degree of ROP. ROP incidence was 81.6% for PTI with BW < 1000 g. The incidence of ROP was independent of whether the newborn was male or female. An increased risk for the development of ROP was associated with younger gestational age, lower birth weights, white race, being born outside a study center nursery, and multiple birth	[95, 97, 110]
Analyze and compare the incidence of severe ROP between <i>Caucasian</i> and <i>black PTI</i>	Multicenter Trial of Cryotherapy for Retinopathy of Prematurity (CRYO-ROP) (1986–1987), 4099 PTI with BW < 1251 g from the USA	Severe ROP was more frequent in low-BW Caucasian PTI than in low-BW black PTI apparently at equivalent risk	
To determine the ROP incidence in the Early Treatment for Retinopathy of Prematurity (ETROP) Study and compare the results with those obtained in the Cryotherapy for Retinopathy of Prematurity (CRYO-ROP) Study	Multicenter prospective study (2000 to 2002) 6998 PTI with BW < 1251 g from the USA	The incidence of ROP was 68% among PTI < 1251 g. The overall incidences of ROP were like the Cryotherapy for Retinopathy of Prematurity (CRYO-ROP) Study but there was more zone I ROP. Among PTI with ROP, more severe (pre-threshold) ROP occurred in 36.9% of PTI	[24]
Classify <i>risk factors</i> according to their contribution to the development or progression of ROP	Retrospective study (2010 to 2015) 324 PTI with GA < 32 wk or BW < 1501 g in Seoul	The incidence of ROP was 48.5%. Severe ROP occurred in 14.8% of all eyes and in 30.6% of eyes with ROP. Risk factors that regulate the development of ROP versus the progression of ROP were not identical	[15]
To find the incidence, beginning, and initial course of ROP in a representative cohort of PTI undergoing ROP screening	Retrospective study (2006 to 2011) 7483 PTI from 29 hospitals in the USA and Canada that performed serial ROP examinations	The incidence of ROP was 43.1%. Of all PTI, 12.4% developed severe ROP and 6.9% developed ROP requiring treatment. 98.1% of severe ROP cases occurred in PTI with a BW inferior to 1251 g	[16]
Analyze zygosity data from 63 monozygotic and 137 dizygotic twin pairs to estimate and determine <i>genetic susceptibility</i> to ROP	Retrospective study (1994 to 2004) 400 PTI with GA ≤ 32 wk from Sweden and the USA	70.1% of the variance in liability for ROP was due to genetic factors. In the mixed effects logistic regression analysis, the GA and the duration of supplemental oxygen were shown to be significant covariates for ROP	[91]
Analyze <i>genetic susceptibility</i> and the influence of different <i>environmental risk factors</i> on ROP development	Retrospective study (2000 to 2014) 257 PTI with GA ≤ 32 wk from Spain	Genetic factors accounted for 72.8% of the variability in the ROP stage, environmental risk factors 23.08%, and random factors 4.12%. The environmental variables associated with increased risk of ROP were number of days of tracheal intubation, postnatal weight gain, and development of sepsis	[92]
Find prenatal and perinatal <i>risk factors</i> for severe retinopathy (stage 3 or 4) ROP	Prospective study (1998 to 1999) 2105 PTI with GA < 32 wk or BW < 1500 g from Australia or New Zealand	The incidence of severe ROP showed differences according to maternal ethnicity. This study also confirmed that prematurity is the most important risk factor for ROP and identified low BW for GA and male gender as significant risk factors	[96]
Identify <i>risk factors</i> for ROP requiring treatment	Retrospective study (1997 to 2008) 6490 PTI with GA < 32 wk from Denmark	Male gender was a statistically independent risk factor for ROP requiring treatment. New statistically independent risk factors for ROP requiring treatment were blood transfusion and mechanical ventilation	[108]

Table 1 (continued)

Clinical studies	Study design and participants	Findings	References
Objectives			
Determine <i>predictive factors</i> for ROP requiring referral in the telemedicine approach	Multicenter retrospective study (2011 to 2013) 979 PTI with BW < 1251 g from the USA	When controlling for prematurity and very low body weight, the presence of stage 2 ROP, pre-plus disease, retinal hemorrhage, and the need for ventilation at the time of the first study-related ophthalmological observation were strong independent predictors for ROP requiring referral in the telemedicine approach. Male gender was an independent predictor for ROP requiring referral in the telemedicine approach	[107]
Determine <i>the incidence of ROP</i> in the state of New York	Retrospective study (1996 to 2000) 15,691 Newborn infants with initial length of stay > 28 days in a New York hospital	In the New York state, the overall incidence of any ROP among all newborn infants was 0.2%. In the study population of newborn infants with initial length of stay > 28 days, the incidence of any ROP was 20.3% among newborns with a BW < 1500 g and 27.3% among newborns with a BW < 1200 g. The probability of ROP development was 24% lower in African American patients compared to newborns of other races, controlling for all other variables. Male gender or Hispanic ethnicity did not show a statistically significant association with the development of ROP	[111]
Experimental studies			
Objectives			
Investigate the incidence and severity of neovascularization in <i>Brown Norway and Sprague Dawley rats in OIR</i> and acidosis-induced retinopathy model for ROP	Study design 110 Brown Norway rats and 110 Sprague Dawley rats OIR model: 20 newborn Sprague Dawley rats and 20 newborn Brown Norway rats were submitted to OIR. 10 newborn SD rats and 10 newborn BN rats for control group Acidosis-induced retinopathy model: A first set of 40 newborn Sprague Dawley rats and 40 newborn Brown Norway rats were submitted to acidosis-induced retinopathy model. 20 newborn Sprague Dawley rats and 20 newborn Brown Norway rats for control group. A second set of 20 newborn Sprague Dawley rats and 20 newborn Brown Norway rats were submitted to acidosis-induced retinopathy model	The incidence and severity of neovascularization in OIR were significantly higher in Brown Norway than in Sprague Dawley rats. The findings in acidosis-induced retinopathy model were limited. In OIR, the greatest severity of neovascularization was associated with increased retinal VEGF mRNA in Brown Norway OIR rats	[94]
Examine the <i>susceptibilities of different strains of rats</i> to OIR	Six strains of rats were exposed to OIR	Marked and consistent differences regarding retinal vascularization and abnormalities in vascular morphology were observed in the response of different strains of inbred rats to cyclic hyperoxia, suggestive of a genetic component of OIR	[93]

Table 1 (continued)

Objectives	Study design	Findings	References
Investigate the role of <i>HIF-2</i> $\alpha$ in pathological angiogenesis in mice	A targeting vector of the <i>HIF-2</i> $\alpha$ ( <i>HIF-1</i> $\alpha$ -like factor) gene was designed. <i>HIF-2</i> $\alpha$ -knockout mice and wild-type mice were submitted to hyperoxia–normoxia treatment, used as a murine model of ROP	Hyperoxia–normoxia treatment induced neovascularization in wild-type mice, but not in <i>HIF-2</i> $\alpha$ -knockout mice. Removal of the inserted gene restored normal <i>HIF-2</i> $\alpha$ expression and retinal neovascularization. In parallel with <i>HIF-2</i> , <i>EPO</i> gene expression was significantly affected	[151]
To determine whether the <i>retinal renin-angiotensin</i> and <i>VEGF</i> systems affect vessel growth and whether agents that disrupt the renin–angiotensin system can prevent neovascularization related to retinal hypoxia in a rat model of ROP	In a model of ROP, the angiotensin-converting enzyme inhibitor lisinopril and the angiotensin type 1 receptor antagonist losartan were administered during the neovascularization period to neonatal transgenic ( <i>mRen-2</i> ) 27 rats that overexpress renin in tissues, and to Sprague Dawley rats	Retinal renin levels were higher with lisinopril and losartan and both prevented the growth of inner retinal blood vessels. In rats with ROP, the expression of <i>VEGF</i> and its type 2 receptor in proliferating blood vessels and in the inner retina were increased. Lisinopril reduced retinal <i>VEGF</i> and its type 2 receptor mRNA, whereas losartan had no effect	[172]
Assess the development of vascular dilation and tortuosity in the OIR mouse and analyze how targeted deletions of <i>ADAM</i> family members (A disintegrin and metalloproteinase) or intravitreal injection of bevacizumab influence the development of plus disease	Wild-type and <i>Adam</i> -knockout mice were exposed to OIR. Fundus imaging and fluorescein angiography were then analyzed	After exposure to OIR, wild-type and <i>Adam</i> -knockout mice developed retinal arterial tortuosity and venous dilation, two hallmarks of plus disease. The severity of plus disease correlates with increased proliferation of endothelial cells. Mice lacking <i>Adam10</i> in endothelial cells and <i>Adam8</i> <sup>-/-</sup> and <i>Adam9</i> <sup>-/-</sup> mice developed relatively less plus disease compared to controls	[179]
Determine how <i>ADAM17</i> inactivation in EC or in pericytes influence pathological retinal neovascularization, developmental angiogenesis, and heterotopic tumor growth	Mice lacking <i>ADAM17</i> in EC ( <i>Adam17</i> <i>lox/lox/Tie2-Cre</i> mice) and mice lacking <i>ADAM17</i> in smooth muscle cells and pericytes ( <i>Adam17</i> <i>lox/lox/</i> $\alpha$ <i>isma-Cre</i> mice) were exposed to OIR	<i>ADAM17</i> inactivation did not affect developmental angiogenesis in any of the conditional knockout strains; however, pathological retinal neovascularization was decreased in <i>Adam17</i> <i>lox/lox/Tie2-Cre</i> mice, but not in <i>Adam17</i> <i>lox/lox/</i> $\alpha$ <i>isma-Cre</i> mice. Lack of <i>ADAM17</i> in EC decreased ex vivo tube formation, and this can be restored by addition of <i>ADAM17</i> HB-EGF substrate. It was also noted that <i>ADAM17</i> is important for stimulating the response to <i>VEGF-A</i> in various receptors with known functions in endothelial cell biology	[178]

*ADAM* “A” disintegrin and metalloproteinase; *BW* birth weight; *EC* endothelial cells; *EPO* erythropoietin; *GA* gestational age; *HIF* Hypoxia-inducible factor; *IGF-1* insulin-like growth factor 1; *OIR* oxygen-induced retinopathy; *PTI* preterm infants; *Wk* weeks

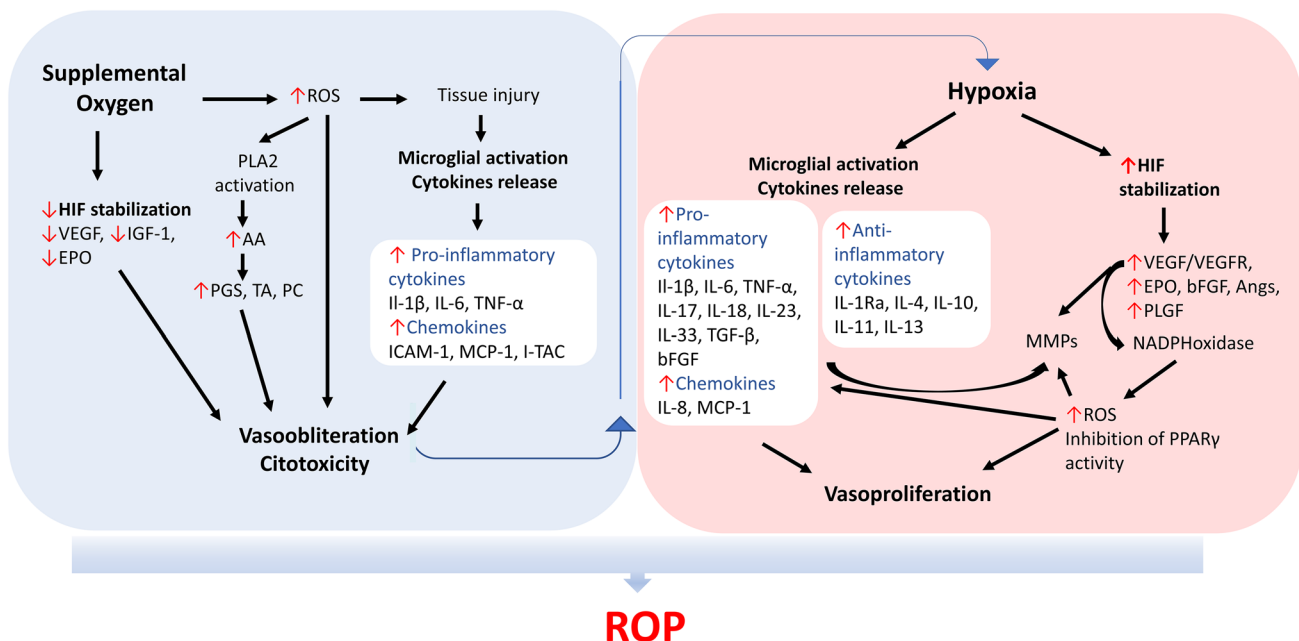
## Cytokines

Cytokines are intercellular signaling polypeptides released by activated immune cells that are produced during inflammatory processes and in which they participate [42]. There is an overlap in molecular signaling between oxidative and inflammatory compounds, in which complex networks of signaling pathways link oxidative agents and pro-inflammatory cytokines [43] (Fig. 2). The vascular damage of the ischemic phase of proliferative retinopathies is followed by an inflammatory response with the production of pro-inflammatory cytokines, which cause an increase in vascular permeability, immune and other cells recruitment, activation and differentiation, apoptosis, and angiogenesis [44].

Angiogenesis is strongly orchestrated by a variety of angiogenic cytokines, such as vascular endothelial growth factor

(VEGF), basic fibroblast growth factor (bFGF), transforming growth factor beta (TGF- $\beta$ ), and interleukin (IL)-1 $\beta$  [45, 46], and anti-angiogenic cytokines [46]. These cytokines contribute to the proliferation and migration of endothelial cells (EC), which is considered the hallmark of angiogenesis [46, 47].

One study reported significant correlations between levels of different cytokines in the first 3 weeks after birth and ROP development [48]. In an OIR model, the investigation of 94 selected genes known to be related to inflammation showed that many of them were upregulated in association with the clinical appearance of OIR [49]. The same authors analyzed the vitreous levels of 27 cytokines in PTI with stage 4 ROP and found higher levels of interleukin (IL) -6, IL-7, IL-10, IL-15, Eotaxin, bFGF, Granulocyte



**Fig. 2** Role of oxidative stress and inflammation in the pathogenesis of ROP. After preterm birth, premature infants are exposed to an excess of supplemental oxygen, leading to retinal vascular obliteration due to suppression of pro-angiogenic factors regulated by oxygen, oxidant stress, and excessive production of pro-inflammatory factors by damaged tissues. The vascular dropout results in hypoxia and HIF stabilization with subsequent production of growth factors. The microenvironment of retinal ischemia is characterized by microglial activation and release of many pro-inflammatory cytokines and chemokines, which cause pathological vasoproliferation. The major pro-inflammatory cytokines responsible for early responses are IL-1 $\beta$ , IL-6, and TNF- $\alpha$ . Other pro-inflammatory mediators include IL-17, IL-18, IL-23, IL-33, TGF- $\beta$ , bFGF, and a variety of other cytokines and chemokines. These cytokines upregulate the synthesis of secondary inflammatory mediators and pro-inflammatory cytokines. IL-6 and TGF- $\beta$  act as either pro-inflammatory or anti-inflammatory cytokines, under various circumstances. Proangiogenic cytokines, such as IL-1, TNF- $\alpha$ , and VEGF, directly or indirectly stimulate endothelial cells proliferation, migration, and tube formation. IL-1Ra,

IL-4, IL-10, IL-11, and IL-13 are major anti-inflammatory cytokines. Except for IL-1Ra, anti-inflammatory cytokines also have at least some pro-inflammatory properties. In ischemic areas, the enhanced production of ROS can further increase the level of pro-inflammatory cytokines. ECM degradation by MMPs activated by inflammatory cytokines, growth factors, and ROS, as well as proteolytic enzymes released from MFs allows EC migration and growth factors recruitment to form new capillaries. AA arachidonic acid; ANGs angiopoietins; bFGF basic fibroblast growth factor; ECM extracellular matrix; EPO erythropoietin; ICAM-1 intercellular adhesion molecule-1; IGF-1 insulin-like growth factor 1; IL Interleukin; IL-1Ra Interleukin 1 receptor antagonist; I-TAC Interferon-inducible T-cell alpha chemoattractant; MCP-1 monocyte chemotactic protein 1; MMPs matrix metalloproteinases; PC prostacyclin; PGs prostaglandins; PLA2 phospholipase A2; PLGF placental growth factor; PPAR $\gamma$  proliferator-activated receptor gamma; ROS reactive oxygen species; TGF- $\beta$  transforming growth factor beta; TA thromboxane; TNF- $\alpha$  Tumor necrosis factor alpha; VEGF vascular endothelial growth factor; VEGFR vascular endothelial growth factor receptor

colony-stimulating factor (G-CSF), interferon-gamma-inducible protein (IP) -10, and mainly, VEGF [50].

Molecules of the IL-1 family acting as the first line of defense against invasive pathogenic microorganisms and physical damage play an important role in inflammatory and immune responses. However, many cytokines in the IL-1 family, such as IL-1 $\alpha$ , IL-1 $\beta$ , IL-18, IL-33, and IL-37, contribute significantly to angiogenesis [46, 51]. IL-1 $\beta$ , an important mediator of inflammation [46, 47], in ischemic conditions of the retina is markedly increased in recruited neutrophils, EC, and retinal glial cells [52, 53] and has been implicated in the development of vasoproliferative retinopathies [53]. It has been suggested that in the hypoxic neonatal retina, activated microglial cells produce increased amounts of IL-1 $\beta$  and tumor necrosis factor alpha (TNF- $\alpha$ ) that can induce retinal ganglion cell death [54]. TNF- $\alpha$  is also known to contribute to the breakdown of the blood–retinal barrier [54, 55].

In an OIR model, it was shown that retinal microglia is induced to produce IL-1 $\beta$ , leading to microvascular injury by the release of semaphorin 3A (Sema3A) from adjacent neurons [53]. Inhibition of the IL-1  $\beta$  receptor prevented microglial activation and Sema3A expression in the retina, resulting in a significant decrease in vaso-obliteration and in the subsequent pathological pre-retinal neovascularization [53]. In another OIR model, inhibition of the IL-1  $\beta$  receptor preserved the choroid and prevented external neuroretinal abnormalities, suggesting IL-1  $\beta$  as a potential therapeutic target in ROP [56].

A mouse model of premature birth, in which chorioamnionitis was induced with an injection of IL-1 $\beta$  in utero, revealed that IL-1 $\beta$  causes sustained eye inflammation accompanied by delayed development of the retinal BV and thinning of the choroid, with all deleterious effects being prevented by antenatal administration of IL-1 receptor antagonist (IL-1Ra) [57]. However, in a study with preterm infants (PTI), the levels of IL-1 $\beta$  in the vitreous were identical and below detectable levels in patients with ROP and in control patients [50].

Cytokines have pro- and anti-inflammatory properties and regulate the human immune response acting in conjunction with specific cytokine inhibitors and soluble cytokine receptors [58]. IL-1Ra, IL-4, IL-10, IL-11, and IL-13 are considered anti-inflammatory cytokines [58].

The IL-1Ra was found at significantly elevated levels in the vitreous and tears of PTI with ROP, along with increased levels of VEGF, complement component proteins, and metalloproteinase 9 [59], possibly as a compensatory mechanism to prevent angiogenic effects of IL-18 and IL-1 $\beta$  [60].

In vitro, the inflammatory response induced in microglial cells was markedly reduced by IL-10 which inhibited the expression of TNF- $\alpha$ , MIP-1 $\alpha$ , and regulated on activation,

normal T cell expressed and secreted (RANTES) [61]. However, in an OIR mouse model, hypoxia guided the behavior of the macrophage to a pro-angiogenic phenotype via IL-10-activated pathways, implicating IL-10 in promoting pathological angiogenesis [62].

IL-38 is a novel cytokine from the IL-1 family that shares high-sequence homology with IL-1Ra [46, 63] and lower homology with IL-1 $\beta$  and other IL-1 family proteins [46]. A recent study in the OIR mice found that administration of IL-38 may help prevent pathogenic neovascularization and inflammation, suggesting that IL-38 is an anti-angiogenic cytokine and may have therapeutic potential for angiogenesis-related diseases [46].

IL-18 is a pleiotropic pro-inflammatory cytokine with an immunoregulatory activity [48]. Studies have suggested that the association of IL-18 with ROP may be as an immunoregulator and modulator of angiogenesis [48], promoting the regression of pathological neovascularization instead of inhibiting its development [64]. IL-6 is known to be a strong inducer of the acute-phase protein response; however, it has both pro-inflammatory and anti-inflammatory properties [58]. Twenty-four hours after birth, elevated levels of IL-6 and TNF- $\alpha$  were observed in PTI who subsequently needed treatment for ROP [65].

Tetrahydrobiopterin (BH4) is a crucial cofactor in several metabolic processes, with a fundamental role in maintaining inflammatory and neurovascular homeostasis [66]. A deficiency in BH4 can produce the uncoupling of endothelial nitric oxide synthase (eNOS), causing a reduction in nitric oxide bioavailability and increased ROS production [66, 67]. BH4 is involved in retinal vascular damage induced by oxygen due to its reduction caused by hyperoxia, which can result in decreased eNOS activity and increased superoxide [66, 68].

## Chemokines

Chemokines are a family of low-molecular weight peptides that induce the activation and migration of specific cells, especially immune cells, such as leukocytes and microglia, and are involved in the inflammatory responses [69, 70]. The participation of chemokines in angiogenesis, growth control, and hematopoiesis has also been demonstrated [69].

IL-8, the first chemokine to be characterized, plays important roles in both eye inflammation and pathological neovascularization [71]. In a study involving PTI with early-onset clinical sepsis, elevated plasma levels of IL-8 in the first days of life were associated with later development of ROP requiring treatment [72]. In another study, high concentrations of IL-8 during the first three weeks after premature birth were associated with an increased risk for pre-threshold ROP [73]. According to these results, in an OIR rat model,

an increased level of an IL-8 homolog was observed during the peak of pathological neovascularization [69].

Monocyte chemoattractant protein 1 (MCP-1), one of the most produced and transitory chemokines during inflammation [74], is expressed by activated microglia of the neuroretina and simultaneously an attraction factor for various cells of the immune system, including macrophages/microglia [75]. MCP-1 was found to be significantly increased in umbilical cord blood from PTI who developed ROP compared to PTI who did not develop ROP [76].

Low concentrations of the chemokine RANTES in the blood [48, 77] and vitreous [50] have been found in PTI who have developed severe ROP, suggesting that RANTES may play a protective role. In agreement, high concentrations of RANTES have been associated with a lower risk of ROP [73].

The current modulation of well-known angiogenic cytokines such as anti-VEGF therapy demonstrated efficacy in ocular neovascularization [46, 78]. However, some patients are refractory to anti-VEGF agents, suggesting that other angiogenic or anti-angiogenic cytokines that contribute in a coordinated manner to angiogenesis need to be identified [46, 51].

## Microglia

Microglia cells, the retinal-resident macrophages that provide neuroprotection against transient pathophysiological insults and play an important role in neuronal homeostasis, under sustained pathological stimuli become overactivated and release exaggerated amounts of inflammatory mediators that may promote tissue damage [79]. IL-1 $\beta$ , IL-6, TNF- $\alpha$ , interferon-gamma (IFN- $\gamma$ ), and TGF- $\beta$  are produced by a variety of cell types, being macrophages and monocytes the most important sources at inflammatory sites [42].

The macrophage population residing in many tissues is mainly derived from the yolk sac and fetal liver; however, after tissue injury, inflammatory monocytes recruited from the bone marrow complement it [80, 81]. Recent studies have indicated that macrophages play different roles in the process of intraocular neovascularization (Fig. 3) [82]. Macrophages can be divided into at least two main phenotypes with different functions: pro-inflammatory M1 macrophages and anti-inflammatory M2 macrophages with a major role in resolving inflammation [82, 83]. After tissue hypoxia, it has been proved that cytokines are involved in the recruitment of monocytes and polarization of macrophages, as well as in angiogenesis [82, 84]. The inflammatory microenvironment leads the macrophages to M1 polarization in an initial phase [85]. The change in the microenvironment in the late inflammatory phase drives macrophages toward the M2 polarization [85].

The M1 phenotype can be polarized by lipopolysaccharide and IFN- $\gamma$ , while other cytokines such as IL-4, IL-10, and IL-13 can induce M2 polarization [82, 86]. In the hypoxic microenvironment, it has been suggested that MCP-1 may play a role in the recruitment of monocytes to the vitreous and retina [82].

It is also increasingly clear that epigenetic modifiers can regulate the fate of macrophages [87]. Differentiation toward M1 or M2 polarization and inflammation *in situ* are regulated by defined microRNAs subsets [85, 88].

M1 macrophages are seen as phagocytic and pro-inflammatory, secreting large amounts of pro-inflammatory cytokines, such as IL-1 $\beta$ , IL-23, and proteases, reactive nitrogen and oxygen intermediates, and little amount of anti-inflammatory IL-10 [85].

M2 macrophages, instead of M1, have been reported to increase angiogenesis *in vivo* and highly express bFGF, insulin-like growth factor 1 (IGF-1), placental growth factor (PLGF), and MCP-1 [82, 83]. In the OIR model, the M2 phenotype was concentrated around neovascular tufts, promoting the development of retinal neovascularization [89].

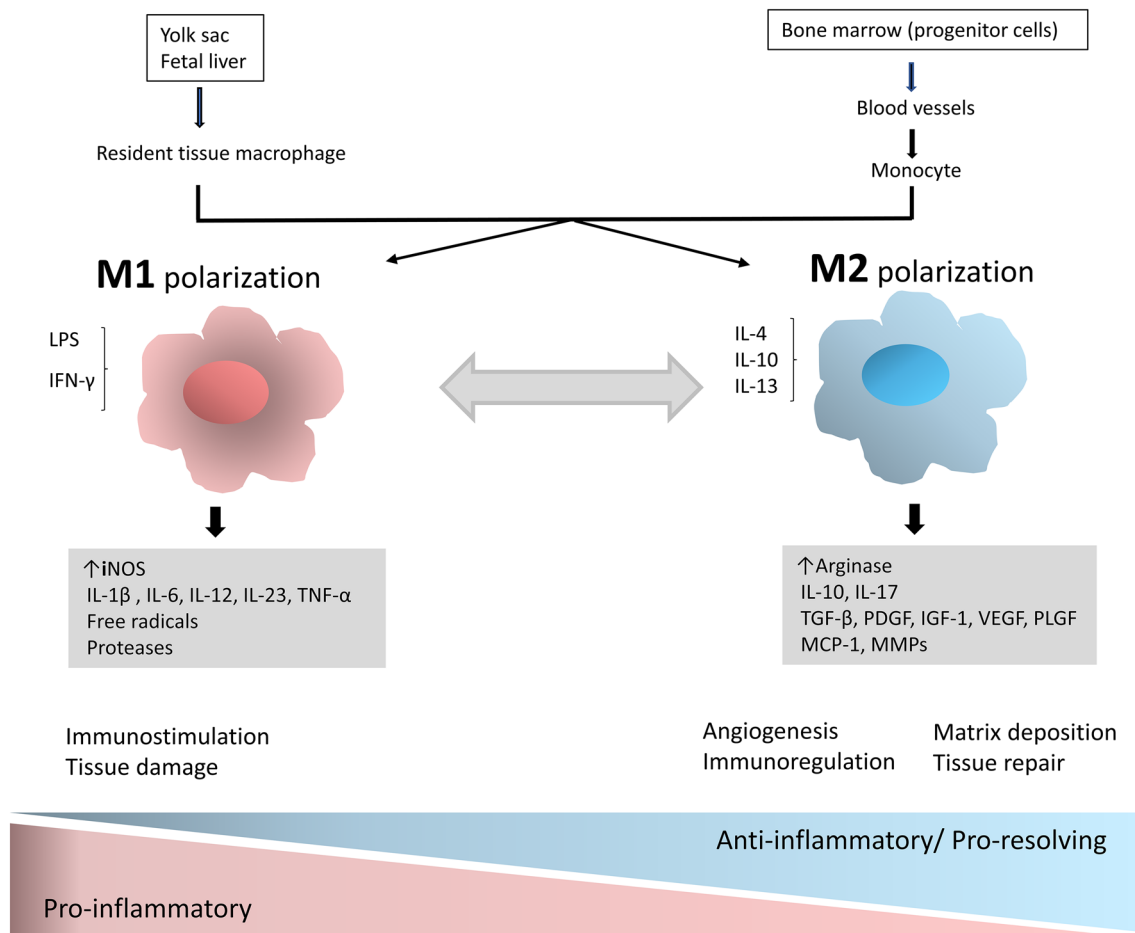
Specific molecular targets associated with macrophages can be considered as a potential treatment in the future for retinal neovascularization; however, further studies are needed [82].

## Genetic contribution

There is growing evidence that ROP is influenced by genetic predisposition, epigenetic regulation, and environmental factors [35, 90]. The fact that PTI of the same gestational age (GA) and exposed to identical environmental risk factors can develop ROP characterized by different degrees of severity strongly supports a genetic contribution to the etiopathogenesis of ROP [36, 37]. A study concluded that in PTI with extreme phenotypes, the known clinical risk factors were not significantly associated with the development of ROP, suggesting that other clinical, maternal, or genetic factors may predispose or protect from ROP [2].

The evidence of a genetic influence in ROP also comes from two studies with monozygotic and dizygotic twins that obtained an estimated heritability for ROP of 70% and 73%, respectively [91, 92] (Table 1).

In animal models of OIR, studies of different strains of rats observed differences in the avascular area of the retina and the expression of VEGF between the strains, these phenotypic differences also support the influence of a genetic factor [93, 94].



**Fig. 3** Mechanisms that influence the main macrophage polarization phenotypes and response to its activation. After injury, resident and recruited macrophages experience remarkable phenotypic and functional variations in response to mediators released into the tissue microenvironment. The dominant phenotype regulates inflammation and tissue repair and may play an active role in the development or inhibition of retinal neovascularization in the OIR model. Cytokines are involved in pathogenesis, monocyte recruitment, and macrophage

polarization and therefore are also key factors in the regulation of angiogenesis. *IGF-1* insulin-like growth factor 1; *IL* Interleukin; *IFN-γ* interferon-gamma; *iNOS* inducible nitric oxide synthase; *LPS* lipopolysaccharide; *MCP-1* monocyte chemotactic protein 1; *MMPs* matrix metalloproteinases; *OIR* oxygen-induced retinopathy; *PDGF* Platelet-derived growth factor; *PLGF* placental growth factor; *TGF-β* transforming growth factor beta; *TNF-α* Tumor necrosis factor alpha; *VEGF* vascular endothelial growth factor

### Epidemiological data and the role of $\beta$ -adrenergic receptor

The influence of a genetic component in the disease was initially based on racial and regional risk profiles resulting from epidemiological studies [95, 96]. The CRYO-ROP study found that although ROP occurred with similar incidence rates in the Caucasian and black populations, severe ROP was less common in black PTI [95, 97]. This result was found in other later studies [2, 98], although one study found an opposite result, a higher incidence of ROP requiring treatment in black PTI than in Caucasian PTI [99]. Studies have found a higher risk of ROP in Asians and Alaskan natives than in Caucasians [100, 101]. One mechanism to explain some of the racial differences observed in ROP is

polymorphisms of the  $\beta$ -blocker receptor. A polymorphism of the G protein-coupled 5 kinase receptor desensitizes  $\beta$ -adrenergic receptors causing resistance to noradrenergic stimuli. Retinal EC have  $\beta$ -adrenergic receptors and this theory of polymorphism is reinforced by reports showing an association of cutaneous hemangiomas with ROP, indicating possible common pathogenesis [102]. Cutaneous hemangiomas show a profound reduction with systemic  $\beta$ -blocker treatment [103, 104] and a  $\beta$ -blocker in eye drops, propranolol 0.2%, reduced the progression of ROP in a recent multicenter clinical trial, being promising in the treatment of ROP [105].

Some studies have reported that the incidence of ROP [106] or progression to severe stages [98, 107–109] is more frequent in males than in females. However, in other studies,

no difference was observed in the incidence of ROP by gender [110, 111].

### Wnt pathway

There are several studies on genetic polymorphisms in genes of the canonical Wnt pathway (dependent on beta-catenin) in ROP (Table 2). Variants of genes in the Wnt pathway cause familial exudative vitreoretinopathy (FEVR) or Norrie disease, which are diseases of the retinal development with characteristics similar to ROP although occurring in full-term infants [36, 90, 112]. Both of these diseases are hereditary disorders and have in common dysgenesis of the retinal vessels with a variable breakdown of the blood–retinal barrier, often leading to exudative and tractional retinal detachment [112, 113]. Molecular genetic studies have identified four genes that cause FEVR (NDP, FZD4, LRP5, and TSPAN12), which when mutated cause X-linked, AD, and AR FEVR (also some sporadic cases) [36]. Norrie disease results from mutations in the NDP gene [114].

Several studies correlate variants in genes of the Wnt pathway associated with FEVR or Norrie disease with an increased risk of severe ROP, suggesting involvement of genes associated with the Wnt pathway at least in a low portion of patients with severe ROP [36, 112, 115]. An important limitation of these results is the difficulty in distinguishing between PTI with severe ROP and PTI with FEVR [36]. Due to overlapping phenotypes, ROP is generally differentiated from FEVR by premature birth and lack of family history [112]. However, an ambiguous birth history can confuse the diagnosis [112] and some authors proposed the designation of ROPER (ROP vs. FEVR) to more accurately classify these patients [116].

### Vascular endothelial growth factor

VEGF-A plays a key role in physiological and pathological angiogenesis [117, 118]. Studies had implicated VEGF and VEGF receptor (VEGFR)-2 in ROP development [119] and the VEGFA-VEGFR system is the main target for anti-angiogenic treatment [120].

In two studies of the *VEGFA* -634 polymorphism, the G allele had a higher frequency between PTI with ROP [121, 122]. However, another study reported a higher frequency of C allele in severe ROP [123] and other studies have not confirmed an association between this polymorphism and ROP [124, 125].

*VEGFA* gene –460C > T and +13553C > T polymorphisms have also been associated with ROP [123, 126]. Although –460C > T has been included in other studies, it was not associated with ROP [125, 127].

The frequency of polymorphisms in the VEGFR-1 and -2 genes did not affect the development of ROP in two studies [125, 126].

### Nitric oxide and endothelial nitric oxide synthase

The isoform of nitric oxide-producing enzymes fairly specific for EC, eNOS, has been found to play a notable role in angiogenesis and vasculogenesis [128, 129]. Functional polymorphisms of the *eNOS* gene affect the expression of eNOS [129] and have been reported to be associated with cardiovascular diseases [130] and diabetic retinopathy in type 1 diabetes [129, 131].

ROP was associated with single-nucleotide polymorphisms (SNPs) of the *eNOS* gene (T-786C [132, 133] and G894T [132]), but these results have not been replicated in other studies [129, 134].

### Neurotrophins and serotonin

Neurotrophins (NTs) are members of a family of polypeptide growth factors that control several aspects related to the survival, differentiation, and function of neurons in the central and peripheral nervous systems and with important functions in non-neuronal cells [135, 136]. NTs family includes nerve growth factor (NGF), brain-derived neurotrophic factor (BDNF), neurotrophin-3 (NT-3), and neurotrophin-4/5 (NT-4/5) [137].

NTs bind to tropomyosin kinase (Trk) receptors, NGF with high affinity for TrkA receptor, BDNF for TrkB receptor, and NT-3 for TrkC, resulting in activation of signaling pathways, namely phosphatidylinositol 3-kinase (PI3K)/protein kinase B (AKT), mitogen-activated protein kinase (MAPK)/extracellular-signal-regulated kinase (ERK), and phospholipase C gamma (PLC $\gamma$ )/protein kinase C (PKC) [138]. BDNF and NGF have been described as playing an important role in the process of angiogenesis [137]. In different cell models, both NGF and BDNF promote the proliferation, migration, differentiation, and survival of EC [139, 140]. Moreover, both have been shown to induce VEGF expression, thus also having an indirect angiogenic role [141, 142].

Studies have associated lower-serum BDNF concentrations in the first week of life in PTI with the development of severe ROP [48]. A large-scale study of candidate genes in a cohort of PTI found SNPs (rs7934165 and rs2049046) in intronic regions of the *BDNF* gene associated with severe ROP [143]. This result supports the line of thought that neurovascular connections play a role in the development of ROP [144].

Different studies have shown a close relationship between BDNF and glial cell line-derived neurotrophic factor (GDNF) with the serotonergic system in brain development

**Table 2** Studies investigating genetic polymorphisms of candidate genes in ROP

Gene	Genetic Polymorphism/ rs or base change	Sample	Findings	References
<i>ANG2</i>	-35G>C	90 PTI with ROP requiring treatment (GA 28.5 ± 2.4 wk, BW 1160 ± 300 g), 110 PTI without ROP or with ROP stage 1 or 2 not requiring treatment (GA 30.1 ± 2.9 wk, BW 1200 ± 280 g) PTI with stage 4 or 5 ROP (GA 23–30 wk, BW 600–1300 g), normal adult controls (GA 34–40 wk, BW 2430–3960 g)	No significant association with ROP	[168]
<i>Angiotensin</i>	rs699	43 PTI with ROP, 299 PTI without ROP (PTI studied: GA 27.1 ± 1.8 wk, BW 915 ± 249 g)	No significant association with ROP	[134]
<i>Angiotensin-converting enzyme</i>	<i>Angiotensin-converting enzyme</i> gene insertion/deletion (I/D) polymorphism	53 PTI with spontaneously regressed ROP (mean GA 30.2 wk [25–32 wk], mean BW 1195 g [713–1500 g]), 21 PTI with stage 4 or 5 ROP (mean GA 30.1 wk [24–32 wk], mean BW 1165 g [700–1500 g]) 107 PTI without ROP (mean GA 30.5 wk [24–32 wk], mean BW 1210 g [710–1500 g])	A higher incidence of genotype II when ROP cases were analyzed collectively as a group. A significantly higher incidence of DD genotype in the stage 4 or 5 ROP compared to spontaneously regressed ROP cases	[173]
<i>Angiotensin receptor 1</i>	rs427832	1209 PTI: 341 PTI with DD genotype (mean GA 29 wk [22.9–36 wk], mean BW 1083 g [430–1495 g]), 624 PTI with DI genotype (mean GA 28.9 wk [23–35.9 wk], mean BW 1075 g [340–1495 g]), 244 PTI with II genotype (mean GA 28.8 wk [22.1–34.7 wk], mean BW 1065 g [410–1500 g])	No significant association with ROP	[174]
<i>BDNF</i>	rs5186 rs7934165, rs2049046	102 PTI with ROP (GA 26 ± 2 wk, BW 884 ± 337 g), 228 without ROP (GA 28 ± 2 wk, BW 1192 ± 389 g) 43 PTI with ROP, 299 PTI without ROP (PTI studied: GA 27.1 ± 1.8 wk, BW 915 ± 249 g) 126 PTI with ROP requiring treatment (GA 24.5 ± 1.2 wk, BW 697 ± 125.0 g), 467 PTI with ROP not requiring treatment (GA 25.7 ± 1.7 wk, BW 758 ± 133.0 g), 264 PTI without ROP (GA 27.1 ± 1.9 wk, BW 823.6 ± 126.0 g)	Associated with the development of ROP No significant association with ROP The two intronic single nucleotide polymorphisms (SNPs) were associated with threshold ROP	[152] [134] [143]
	rs7934165	140 PTI with ROP requiring treatment, 1257 PTI with ROP not requiring treatment or without ROP	A meta-analysis showed an association with severe ROP	[143]
<i>Complement factor H</i>	rs52985	102 PTI with ROP (GA 26 ± 2 wk, BW 884 ± 337G), 228 without ROP (GA 28 ± 2 wk, BW 1192 ± 389G)	An increment in the number of T alleles was associated with protection against ROP	[152]

Table 2 (continued)

Gene	Genetic Polymorphism/ rs or base change	Sample	Findings	References
<i>eNOS</i>	rs800292 rs2070744 (-786T>C)	102 PTI with ROP (GA 26±2 wk, BW 884±337G), 228 without ROP (GA 28±2 wk, BW 1192±389G) 19 PTI with stage 4/5 ROP, 34 full-term normal adult controls 15 PTI with ROP, 131 PTI without ROP	An increment in the number of T alleles was associated with protection against ROP The frequency of the C allele was significantly elevated in ROP The frequency of the C allele was significantly elevated in PTI with ROP	[152] [133] [132]
	rs1799983 (894G>T)	43 PTI with ROP, 299 PTI without ROP (PTI studied: GA 27.1±1.8 wk, BW 915±249 g) 105 PTI with ROP requiring treatment (GA 28.4±2.5 wk, BW 1150±360 g), 127 PTI with stage 1 or 2 ROP (GA 30.5±3.5 wk, BW 1300±400 g) 15 PTI with ROP, 131 PTI without ROP	No significant association with ROP No significant association with ROP The frequency of the T allele was significantly higher in PTI with ROP	[134] [129] [132]
<i>EPAS1</i>	rs1868085	43 PTI with ROP, 299 PTI without ROP (PTI studied: GA 27.1±1.8 wk, BW 915±249 g) 102 PTI with ROP (GA 26±2 wk, BW 884±337G), 228 without ROP (GA 28±2 wk, BW 1192±389 g)	No significant association with ROP The frequency of the A allele was significantly higher in PTI with ROP	[134] [152]
<i>FZD4 (Frizzled 4, Wnt pathway)</i>	c.97 C>T; c.502 C>T	93 ROP, 98 Full-term infants (controls)	c.97 C>T; c.502 C>T double missense mutation was present in 7 of 93 PTI with ROP (7.5%)	[112]
	c.205 C>T /rs80358282, c.380 G>A /rs184709254, c.313A>G* (exon 2), c.40_49del* (exon 1) rs3074372	53 advanced ROP (mean GA 25.1 [22–29 wk], mean BW 769.2 g [420–1244 g]) 9 atypical ROP cases (mean GA 33.78 wk [28–36 wk], mean BW 2324.44 g [1050–3500 g]) 43 PTI with ROP, 299 PTI without ROP (PTI studied: GA 27.1±1.8 wk, BW 915±249 g)	3 different nonsynonymous DNA variants in the coding region in 4 patients 1 nonsynonymous and 1 frameshift DNA variant in 2 patients No significant association with ROP	[180] [115] [134]
<i>HMOX-1</i>	rs3074372	43 PTI with ROP, 299 PTI without ROP (PTI studied: GA 27.1±1.8 wk, BW 915±249 g)	No significant association with ROP	[134]
<i>IGF-1 receptor</i>	c.3174G>A	108 PTI with ROP requiring treatment, 120 PTI with ROP stage 1 or 2 not requiring treatment, 164 full-term newborn controls	No significant association with ROP	[158]

Table 2 (continued)

Gene	Genetic Polymorphism/ rs or base change	Sample	Findings	References
<i>IL-1<math>\beta</math></i>	+ 3953C>T	52 PTI with stage 4 or 5 ROP (mean GA 26 wk [23–30 wk], mean BW 882 g [600–1300 g]), 33 full-term normal adult controls	No significant association with ROP	[157]
		31 PTI with stage 1 or 2 ROP (mean GA 28 wk [24–31 wk]), 13 PTI with stage 3 ROP (mean GA 24 wk [23–26 wk]), 29 PTI without ROP (mean GA 31 wk [28–31 wk])	No significant association with ROP	[169]
<i>IL-10</i>	– 1082G>A	31 PTI with stage 1 or 2 ROP (mean GA 28 wk [24–31 wk]), 13 PTI with stage 3 ROP (mean GA 24 wk [23–26 wk]), 29 PTI without ROP (mean GA 31 wk [28–31 wk])	No significant association with ROP	[169]
<i>LRP5</i> ( <i>LDL receptor related protein 5</i> , <i>Wnt pathway</i> )	rs143924910 (c.3656 G>A), c.4148 A>C, rs141407040 (c.4619 C>T/) c.2447A>C* (exon 11), c.2431A>G (exon 11), c.1434G>A (exon 7)	53 advanced ROP (mean GA 25.1 [22–29 wk], mean BW 769.2 g [420–1244 g]) 9 atypical ROP cases (mean GA 33.78 wk [28–36 wk], mean BW 2324.44 g [1050–3500 g])	3 different nonsynonymous DNA variants in the coding region in 3 patients 2 different nonsynonymous and 1 stop-gain DNA variants in 3 patients	[180] [115]
<i>NDP</i> ( <i>ND protein</i> , <i>Wnt pathway</i> )	Sequencing of all 3 exons and untranslated regions (UTR)	143 subjects of different ethnic backgrounds; 54 severe ROP (stage 3 or worse) (mean GA 25.5 wk [23–32 wk], mean BW 773 g [367–1440 g]), 36 mild or no ROP (mean GA 27.7 wk [24–34 wk], mean BW 968 g [650–1360 g]), 31 normal parents, 22 wild type (normal) controls	Genetic polymorphisms in the <i>NDP</i> gene were present in 6 of 54 (11%) PTI with severe ROP	[181]
	Direct sequencing of the coding regions and a noncoding exon c.181C>A* (exon 3), c.134 T>G* (exon 2), c.134 T>A* (exon 2)	53 advanced ROP (mean GA 25.1 [22–29 wk], mean BW 769.2 g [420–1244 g]) 9 atypical ROP cases (mean GA 33.78 wk [28–36 wk], mean BW 2324.44 g [1050–3500 g])	No sequence changes with pathogenic significance were identified 3 different nonsynonymous DNA variants in 3 patients	[180] [115]
	597C>A, 110C>G	95 PTI with ROP, 115 PTI without ROP (PTI studied: mean GA 30.7 wk [26–36 wk], mean BW 1267 g [800–1500 g])	The AA genotype of the 597C>A polymorphism was significantly associated with advanced ROP cases (83.3% compared to spontaneous ROP regression cases (0%) and the normal controls (10.4%) ( $p<0,0001$ ). No significant association between 110C>G polymorphism and ROP	[182]
	R121W, L108P	16 PTI with ROP (mean GA 26.2 wk [23–30 wk], mean BW 882 g [601–1500 g]), 50 unrelated healthy control subjects	Missense mutations (R121W and L108P) observed in four patients. No statistical analysis	[183]
<i>TSPAN12</i> ( <i>tetraspanin 1</i> , <i>Wnt pathway</i> )	Direct sequencing of the coding regions and a noncoding exon c.194C>T (exon 4)	53 advanced ROP (mean GA 25.1 [22–29 wk], mean BW 769.2 g [420–1244 g]) 9 atypical ROP cases (mean GA 33.78 wk [28–36 wk], mean BW 2324.44 g [1050–3500 g])	No sequence changes with pathogenic significance were identified 1 nonsynonymous DNA variant in 1 Chinese patient	[180] [115]

Table 2 (continued)

Gene	Genetic Polymorphism/ rs or base change	Sample	Findings	References
<i>VEGFA</i>	rs2010963 (- 634G > C, + 405G > C)	62 ROP (mean GA 32 wk [28–34 wk], mean BW 1400 g [1000–2110 g]), 40 no ROP PTI (mean GA 33 wk [29–35 wk], mean BW 1640 g [1009–2800 g])	G allele was significantly associated with ROP	[122]
		91 PTI with ROP requiring treatment (mean GA 25 wk [23–30 wk], mean BW 779 g [440–1185 g]), 97 PTI without ROP requiring treatment (mean GA 26 wk [23–32 wk], mean BW 920 g [448–2302 g])	G allele was more frequent in PTI with threshold ROP. Homozygotes for the G allele, related to increased VEGF production, were twice as likely to progress to threshold ROP	[121]
		86 PTI with ROP requiring treatment (GA 28.5 ± 2.0 wk, BW 1160 ± 300 g), 115 PTI without ROP requiring treatment (GA 29.2 ± 2.9 wk, BW 1200 ± 270 g)	Prevalence of C allele was higher in the treated PTI than in the untreated PTI (0.30 versus 0.41)	[123]
		42 PTI with ROP requiring treatment (BW 1097.5 ± 264.3 g, GA 28.2 ± 2.4 wk), 50 PTI with regressed ROP (BW 1253.0 ± 212.2 g, GA 29.7 ± 2.0 wk), 31 PTI without ROP (BW 1345.6 ± 225.9 g)	No significant association with ROP	[125]
		724 PTI with advanced ROP (stages 4 and 5) (BW 1349.31 ± 83.09 g, GA 30.12 ± 2.57), 878 PTI without ROP (BW 1360.38 ± 73.83 g, GA 31.14 ± 1.93 wk)	No significant association with ROP	[124]
	rs833061 (- 460C > T)	86 PTI with ROP requiring treatment (GA 28.5 ± 2.0 wk, BW 1160 ± 300 g), 115 PTI without ROP requiring treatment (GA 29.2 ± 2.9 wk, BW 1200 ± 270 g)	Higher prevalence of -460TT / +405CC haplotype in the treated PTI than in the untreated PTI (13 of 86 versus 1 of 115)	[123]
		42 PTI with ROP requiring treatment (BW 1097.5 ± 264.3 g, GA 28.2 ± 2.4 wk), 50 PTI with regressed ROP (BW 1253.0 ± 212.2 g, GA 29.7 ± 2.0 wk), 31 PTI without ROP (BW 1345.6 ± 225.9 g)	No significant association with ROP	[125]
		61 PTI with stage 4/5 ROP (mean BW 882 g [600–1300 g], mean GA 26 wk [23–30 wk]), 61 full-term normal adult controls (BW 2430–3960 g, GA 34–40 wk)	No significant association with ROP	[127]
	+ 13553C > T	127 PTI with ROP (mean BW 944 g [378–2168 g], mean GA 27 wk [22–33 wk]), 77 PTI without ROP (mean BW 1596 g [692–2400 g], mean GA 32 wk [28–34 wk])	The TT genotype was significantly associated with non-severe ROP	[126]

Table 2 (continued)

Gene	Genetic Polymorphism/ rs or base change	Sample	Findings	References
	rs3025039 (+936C>T)	62 ROP (mean GA 32 wk [28–34 wk], mean BW 1400 g [1000–2110 g]), 40 no ROP PTI (mean GA 33 wk [29–35 wk], mean BW 1640 g [1009–2800 g])	No significant association with ROP	[122]
<i>VEGFR-1 (Flt-1)</i>	c. +6724 (TG) 13–23 dinucleotide repeat	91 PTI with ROP requiring treatment (mean GA 25 wk [23–30 wk], mean BW 779 g [440–1185 g]), 97 PTI without ROP requiring treatment (mean GA 26 wk [23–32 wk], mean BW 920 g [448–2302 g])	No significant association with progression to threshold ROP	[121]
	c. +6724 (TG) 13–23 dinucleotide repeat	127 PTI with ROP (mean BW 944 g [378–2168 g], mean GA 27 wk [22–33 wk]), 77 PTI without ROP (mean BW 1596 g [692–2400 g], mean GA 32 wk [28–34 wk])	No significant association with ROP	[126]
<i>VEGFR-2 (KDR)</i>	+32 G>A	42 PTI with ROP requiring treatment (BW 1097.5 ± 264.3 g, GA 28.2 ± 2.4 wk), 50 PTI with regressed ROP (BW 1253.0 ± 212.2 g, GA 29.7 ± 2.0 wk), 31 PTI without ROP (BW 1345.6 ± 225.9 g)	No significant association with ROP	[125]
	g. +4422(AC) 11–14 dinucleotide repeat	127 PTI with ROP (mean BW 944 g [378–2168 g], mean GA 27 wk [22–33 wk]), 77 PTI without ROP (mean BW 1596 g [692–2400 g], mean GA 32 wk [28–34 wk])	No significant association with ROP	[126]
<i>Toll-like receptor-4 (TLR-4)</i>	Asp299Gly	31 PTI with stage 1 or 2 ROP (mean GA 28 wk [24–31 wk]), 13 PTI with stage 3 ROP (mean GA 24 wk [23–26 wk]), 29 PTI without ROP (mean GA 31 wk [28–31 wk])	No significant association with ROP	[169]
<i>TNF-α</i>	–308G>A	31 PTI with stage 1 or 2 ROP (mean GA 28 wk [24–31 wk]), 13 PTI with stage 3 ROP (mean GA 24 wk [23–26 wk]), 29 PTI without ROP (mean GA 31 wk [28–31 wk])	No significant association with ROP	[169]

ANG angiopoietin; *BDNF* brain-derived neurotrophic factor; *BW* birth weight; *eNOS* endothelial nitric oxide synthase; *EPAS1* endothelial PAS domain protein 1; *GA* gestational age; *HMOX-1* heme oxygenase 1; *IGF-1* insulin-like growth factor 1; *IL* interleukin; *ROP* retinopathy of prematurity; *TNF-α* tumor necrosis factor alpha; *VEGF* vascular endothelial growth factor; *VEGFR* vascular endothelial growth factor receptor; *Wk* weeks

and neuroplasticity [145, 146]. The synthesis and release of the neurotransmitter serotonin in the retina, and the existence of several types of serotonin receptors expressed in the retina, support its retinal neuromodulatory role [147]. Several data show that serotonin is implicated in retinal physiology and pathophysiology and photoreceptor survival; however, retinal signaling pathways activated by serotonin receptors have been little investigated to date [147].

### Hypoxia-inducible factor

Hypoxia-responsive genes, such as *VEGF* and *erythropoietin* (*EPO*), are regulated mainly through hypoxia-inducible factor (HIF) [148], a heterodimeric transcription factor consisting of two subunits, HIF-1-alpha (or HIF-2-alpha and HIF3-alpha, their analogs) and HIF1-beta (also known as ARNT) [149]. During hypoxia, the HIF-1 $\alpha$  level increases and it binds to HIF-1 $\beta$  in the nucleus to trigger the transcription of genes involved in angiogenesis and adaptation of cells to hypoxia [149].

Endothelial PAS Domain Protein 1 (EPAS1), also called HIF-2 $\alpha$ , has high homology to HIF-1 $\alpha$  and, like HIF-1 $\alpha$ , EPAS1 is stabilized during hypoxia and forms a heterodimer with the ARNT translocator and transactivates the VEGF promoter [150]. In addition, this heterodimer complex has also been shown to transactivate *Flt-1*, which encodes VEGFR-1 [150].

In a study with a hyperoxia/normoxia treatment, using a murine model of ROP, *HIF-2 $\alpha$* -knockdown mice showed no evidence of retinal neovascularization when compared to wild-type mice [151]. The expression of EPO mRNA was also significantly decreased when compared to control mice [151]. A candidate gene study in PTI found an association between *EPAS1* and the development of severe ROP [152]. It is possible that polymorphisms in the *EPAS1* gene in PTI predispose to increased expression of angiogenic factors, such as VEGF and EPO [152].

### Erythropoietin

EPO is an oxygen-regulated growth factor [44] and also an important angiogenic factor, its production being regulated by HIF [149]. EPO plays an important role in both the first and second phases of ROP [153]. A candidate gene study investigated the influence of an EPO polymorphism in the development of ROP, but no statistical significance was observed [152].

### Insulin-like growth factor 1

IGF-1 is a growth factor supplied by the placenta and amniotic fluid that is crucial for fetal development, including healthy retinal angiogenesis [153]. It has been reported that

it is also essential for postnatal vascular eye development and that a prolonged period of low levels of IGF-1 can predict the development of ROP and other diseases related to prematurity [154]. In patients with a genetic defect in the production of IGF-1, a reduction in retinal vascularization was observed, which has not been restored after the administration of IGF-1 [155].

Because the level of IGF-1 is determined by the IGF-1 receptor [156], it is possible that the most prevalent *IGF-1 receptor* polymorphism (c.3174G > A), which exhibits low levels of free plasma IGF-1, has a role in ROP [36]. However, the association of this polymorphism with the risk of advanced ROP has not been proven by studies in different populations [157, 158].

### Angiopoietins

Angiopoietins (ANGs) are growth factors that regulate physiological and pathological neovascularization, specifically in association with VEGF [159, 160]. Although ANG-1 and ANG-2 bind to the Tie2 tyrosine kinase receptor, ANG-2 is a functional ANG-1 antagonist [161, 162]. ANG-1 contributes to the maintenance of vascular integrity [163], while ANG-2 stimulates neovascularization [164] and is upregulated by VEGF and hypoxia [165, 166].

The influence of the ANG-2 (-35G > C) gene polymorphism on ROP was investigated in two studies; however, no significance was reported [167, 168].

### Mediators of immune and inflammatory response

Studies involving PTI have demonstrated the presence of multiple and complex associations of polymorphisms that occur in genes involved in the pro-inflammatory and pro-oxidant response with premature birth and the occurrence of SO diseases complicating prematurity [1, 23]

Regarding the association with ROP, one study suggested an increased risk of ROP progression with the presence of SNPs from the *IL-10*, *IL-1 $\beta$* , and *TNF- $\alpha$*  genes, without changing the risk with an SNP of the *Toll-like receptor-4* (*TLR-4*) gene, although none of these trends reached formal statistical significance [169].

### Heme oxygenase 1

Heme oxygenase 1 (HMOX-1) is an enzyme that breaks down heme into iron ions, carbon monoxide, and biliverdin [134]. HMOX-1 products perform important physiological functions in the vascular system, related to the protection of the endothelium through a cytoprotective, promitogenic, and anti-inflammatory action [170].

The effectiveness of this enzyme is affected by repeated polymorphisms in the HMOX-1 gene promoter [170].

Despite this, no significant association was found between HMOX-1 and ROP in a candidate gene study [134].

### Renin–angiotensin system

It has been shown that the renin–angiotensin system may influence the early stages of retinal vascularization [171] and retinal neovascularization was prevented by blocking the renin–angiotensin system in a rat model of ROP [172].

*Angiotensin-converting enzyme* gene polymorphism has been associated with ROP in the population of Kuwait [173], but not in another population [174].

A study of *Angiotensin* gene polymorphism found no association with ROP [134], while studies on the *angiotensin receptor 1* gene found an association with the development of ROP [152] or found no association [134].

### Matrix metalloproteinases

Matrix metalloproteinases (MMPs) are endopeptidases that hydrolyze the extracellular matrix (ECM) [175] and play an important role in inflammatory responses and angiogenesis among other various biological processes [176]. “A” disintegrin and metalloproteinase (ADAM) is also a family of enzymes involved in the degradation of components of the ECM [177].

Based on studies in animal models of OIR, some subtypes of the ADAM family have been suggested to be implicated in the ROP pathogenesis [178, 179]. Genetic studies in humans are needed to assess the influence of ECM, metalloproteinases, and the ADAM family on the pathogenesis of ROP.

### Other studies

Apart from the studies described involving factors related to the pathogenesis of ROP, a large study mentioned above identified candidate genes with an unknown relationship with ROP, such as the complement factor H gene [152].

From the above, several evidences suggest a genetic contribution to ROP; however, it is not yet clear which genes or genetic polymorphisms are significantly associated with the development and progression of ROP. Many of the ROP candidate gene studies have limitations, essentially small sample size, non-replicable, or conflicting results from several studies, the latter of which may be at least in part, due to differences in neonatal care and clinical characterization in different countries or populations. In some studies, it may also be difficult to separate the contribution of genetic factors associated with ROP from those associated with prematurity itself.

Epigenetic studies on ROP have not been found in the literature, which could be an important contribution to the emergence of new methods for the treatment of this

pathology. Future studies involving next-generation sequencing and genome-wide association, integrated with metabolomics and proteomics, may provide a better understanding of the genetic risk factors and pathophysiology of ROP and contribute to finding new solutions in the management and treatment of ROP.

### Expected clinical applicability of studies on genetics and inflammatory pathways in ROP

The search for biomarkers to detect PTI with increased risk of developing ROP allowed the identification of potential indicators involved in inflammatory and angiogenic pathways. Circulating and genetic biomarkers can be incorporated into models to predict the risk of developing ROP. A risk analysis system that includes biomarkers and clinical risk factors can help neonatologists and ophthalmologists identify high-risk PTI. This may allow the development of more adequate follow-up strategies depending on the risk level of the PTI and reduce the number of ROP screening tests for those at lower risk.

A better understanding of the genetic contribution to the pathogenesis of ROP may also help to find new targets that lead to the development of therapeutic approaches that are more effective and less harmful than current ones. In addition, knowledge of the influence of genetic polymorphisms on phenotypic biomarkers (biochemical and cellular) can contribute to defining the ROP phase and, thus, choosing the most appropriate therapeutic approach over time.

Furthermore, a deeper knowledge of the molecular and genetic mechanisms involved in ROP may help to better understand and treat other oxidative stress diseases associated with prematurity with which ROP shares etiopathogenic factors.

Many molecules and related signaling pathways suspected to be involved in the pathogenesis of ROP are common to other pediatric and adult ischemic retinopathies. Thus, a deeper comprehension of molecular mechanisms in ROP may provide important insights to other retinal neovascular pathologies.

### Conclusion

Several pieces of evidence suggest that the pathogenesis of ROP begins in utero. Perinatal inflammation and genetic factors may contribute to the development and progression of ROP.

Studies have implicated the involvement of factors linked to the inflammatory process, such as leukocytes, monocytes, macrophages, cytokines, chemokines, and growth factors, in

angiogenesis and pathological vascular development of ROP. Cytokines are also involved in monocyte recruitment and macrophage polarization. Macrophages may be recruited by long-term pathological neovascularization, but they can also promote pathological neovascularization.

Several studies have found genetic polymorphisms in candidate genes associated with ROP or severe ROP. Many pathways and their signaling molecules have been studied due to their connection with the pathogenesis of ROP. Associations were found between genes involved in the WNT signaling pathway, the *VEGFA* gene and the *eNOS* gene, and the development of ROP. A large multicenter study found polymorphisms in the *BDNF* gene associated with severe ROP.

Although multiple genes have been implicated in several investigations, a genetic component with a major impact on ROP has not yet been discovered. Several of these studies have not replicated findings mainly because of limitations in aspects such as sample size, non-replicable or conflicting results, and differences in neonatal care or inclusion criteria. The knowledge of such a genetic component would possibly allow the identification of possible targets to improve the screening and treatment of ROP.

New technologies involving bioinformatics, genomics, and proteomics may contribute to find genes or pathways associated with ROP and help in the future to find better solutions in the management and treatment of ROP.

**Acknowledgments** Special thanks to Ana Carolina Santos for her support in this work.

**Author contributions** The first draft of the manuscript was written by Mariza Fevereiro-Martins. Mariza Fevereiro-Martins and Manuel Bicho had the idea for the article. All authors commented on previous versions of the manuscript. All authors read and approved the final manuscript.

**Funding** This work was supported by the Laboratório de Genética and the Instituto de Saúde Ambiental (ISAMB) of the Faculdade de Medicina of Universidade de Lisboa and the Instituto de Investigação Científica Bento da Rocha Cabral. The writing of the manuscript was also supported by funds from Fundação para a Ciência e a Tecnologia to ISAMB (ref. UIDB/04295/2020 and UIDP/04295/2020).

**Data availability** Not applicable.

## Declarations

**Conflict of interest** The authors report no conflicts of interest.

## References

- Giusti B, Vestri A, Poggi C, Magi A, Pasquini E, Abbate R, Dani C (2012) Genetic polymorphisms of antioxidant enzymes as risk factors for oxidative stress-associated complications in preterm infants. *Free Radic Res* 46:1130–1139. <https://doi.org/10.3109/10715762.2012.692787>
- Port AD, Chan RVP, Ostmo S, Choi D, Chiang MF (2014) Risk factors for retinopathy of prematurity: insights from outlier infants. *Graefes Arch Clin Exp Ophthalmol* 252(10):1669–1677. <https://doi.org/10.1007/s00417-014-2716-1>
- Aydin H, Gunay M, Celik G, Gunay BO, Taka U, Karaman A (2016) Evaluation of Factor V Leiden, Prothrombin G20210A, MTHFR C677T and MTHFR A1298C gene polymorphisms in retinopathy of prematurity in a Turkish cohort. *Ophthalmic Genet* 37(4):415–418. <https://doi.org/10.3109/13816810.2015.1126611>
- Jang JH, Kim YC (2020) Retinal vascular development in an immature retina at 33–34 weeks postmenstrual age predicts retinopathy of prematurity. *Sci Rep* 10(1):18111. <https://doi.org/10.1038/s41598-020-75151-0>
- Smith LEH (2004) Pathogenesis of retinopathy of prematurity. *Growth Horm IGF Res*. <https://doi.org/10.1016/j.ghir.2004.03.030>
- Liu CH, Wang Z, Sun Y, Chen J (2017) Animal models of ocular angiogenesis: from development to pathologies. *FASEB J* 31(11):4665–4681. <https://doi.org/10.1096/fj.201700336R>
- Suwanpradid J, Rojas M, Behzadian MA, Caldwell RW, Caldwell RB (2014) Arginase 2 deficiency prevents oxidative stress and limits hyperoxia-induced retinal vascular degeneration. *PLoS ONE* 9(11):e110604. <https://doi.org/10.1371/journal.pone.0110604>
- Perrone S, Santacroce A, Longini M, Proietti F, Bazzini F, Buonocore G (2018) The free radical diseases of prematurity: from cellular mechanisms to bedside. *Oxid Med Cell Longev* 2018:7483062. <https://doi.org/10.1155/2018/7483062>
- Hartnett ME (2015) Pathophysiology and mechanisms of severe retinopathy of prematurity. *Ophthalmology* 122(1):200–210. <https://doi.org/10.1016/j.ophtha.2014.07.050>
- Smith LEH (2008) Through the eyes of a child: understanding retinopathy through ROP—The Friedenwald Lecture. *Invest Ophthalmol Vis Sci* 49(12):5177–5182. <https://doi.org/10.1167/iovs.08-2584>
- Sapieha P, Hamel D, Shao Z, Rivera JC, Zaniolo K, Joyal JS, Chemtob S (2010) Proliferative retinopathies: angiogenesis that blinds. *Int J Biochem Cell Biol* 42(1):5–12. <https://doi.org/10.1016/j.biocel.2009.10.006>
- Chiang MF, Quinn GE, Fielder AR et al (2021) International classification of retinopathy of prematurity, third edition. *Ophthalmology* 128(10):e51–e68. <https://doi.org/10.1016/j.ophtha.2021.05.031>
- Hartnett ME (2010) Studies on the pathogenesis of avascular retina and neovascularization into the vitreous in peripheral severe retinopathy of prematurity (an American Ophthalmological Society thesis). *Trans Am Ophthalmol Soc* 108:96–119
- Zin A, Gole GA (2013) Retinopathy of prematurity-incidence today. *Clin Perinatol* 40(2):185–200. <https://doi.org/10.1016/j.clp.2013.02.001>
- Chang JW (2019) Risk factor analysis for the development and progression of retinopathy of prematurity. *PLoS ONE* 14(7):e0219934. <https://doi.org/10.1371/journal.pone.0219934>
- Quinn GE, Ying GS, Bell EF, Donohue PK, Morrison D, Tomlinson LA, Binenbaum G (2018) Incidence and early course of retinopathy of prematurity: secondary analysis of the Postnatal Growth and Retinopathy of Prematurity (G-ROP) Study. *JAMA Ophthalmol* 136(12):1383–1389. <https://doi.org/10.1001/jamaophthalmol.2018.4290>
- Blencowe H, Lawn JE, Vazquez T, Fielder A, Gilbert C (2013) Preterm-associated visual impairment and estimates of retinopathy of prematurity at regional and global levels for 2010. *Pediatr Res* 74(Suppl 1):35–49. <https://doi.org/10.1038/pr.2013.205>

18. Goldstein GP, Leonard SA, Kan P, Koo EB, Lee HC, Carmichael SL (2019) Prenatal and postnatal inflammation-related risk factors for retinopathy of prematurity. *J Perinatol* 39(7):964–973. <https://doi.org/10.1038/s41372-019-0357-2>
19. Saugstad OD (2005) Oxidative stress in the newborn—a 30-year perspective. *Biol Neonate* 88(3):228–236. <https://doi.org/10.1159/000087586>
20. Dammann O (2010) Inflammation and retinopathy of prematurity. *Acta Paediatr Int J Paediatr* 99(7):975–977. <https://doi.org/10.1111/j.1651-2227.2010.01836.x>
21. Sullivan JL (1986) Retinopathy of prematurity and iron: a modification of the oxygen hypothesis. *Pediatrics* 78(6):1171–1172
22. Miao L, St. Clair DK (2009) Regulation of superoxide dismutase genes: Implications in disease. *Free Radic Biol Med* 47(4):344–356. <https://doi.org/10.1016/j.freeradbiomed.2009.05.018>
23. Poggi C, Giusti B, Vestri A, Pasquini E, Abbate R, Dani C (2012) Genetic polymorphisms of antioxidant enzymes in preterm infants. *J Matern Neonatal Med* 25(Suppl 4):131–134. <https://doi.org/10.3109/14767058.2012.714976>
24. Good WV, Hardy RJ, Dobson V et al (2005) The incidence and course of retinopathy of prematurity: findings from the early treatment for retinopathy of prematurity study. *Pediatrics* 116(1):15–23. <https://doi.org/10.1542/peds.2004-1413>
25. Patz A (1980) Studies on retinal neovascularization. Friedenwald lecture. *Investig Ophthalmol Vis Sci* 19(10):1133–1138
26. York JR, Landers S, Kirby RS, Arbogast PG, Penn JS (2004) Arterial oxygen fluctuation and retinopathy of prematurity in very-low-birth-weight infants. *J Perinatol* 24(2):82–87. <https://doi.org/10.1038/sj.jp.7211040>
27. Lenhartova N, Matasova K, Lasabova Z, Javorka K (2017) Impact of early aggressive nutrition on retinal development in premature infants. *Physiol Res* 66(Suppl 2):S215–S226. <https://doi.org/10.33549/physiolres.933677>
28. Gagliardi L, Rusconi F, Da Frè M, Mello G, Carnielli V, Di Lallo D, Macagno F, Miniaci S, Corchia C, Cuttini M (2013) Pregnancy disorders leading to very preterm birth influence neonatal outcomes: results of the population-based ACTION cohort study. *Pediatr Res* 73(6):794–801. <https://doi.org/10.1038/pr.2013.52>
29. Gallo J, Jacobson L, Broberger U (1993) Perinatal factors associated with retinopathy of prematurity. *Acta Paediatr* 82(10):829–834. <https://doi.org/10.1111/j.1651-2227.1993.tb12573.x>
30. Spiegler J, Jensen R, Segerer H, Ehlers S, Kühn T, Jenke A, Gebauer C, Möller J, Orlikowsky T, Heitmann F, Boeckenholt K, Herting E, Göpel W (2013) Influence of smoking and alcohol during pregnancy on outcome of VLBW infants. *Z Geburtshilfe Neonatol* 217(6):215–219. <https://doi.org/10.1055/s-0033-1361145>
31. Reem RE, Nguyen T, Yu Y, Ying G-S, Tomlinson LA, Binenbaum G (2021) Effects of altitude on retinopathy of prematurity. *J Am Assoc Pediatr Ophthalmol Strabismus* 61(7):2190. <https://doi.org/10.1016/j.jaapos.2021.08.254>
32. Yang MB, Rao S, Copenhagen DR, Lang RA (2013) Length of day during early gestation as a predictor of risk for severe retinopathy of prematurity. *Ophthalmology* 120(12):2706–2713. <https://doi.org/10.1016/j.ophtha.2013.07.051>
33. Chan RV, Yonekawa Y, Morrison MA, Sun G, Wong RK, Perlman JM, Chiang MF, Lee TC, Hartnett ME, Deangelis MM (2010) Association between assisted reproductive technology and advanced retinopathy of prematurity. *Clin Ophthalmol* 4:1385–1390. <https://doi.org/10.2147/OPHTH.S15587>
34. Barker L, Bunce C, Husain S, Adams GGW (2017) Is artificial reproductive technology a risk factor for retinopathy of prematurity independent of the generation of multiple births? *Eur J Ophthalmol* 27(2):174–178. <https://doi.org/10.5301/ejo.5000832>
35. Hartnett ME (2017) Advances in understanding and management of retinopathy of prematurity. *Surv Ophthalmol* 62(3):257–276. <https://doi.org/10.1016/j.survophthal.2016.12.004>
36. Shastry BS (2010) Genetic susceptibility to advanced retinopathy of prematurity (ROP). *J Biomed Sci* 17(1):69. <https://doi.org/10.1186/1423-0127-17-69>
37. Pietrzyk JJ, Kwinta P, Bik-Multanowski M, Madetko-Talowska A, Jagła M, Tomasiak T, Mitkowska Z, Wollen EJ, Nygård S, Saugstad OD (2013) New insight into the pathogenesis of retinopathy of prematurity: assessment of whole-genome expression. *Pediatr Res* 73(4 Pt 1):476–483. <https://doi.org/10.1038/pr.2012.195>
38. Lee J, Dammann O (2012) Perinatal infection, inflammation, and retinopathy of prematurity. *Semin Fetal Neonatal Med* 17(1):26–29. <https://doi.org/10.1016/j.siny.2011.08.007>
39. Ahn YJ, Hong KE, Yum HR, Lee JH, Kim KS, Youn YA, Park SH (2017) Characteristic clinical features associated with aggressive posterior retinopathy of prematurity. *Eye* 31(6):924–930. <https://doi.org/10.1038/eye.2017.18>
40. Wang X, Tang K, Chen L, Cheng S, Xu H (2019) Association between sepsis and retinopathy of prematurity: a systematic review and meta-analysis. *BMJ Open* 9(5):e025440. <https://doi.org/10.1136/bmjopen-2018-025440>
41. Hong HK, Lee HJ, Ko JH, Park JH, Park JY, Choi CW, Yoon CH, Ahn SJ, Park KH, Woo SJ, Oh JY (2014) Neonatal systemic inflammation in rats alters retinal vessel development and simulates pathologic features of retinopathy of prematurity. *J Neuroinflamm* 11:87. <https://doi.org/10.1186/1742-2094-11-87>
42. Gabay C, Kushner I (1999) Acute-phase proteins and other systemic responses to inflammation. *N Engl J Med* 340(6):448–454. <https://doi.org/10.1056/NEJM199902113400607>
43. Wang H, Zhang SX, Hartnett ME (2013) Signaling pathways triggered by oxidative stress that mediate features of severe retinopathy of prematurity. *Arch Ophthalmol* 131(1):80–85. <https://doi.org/10.1001/jamaophthalmol.2013.986>
44. Mataftsi A, Dimitrakos SA, Adams GGW (2011) Mediators involved in retinopathy of prematurity and emerging therapeutic targets. *Early Hum Dev* 87(10):683–690. <https://doi.org/10.1016/j.earlhumdev.2011.05.009>
45. Folkman J, D'Amore PA (1996) Blood vessel formation: what is its molecular basis? *Cell* 87(7):1153–1155. [https://doi.org/10.1016/s0092-8674\(00\)81810-3](https://doi.org/10.1016/s0092-8674(00)81810-3)
46. Zhang J, Zhao R, Chen J, Jin J, Yu Y, Tian Y, Li W, Wang W, Zhou H, Su SB (2017) The effect of interleukin 38 on angiogenesis in a model of oxygen-induced retinopathy. *Sci Rep* 7(1):256. <https://doi.org/10.1038/s41598-017-03079-z>
47. Chung AS, Ferrara N (2011) Developmental and pathological angiogenesis. *Annu Rev Cell Dev Biol* 27:563–584. <https://doi.org/10.1146/annurev-cellbio-092910-154002>
48. Sood BG, Madan A, Saha S, Schendel D, Thorsen P, Skogstrand K, Hougaard D, Shankaran S, Carlo W (2010) Perinatal systemic inflammatory response syndrome and retinopathy of prematurity. *Pediatr Res* 67(4):394–400. <https://doi.org/10.1203/PDR.0b013e3181d01a36>
49. Sato T, Kusaka S, Hashida N, Saishin Y, Fujikado T, Tano Y (2009) Comprehensive gene-expression profile in murine oxygen-induced retinopathy. *Br J Ophthalmol* 93(1):96–103. <https://doi.org/10.1136/bjo.2008.142646>
50. Sato T, Kusaka S, Shimojo H, Fujikado T (2009) Simultaneous analyses of vitreous levels of 27 cytokines in eyes with retinopathy of prematurity. *Ophthalmology* 116(11):2165–2169. <https://doi.org/10.1016/j.ophtha.2009.04.026>
51. Voronov E, Shouval DS, Krelin Y, Cagnano E, Benharroch D, Iwakura Y, Dinarello CA, Apte RN (2003) IL-1 is required for tumor invasiveness and angiogenesis. *Proc Natl Acad Sci USA* 100(5):2645–2650. <https://doi.org/10.1073/pnas.0437939100>

52. Hangai M, Yoshimura N, Yoshida M, Yabuuchi K, Honda Y (1995) Interleukin-1 gene expression in transient retinal ischemia in the rat. *Investig Ophthalmol Vis Sci* 36(3):571–578
53. Rivera JC, Sitaras N, Noueihed B, Hamel D, Madaan A, Zhou T, Honoré JC, Quiniou C, Joyal JS, Hardy P, Sennlaub F, Lubell W, Chemtob S (2013) Microglia and interleukin-1 $\beta$  in ischemic retinopathy elicit microvascular degeneration through neuronal semaphorin-3A. *Arterioscler Thromb Vasc Biol* 33(8):1881–1891. <https://doi.org/10.1161/ATVBAHA.113.301331>
54. Sivakumar V, Foulds WS, Luu CD, Ling EA, Kaur C (2011) Retinal ganglion cell death is induced by microglia derived pro-inflammatory cytokines in the hypoxic neonatal retina. *J Pathol* 224:245–260. <https://doi.org/10.1002/path.2858>
55. Luna JD, Chan CC, Derevanik NL, Mahlow J, Chiu C, Peng B, Tobe T, Campochiaro PA, Vinorez SA (1997) Blood-retinal barrier (BRB) breakdown in experimental autoimmune uveoretinitis: Comparison with vascular endothelial growth factor, tumor necrosis factor and interleukin-1 $\beta$ -mediated breakdown. *J Neurosci Res* 49(3):268–280. [https://doi.org/10.1002/\(SICI\)1097-4547\(19970801\)49:3%3c268::AID-JNR2%3e3.0.CO;2-A](https://doi.org/10.1002/(SICI)1097-4547(19970801)49:3%3c268::AID-JNR2%3e3.0.CO;2-A)
56. Zhou TE, Rivera JC, Bhosle VK et al (2016) Choroidal Involvement Is Associated with a Progressive Degeneration of the Outer Retinal Function in a Model of Retinopathy of Prematurity: Early Role for IL-1 $\beta$ . *Am J Pathol* 186(12):3100–3116. <https://doi.org/10.1016/j.ajpath.2016.08.004>
57. Beaudry-Richard A, Nadeau-Vallée M, Prairie É et al (2018) Antenatal IL-1-dependent inflammation persists postnatally and causes retinal and sub-retinal vasculopathy in progeny. *Sci Rep* 8:11875. <https://doi.org/10.1038/s41598-018-30087-4>
58. Opal SM, DePalo VA (2000) Anti-inflammatory cytokines. *Chest* 117(4):1162–1172. <https://doi.org/10.1378/chest.117.4.1162>
59. Rathi S, Jalali S, Patnaik S et al (2017) Abnormal complement activation and inflammation in the pathogenesis of retinopathy of prematurity. *Front Immunol* 8:1868. <https://doi.org/10.3389/fimmu.2017.01868>
60. Wooff Y, Man SM, Aggio-Bruce R, Natoli R, Fernando N (2019) IL-1 family members mediate cell death, inflammation and angiogenesis in retinal degenerative diseases. *Front Immunol* 10:1618. <https://doi.org/10.3389/fimmu.2019.01618>
61. Kremlev SG, Palmer C (2005) Interleukin-10 inhibits endotoxin-induced pro-inflammatory cytokines in microglial cell cultures. *J Neuroimmunol* 162(1–2):71–80. <https://doi.org/10.1016/j.jneuroim.2005.01.010>
62. Dace DS, Khan AA, Kelly J, Apte RS (2008) Interleukin-10 promotes pathological angiogenesis by regulating macrophage response to hypoxia during development. *PLoS ONE* 3(10):e3381. <https://doi.org/10.1371/journal.pone.0003381>
63. Bensen JT, Dawson PA, Mychaleckyj JC, Bowden DW (2001) Identification of a novel human cytokine gene in the interleukin gene cluster on chromosome 2q12–14. *J Interf Cytokine Res* 21(11):899–904. <https://doi.org/10.1089/107999001753289505>
64. Qiao H, Sonoda K-H, Ikeda Y, Yoshimura T, Hijioaka K, Jo Y-J, Sassa Y, Tsutsumi-Miyahara C, Hata Y, Akira S, Ishibashi T (2007) Interleukin-18 regulates pathological intraocular neovascularization. *J Leukoc Biol* 81(4):1012–1021. <https://doi.org/10.1189/jlb.0506342>
65. Hellgren G, Löfqvist C, Hansen-Pupp I, Gram M, Smith LE, Ley D, Hellström A (2018) Increased postnatal concentrations of pro-inflammatory cytokines are associated with reduced IGF-I levels and retinopathy of prematurity. *Growth Horm IGF Res* 39:19–24. <https://doi.org/10.1016/j.ghir.2017.11.006>
66. Rivera JC, Noueihed B, Madaan A, Lahaie I, Pan J, Belik J, Chemtob S (2017) Tetrahydrobiopterin (BH4) deficiency is associated with augmented inflammation and microvascular degeneration in the retina. *J Neuroinflammation* 14:181. <https://doi.org/10.1186/s12974-017-0955-x>
67. Brand MP, Heales SJR, Land JM, Clark JB (1995) Tetrahydrobiopterin deficiency and brain nitric oxide synthase in the hph1 mouse. *J Inher Metab Dis* 18(1):33–39. <https://doi.org/10.1007/BF00711370>
68. Edgar KS, Matesanz N, Gardiner TA, Katusic ZS, McDonald DM (2015) Hyperoxia depletes (6R)-5,6,7,8-tetrahydrobiopterin levels in the neonatal retina: Implications for nitric oxide synthase function in retinopathy. *Am J Pathol* 185(6):1769–1782. <https://doi.org/10.1016/j.ajpath.2015.02.021>
69. Powers MR, Davies MH, Eubanks JP (2005) Increased expression of chemokine KC, an interleukin-8 homologue, in a model of oxygen-induced retinopathy. *Curr Eye Res* 30(4):299–307. <https://doi.org/10.1080/02713680590923276>
70. Hughes CE, Nibbs RJB (2018) A guide to chemokines and their receptors. *FEBS J* 285(16):2944–2971. <https://doi.org/10.1111/febs.14466>
71. Ghasemi H, Ghazanfari T, Yaraee R, Faghihzadeh S, Hassan ZM (2011) Roles of IL-8 in ocular inflammations: a review. *Ocul Immunol Inflamm* 19(6):401–412. <https://doi.org/10.3109/09273948.2011.618902>
72. Silveira RC, Fortes Filho JB, Procianny RS (2011) Assessment of the contribution of cytokine plasma levels to detect retinopathy of prematurity in very low birth weight infants. *Invest Ophthalmol Vis Sci* 52(3):1297–1301. <https://doi.org/10.1167/iovs.10>
73. Holm M, Morken TS, Fichorova RN, VanderVeen DK, Allred EN, Dammann O, Leviton A (2017) Systemic inflammation-associated proteins and retinopathy of prematurity in infants born before the 28th week of gestation. *Investig Ophthalmol Vis Sci* 58(14):6419–6428. <https://doi.org/10.1167/iovs.17-21931>
74. Yao Y, Tsrka SE (2014) Monocyte chemoattractant protein-1 and the blood–brain barrier. *Cell Mol Life Sci* 71(4):683–697. <https://doi.org/10.1007/s00018-013-1459-1>
75. Yoshida S (2003) Role of MCP-1 and MIP-1alpha in retinal neovascularization during postischemic inflammation in a mouse model of retinal neovascularization. *J Leukoc Biol* 73(1):137–144. <https://doi.org/10.1189/jlb.0302117>
76. Yu H, Yuan L, Zou Y, Peng L, Wang Y, Li T, Tang S (2014) Serum concentrations of cytokines in infants with retinopathy of prematurity. *APMIS* 122(9):818–823. <https://doi.org/10.1111/apm.12223>
77. Hellgren G, Willett K, Engstrom E, Thorsen P, Hougaard DM, Jacobsson B, Hellstrom A, Lofqvist C (2010) Proliferative retinopathy is associated with impaired increase in BDNF and RANTES expression levels after preterm birth. *Neonatology* 98(4):409–418. <https://doi.org/10.1159/000317779>
78. Kamba T, McDonald DM (2007) Mechanisms of adverse effects of anti-VEGF therapy for cancer. *Br J Cancer* 96(12):1788–1795. <https://doi.org/10.1038/sj.bjc.6603813>
79. Rashid K, Akhtar-Schaefer I, Langmann T (2019) Microglia in retinal degeneration. *Front Immunol* 10:1975. <https://doi.org/10.3389/fimmu.2019.01975>
80. Davies LC, Jenkins SJ, Allen JE, Taylor PR (2013) Tissue-resident macrophages. *Nat Immunol* 14(10):986–995. <https://doi.org/10.1038/ni.2705>
81. Galli SJ, Borregaard N, Wynn TA (2011) Phenotypic and functional plasticity of cells of innate immunity: macrophages, mast cells and neutrophils. *Nat Immunol* 12(11):1035–1044. <https://doi.org/10.1038/ni.2109>
82. Di ZY, Yoshida S, Peng YQ, Kobayashi Y, Zhang LS, Tang LS (2017) Diverse roles of macrophages in intraocular neovascular diseases: a review. *Int J Ophthalmol* 10(12):1902–1908. <https://doi.org/10.18240/ijo.2017.12.18>
83. Jetten N, Verbruggen S, Gijbels MJ, Post MJ, De Winther MPJ, Donners MMPC (2014) Anti-inflammatory M2, but not pro-inflammatory M1 macrophages promote angiogenesis

- in vivo. *Angiogenesis* 17(1):109–118. <https://doi.org/10.1007/s10456-013-9381-6>
84. Sica A, Erreni M, Allavena P, Porta C (2015) Macrophage polarization in pathology. *Cell Mol Life Sci* 72(21):4111–4126. <https://doi.org/10.1007/s00018-015-1995-y>
  85. Ribatti D (2017) The contribution of immune cells to angiogenesis in inflammation and tumor growth. *Inflammation and angiogenesis*. Springer, Cham, pp 27–84
  86. Mantovani A, Biswas SK, Galdiero MR, Sica A, Locati M (2013) Macrophage plasticity and polarization in tissue repair and remodelling. *J Pathol* 229(2):176–185. <https://doi.org/10.1002/path.4133>
  87. Chen S, Yang J, Wei Y, Wei X (2020) Epigenetic regulation of macrophages: from homeostasis maintenance to host defense. *Cell Mol Immunol* 17:36–49. <https://doi.org/10.1038/s41423-019-0315-0>
  88. Ponomarev ED, Veremyko T, Weiner HL (2013) MicroRNAs are universal regulators of differentiation, activation, and polarization of microglia and macrophages in normal and diseased CNS. *Glia* 61(1):91–103. <https://doi.org/10.1002/glia.22363>
  89. Zhou Y, Yoshida S, Nakao S, Yoshimura T, Kobayashi Y, Nakama T, Kubo Y, Miyawaki K, Yamaguchi M, Ishikawa K, Oshima Y, Akashi K, Ishibashi T (2015) M2 macrophages enhance pathological neovascularization in the mouse model of oxygen-induced retinopathy. *Investig Ophthalmol Vis Sci* 56(8):4767–4777. <https://doi.org/10.1167/iovs.14-16012>
  90. Hartnett ME, Cotten CM (2015) Genomics in the neonatal nursery: focus on ROP. *Semin Perinatol* 39(8):604–610. <https://doi.org/10.1053/j.semperi.2015.09.007>
  91. Bizzarro MJ, Hussain N, Jonsson B, Feng R, Ment LR, Gruen JR, Zhang H, Bhandari V (2006) Genetic susceptibility to retinopathy of prematurity. *Pediatrics* 118(5):1858–1863. <https://doi.org/10.1542/peds.2006-1088>
  92. Ortega-Molina JM, Anaya-Alaminos R, Uberos-Fernández J, Solans-Pérez De Larraya A, Chaves-Samaniego MJ, Salgado-Miranda A, Piñar-Molina R, Jerez-Calero A, García-Serrano JL (2015) Genetic and environmental influences on retinopathy of prematurity. *Mediators Inflamm* 2015:764159. <https://doi.org/10.1155/2015/764159>
  93. Van Wijngaarden P, Coster DJ, Brereton HM, Gibbins IL, Williams KA (2005) Strain-dependent differences in oxygen-induced retinopathy in the inbred rat. *Investig Ophthalmol Vis Sci* 46(4):1445–1452. <https://doi.org/10.1167/iovs.04-0708>
  94. Floyd BNI, Leske DA, Wren SME, Mookadam M, Fautsch MP, Holmes JM (2005) Differences between rat strains in models of retinopathy of prematurity. *Mol Vis* 11:524–530
  95. Saunders RA, Donahue ML, Christmann LM, Pakalnis AV, Tung B, Hardy RJ, Phelps DL (1997) Racial variation in retinopathy of prematurity. The Cryotherapy for Retinopathy of Prematurity Cooperative Group. *Arch Ophthalmol* 115(5):604–608. <https://doi.org/10.1001/archophth.1997.01100150606005>
  96. Darlow BA, Hutchinson JL, Henderson-Smart DJ, Donoghue DA, Simpson JM, Evans NJ (2005) Prenatal risk factors for severe retinopathy of prematurity among very preterm infants of the Australian and New Zealand Neonatal Network. *Pediatrics* 115(4):990–996. <https://doi.org/10.1542/peds.2004-1309>
  97. Schaffer DB, Palmer EA, Plotsky DF, Metz HS, Flynn JT, Tung B, Hardy RJ (1993) Prognostic factors in the natural course of retinopathy of prematurity. The Cryotherapy for Retinopathy of Prematurity Cooperative Group. *Ophthalmology* 100(2):230–237. [https://doi.org/10.1016/S0161-6420\(93\)31665-9](https://doi.org/10.1016/S0161-6420(93)31665-9)
  98. Yang MB, Donovan EF, Wagge JR (2006) Race, Gender, and Clinical Risk Index for Babies (CRIB) Score as predictors of severe retinopathy of prematurity. *J AAPOS* 10(3):253–261. <https://doi.org/10.1016/j.jaapos.2006.01.004>
  99. Aralikkatti AKV, Mitra A, Denniston AKO, Haque MS, Ewer AK, Butler L (2010) Is ethnicity a risk factor for severe retinopathy of prematurity? *Arch Dis Child Fetal Neonatal Ed* 95(3):F174–F176. <https://doi.org/10.1136/adc.2009.160366>
  100. Janevic T, Zeitlin J, Auger N, Egorova NN, Hebert P, Balbierz A, Howell EA (2018) Association of race/ethnicity with very preterm neonatal morbidities. *JAMA Pediatr* 172(11):1061–1069. <https://doi.org/10.1001/jamapediatrics.2018.2029>
  101. Lang DM, Blackledge J, Arnold RW (2005) Is Pacific race a retinopathy of prematurity risk factor? *Arch Pediatr Adolesc Med* 159(8):771–773. <https://doi.org/10.1001/archpedi.159.8.771>
  102. Hyland RM, Komlósi K, Alleman BW, Tolnai M, Wood LM, Bell EF, Ertl T (2013) Infantile hemangiomas and retinopathy of prematurity: clues to the regulation of vasculogenesis. *Eur J Pediatr* 172(6):803–809. <https://doi.org/10.1007/s00431-013-1966-y>
  103. Léauté-Labrèze C, de la Roque ED, Hubiche T, Boralevi F, Thambo J-B, Taïeb A (2008) Propranolol for severe hemangiomas of infancy. *N Engl J Med* 358(24):2649–2651. <https://doi.org/10.1056/nejmc0708819>
  104. Krowchuk DP, Frieden IJ, Mancini AJ et al (2019) Clinical practice guideline for the management of infantile hemangiomas. *Pediatrics* 143(1):e20183475. <https://doi.org/10.1542/peds.2018-3475>
  105. Filippi L, Cavallaro G, Berti E et al (2019) Propranolol 0.2% eye micro-drops for retinopathy of prematurity: a prospective phase IIb study. *Front Pediatr* 7:180. <https://doi.org/10.3389/fped.2019.00180>
  106. Van Sorge AJ, Termote JUM, Kerkhoff FT, Van Rijn LJ, Simonsz HJ, Peer PGM, Schalijs-Delfos NE (2014) Nationwide inventory of risk factors for retinopathy of prematurity in the Netherlands. *J Pediatr* 164(3):494–498.e1. <https://doi.org/10.1016/j.jpeds.2013.11.015>
  107. Ying GS, Quinn GE, Wade KC, Repka MX, Baumritter A, Daniel E (2015) Predictors for the development of referral-warranted retinopathy of prematurity in the telemedicine approaches to evaluating acute-phase retinopathy of prematurity (e-ROP) study. *JAMA Ophthalmol* 133(3):304–311. <https://doi.org/10.1001/jamaophthalmol.2014.5185>
  108. Slidsborg C, Jensen A, Forman JL, Rasmussen S, Bangsgaard R, Fledelius HC, Greisen G, La Cour M (2016) Neonatal risk factors for treatment-demanding retinopathy of prematurity: a Danish National Study. *Ophthalmology* 123(4):796–803. <https://doi.org/10.1016/j.ophtha.2015.12.019>
  109. Lundgren P, Kistner A, Andersson EM, Pupp IH, Holmström G, Ley D, Niklasson A, Smith LEH, Wu C, Hellström A, Löfqvist C (2014) Low birth weight is a risk factor for severe retinopathy of prematurity depending on gestational age. *PLoS ONE* 9(10):e109460. <https://doi.org/10.1371/journal.pone.0109460>
  110. Palmer EA, Flynn JT, Hardy RJ et al (1991) Incidence and early course of retinopathy of prematurity. *Ophthalmology* 98(11):1628–1640. [https://doi.org/10.1016/S0161-6420\(91\)32074-8](https://doi.org/10.1016/S0161-6420(91)32074-8)
  111. Chiang MF, Arons RR, Flynn JT, Starren JB (2004) Incidence of retinopathy of prematurity from 1996 to 2000: Analysis of a comprehensive New York state patient database. *Ophthalmology* 111(7):1317–1325. <https://doi.org/10.1016/j.ophtha.2003.10.030>
  112. Dailey WA, Garg PG, Dresner KA (2015) Frizzled-4 variations associated with retinopathy and intrauterine growth retardation: a potential marker for prematurity and retinopathy. *Ophthalmology* 122(9):1917–1923. <https://doi.org/10.1016/j.ophtha.2015.05.036>
  113. Sizmaz S, Yonekawa Y, Trese MT (2015) Familial exudative vitreoretinopathy. *Turk J Ophthalmol* 45(4):164–168. <https://doi.org/10.4274/tjo.67699>
  114. Chen ZY, Battinelli EM, Fielder A, Bunday S, Sims K, Breakefield XO, Craig IW (1993) A mutation in the norrie disease

- gene (NDP) associated with X linked familial exudative vitreoretinopathy. *Nat Genet* 5(2):180–183. <https://doi.org/10.1038/ng1093-180>
115. Li Y, Li J, Zhang X, Peng J, Li J, Zhao P, Armenti ST (2020) Identification of gene mutations in atypical retinopathy of prematurity cases. *J Ophthalmol* 2020:4212158. <https://doi.org/10.1155/2020/4212158>
  116. John VJ, McClintic JI, Hess DJ, Berrocal AM (2016) Retinopathy of prematurity versus familial exudative vitreoretinopathy: report on clinical and angiographic findings. *Ophthalmic Surg Lasers Imaging Retin* 47(1):14–19. <https://doi.org/10.3928/23258160-20151214-02>
  117. Kandasamy Y, Hartley L, Rudd D, Smith R (2017) The association between systemic vascular endothelial growth factor and retinopathy of prematurity in premature infants: a systematic review. *Br J Ophthalmol* 101(1):21–24. <https://doi.org/10.1136/bjophthalmol-2016-308828>
  118. Nguyen QD, De Falco S, Behar-Cohen F, Lam WC, Li X, Reichhart N, Ricci F, Plum J, Li WW (2018) Placental growth factor and its potential role in diabetic retinopathy and other ocular neovascular diseases. *Acta Ophthalmol* 96:e1–e9. <https://doi.org/10.1111/aos.13325>
  119. Pieh C, Agostini H, Buschbeck C, Krüger M, Schulte-Mönting J, Zirgibel U, Dreves J, Lagrèze WA (2008) VEGF-A VEGFR-1, VEGFR-2 and Tie2 levels in plasma of premature infants: Relationship to retinopathy of prematurity. *Br J Ophthalmol* 92(5):689–693. <https://doi.org/10.1136/bjo.2007.128371>
  120. Shibuya M (2011) Vascular endothelial growth factor (VEGF) and its receptor (VEGFR) signaling in angiogenesis: a crucial target for anti- and pro-angiogenic therapies. *Genes Cancer* 2(12):1097–1105. <https://doi.org/10.1177/1947601911423031>
  121. Cooke RW, Drury JA, Mountford R, Clark D (2004) Genetic polymorphisms and retinopathy of prematurity. *Investig Ophthalmol Vis Sci* 45(6):1712–1715. <https://doi.org/10.1167/iov.03-1303>
  122. Ali AA, Hussien NF, Samy RM, Al Hussein K (2015) Polymorphisms of vascular endothelial growth factor and retinopathy of prematurity. *J Pediatr Ophthalmol Strabismus* 52(4):245–253. <https://doi.org/10.3928/01913913-20150506-02>
  123. Vannay Á, Dunai G, Bányász I, Szabó M, Vámos R, Treszl A, Hajdú J, Tulassay T, Vászárhelyi B (2005) Association of genetic polymorphisms of vascular endothelial growth factor and risk for proliferative retinopathy of prematurity. *Pediatr Res* 57(3):396–398. <https://doi.org/10.1203/01.PDR.0000153867.80238.E0>
  124. Lei XJ, Zhao YX, Qiao T (2018) Influence of polymorphisms in VEGF, ACE, TNF and GST genes on the susceptibility to retinopathy of prematurity among Chinese infants. *Int J Ophthalmol* 11(9):1451–1457. <https://doi.org/10.18240/ijo.2018.09.04>
  125. Kaya M, Çokaklı M, Berk AT, Yaman A, Yesilirmak D, Kumral A, Atabey N (2013) Associations of VEGF/VEGF-receptor and HGF/c-Met promoter polymorphisms with progression/regression of retinopathy of prematurity. *Curr Eye Res* 38(1):137–142. <https://doi.org/10.3109/02713683.2012.731550>
  126. Kusuda T, Hikino S, Ohga S, Kinjo T, Ochiai M, Takahata Y, Tokunaga S, Ihara K, Hata Y, Hara T (2011) Genetic variation of vascular endothelial growth factor pathway does not correlate with the severity of retinopathy of prematurity. *J Perinatol* 31(4):246–250. <https://doi.org/10.1038/jp.2010.111>
  127. Shastry BS, Qu X (2007) Lack of association of the VEGF gene promoter (-634 G→C and -460 C→T) polymorphism and the risk of advanced retinopathy of prematurity. *Graefes Arch Clin Exp Ophthalmol* 2(9):949–962. <https://doi.org/10.1007/s00417-006-0480-6>
  128. Kimura H, Esumi H (2003) Reciprocal regulation between nitric oxide and vascular endothelial growth factor in angiogenesis. *Acta Biochim Pol* 50(1):49–59
  129. Rusai K, Vannay A, Szebeni B, Borgulya G, Fekete A, Vászárhelyi B, Tulassay T, Szabó AJ (2008) Endothelial nitric oxide synthase gene T-786C and 27-bp repeat gene polymorphisms in retinopathy of prematurity. *Mol Vis* 14:286–290
  130. Nishijima T, Nakayama M, Yoshimura M et al (2007) The endothelial nitric oxide synthase gene -786T/C polymorphism is a predictive factor for reattacks of coronary spasm. *Pharmacogenet Genomics* 17(8):581–587. <https://doi.org/10.1097/01.fpc.0000239978.61841.1a>
  131. Taverna MJ, Sola A, Guyot-Argenton C, Pacher N, Bruzzo F, Chevalier A, Slama G, Reach G, Selam JL (2002) eNOS4 polymorphism of the endothelial nitric oxide synthase predicts risk for severe diabetic retinopathy. *Diabet Med* 19(3):240–245. <https://doi.org/10.1046/j.1464-5491.2002.00681.x>
  132. Yanamandra K, Napper D, Pramanik A, Bocchini JA, Dhanireddy R (2010) Endothelial nitric oxide synthase genotypes in the etiology of retinopathy of prematurity in premature infants. *Ophthalmic Genet* 31(4):173–177. <https://doi.org/10.3109/13816810.2010.497528>
  133. Shastry BS (2013) Endothelial nitric oxide synthase gene promoter polymorphism (T-786C) may be associated with advanced retinopathy of prematurity. *Graefes Arch Clin Exp Ophthalmol* 251(9):2251–2253. <https://doi.org/10.1007/s00417-012-2231-1>
  134. Poggi C, Giusti B, Gozzini E, Sereni A, Romagnuolo I, Kura A, Pasquini E, Abbate R, Dani C, Rogers LK (2015) Genetic contributions to the development of complications in preterm newborns. *PLoS ONE* 10:e0131741. <https://doi.org/10.1371/journal.pone.0131741>
  135. Skaper S (2011) Peptide mimetics of neurotrophins and their receptors. *Curr Pharm Des* 17(25):2704–2718. <https://doi.org/10.2174/138161211797415995>
  136. Camerino C, Conte E, Cannone M, Caloiero R, Fonzino A, Tricarico D (2016) Nerve growth factor, brain-derived neurotrophic factor and osteocalcin gene relationship in energy regulation, bone homeostasis and reproductive organs analyzed by mrna quantitative evaluation and linear correlation analysis. *Front Physiol* 7:456. <https://doi.org/10.3389/fphys.2016.00456>
  137. Sahay AS, Sundrani DP, Joshi SR (2017) Neurotrophins: role in placental growth and development. *Vitam Horm* 104:243–261. <https://doi.org/10.1016/bs.vh.2016.11.002>
  138. Reichardt LF (2006) Neurotrophin-regulated signalling pathways. *Philos Trans R Soc B Biol Sci* 361(1473):1545–1564. <https://doi.org/10.1098/rstb.2006.1894>
  139. Garrido MP, Vera C, Vega M, Quest AFG, Romero C (2018) Metformin prevents nerve growth factor-dependent proliferative and proangiogenic effects in epithelial ovarian cancer cells and endothelial cells. *Ther Adv Med Oncol* 10:1758835918770984. <https://doi.org/10.1177/1758835918770984>
  140. Lam CT, Yang ZF, Lau CK, Tam KH, Fan ST, Poon RTP (2011) Brain-derived neurotrophic factor promotes tumorigenesis via induction of neovascularization: implication in hepatocellular carcinoma. *Clin Cancer Res* 17(10):3123–3133. <https://doi.org/10.1158/1078-0432.CCR-10-2802>
  141. Julio-Pieper M, Lozada P, Tapia V, Vega M, Miranda C, Vantman D, Ojeda SR, Romero C (2009) Nerve growth factor induces vascular endothelial growth factor expression in granulosa cells via a trkA receptor/mitogen-activated protein kinase-extracellularly regulated kinase 2-dependent pathway. *J Clin Endocrinol Metab* 94(8):3065–3071. <https://doi.org/10.1210/jc.2009-0542>
  142. Zhang Z, Zhang Y, Zhou Z, Shi H, Qiu X, Xiong J, Chen Y (2017) BDNF regulates the expression and secretion of VEGF from osteoblasts via the TrkB/ERK1/2 signaling pathway during

- fracture healing. *Mol Med Rep* 15(3):1362–1367. <https://doi.org/10.3892/mmr.2017.6110>
143. Hartnett ME, Morrison MA, Smith S et al (2014) Genetic variants associated with severe retinopathy of prematurity in extremely low birth weight infants. *Investig Ophthalmol Vis Sci* 55(10):6194–6203. <https://doi.org/10.1167/iovs.14-14841>
  144. Hartnett ME, Capone A Jr (2016) Advances in diagnosis, clinical care, research, and treatment in retinopathy of prematurity. *Eye Brain* 8:27–29. <https://doi.org/10.2147/EB.S105319>
  145. Rumajogee P, Madeira A, Vergé D, Hamon M, Miquel MC (2002) Up-regulation of the neuronal serotonergic phenotype in vitro: BDNF and cAMP share Trk B-dependent mechanisms. *J Neurochem* 83(6):1525–1528. <https://doi.org/10.1046/j.1471-4159.2002.01264.x>
  146. Popova NK, Ilchibaeva TV, Naumenko VS (2017) Neurotrophic factors (BDNF and GDNF) and the serotonergic system of the brain. *Biochem* 82(3):308–317. <https://doi.org/10.1134/S0006297917030099>
  147. Masson J (2019) Serotonin in retina. *Biochimie* 161:51–55. <https://doi.org/10.1016/j.biochi.2018.11.006>
  148. Chen PS, Chiu WT, Hsu PL, Lin SC, Peng IC, Wang CY, Tsai SJ (2020) Pathophysiological implications of hypoxia in human diseases. *J Biomed Sci* 27(1):63. <https://doi.org/10.1186/s12929-020-00658-7>
  149. Fallah J, Rini BI (2019) HIF inhibitors: status of current clinical development. *Curr Oncol Rep* 21(1):6. <https://doi.org/10.1007/s11912-019-0752-z>
  150. Takeda N, Maemura K, Imai Y, Harada T, Kawanami D, Nojiri T, Manabe I, Nagai R (2004) Endothelial PAS domain protein 1 gene promotes angiogenesis through the transactivation of both vascular endothelial growth factor and its receptor, Flt-1. *Circ Res* 95(2):146–153. <https://doi.org/10.1161/01.RES.0000134920.10128.b4>
  151. Morita M, Ohneda O, Yamashita T et al (2003) HLF/HIF-2 $\alpha$  is a key factor in retinopathy of prematurity in association with erythropoietin. *EMBO J* 22(5):1134–1146. <https://doi.org/10.1093/emboj/cdg117>
  152. Mohamed S, Schaa K, Cooper ME, Ahrens E, Alvarado A, Colaizy T, Marazita ML, Murray JC, Dagle JM (2009) Genetic contributions to the development of retinopathy of prematurity. *Pediatr Res* 65(2):193–197. <https://doi.org/10.1203/PDR.0b013e31818d1dbd>
  153. Hellström A, Smith LEH, Dammann O (2013) Retinopathy of prematurity. *Lancet* 382(9902):1445–1457. [https://doi.org/10.1016/S0140-6736\(13\)60178-6](https://doi.org/10.1016/S0140-6736(13)60178-6)
  154. Hellström A, Engström E, Hård AL et al (2003) Postnatal serum insulin-like growth factor I deficiency is associated with retinopathy of prematurity and other complications of premature birth. *Pediatrics* 112(5):1016–1020. <https://doi.org/10.1542/peds.112.5.1016>
  155. Hellström A, Carlsson B, Niklasson A et al (2002) IGF-I is critical for normal vascularization of the human retina. *J Clin Endocrinol Metab* 87(7):3413–3416. <https://doi.org/10.1210/jc.87.7.3413>
  156. Bonafè M, Barbieri M, Marchegiani F, Olivieri F, Ragno E, Giampieri C, Mugianesi E, Centurelli M, Franceschi C, Paolisso G (2003) Polymorphic variants of insulin-like growth factor I (IGF-I) receptor and phosphoinositide 3-kinase genes affect IGF-I plasma levels and human longevity: cues for an evolutionarily conserved mechanism of life span control. *J Clin Endocrinol Metab* 88(7):3299–3304. <https://doi.org/10.1210/jc.2002-021810>
  157. Shastry BS (2007) Assessment of the contribution of insulin-like growth factor I receptor 3174 G→A polymorphism to the progression of advanced retinopathy of prematurity. *Eur J Ophthalmol* 17(6):950–953. <https://doi.org/10.1177/112067210701700613>
  158. Balogh Á, Derzbach L, Vannay Á, Vászrhelyi B (2006) Lack of association between insulin-like growth factor I receptor G+3174A polymorphism and retinopathy of prematurity. *Graefes Arch Clin Exp Ophthalmol* 244(8):1035–1038. <https://doi.org/10.1007/s00417-005-0203-4>
  159. Sato T, Shima C, Kusaka S (2011) Vitreous levels of angiotensin-1 and angiotensin-2 in eyes with retinopathy of prematurity. *Am J Ophthalmol* 151(2):353–357.e1. <https://doi.org/10.1016/j.ajo.2010.08.037>
  160. Stark A, Dammann C, Nielsen HC, Volpe MV (2018) A pathogenic relationship of bronchopulmonary dysplasia and retinopathy of prematurity? A review of angiogenic mediators in both diseases. *Front Pediatr* 6:125. <https://doi.org/10.3389/fped.2018.00125>
  161. Maisonpierre PC, Suri C, Jones PF et al (1997) Angiotensin-2, a natural antagonist for Tie2 that disrupts in vivo angiogenesis. *Science* 277(5322):55–60. <https://doi.org/10.1126/science.277.5322.55>
  162. Takagi H, Koyama S, Seike H, Oh H, Otani A, Matsumura M, Honda Y (2003) Potential role of the angiotensin/tie2 system in ischemia-induced retinal neovascularization. *Investig Ophthalmol Vis Sci* 44(1):393–402. <https://doi.org/10.1167/iovs.02-0276>
  163. Geva E, Jaffe RB (2000) Role of angiotensins in reproductive tract angiogenesis. *Obstet Gynecol Surv* 55(8):511–519. <https://doi.org/10.1097/00006254-200008000-00024>
  164. Asahara T, Chen D, Takahashi T, Fujikawa K, Kearney M, Mager M, Yancopoulos GD, Isner JM (1998) Tie2 receptor ligands, angiotensin-1 and angiotensin-2, modulate VEGF-induced postnatal neovascularization. *Circ Res* 83(3):233–240. <https://doi.org/10.1161/01.res.83.3.233>
  165. Mandriota SJ, Pepper MS (1998) Regulation of angiotensin-2 mRNA levels in bovine microvascular endothelial cells by cytokines and hypoxia. *Circ Res* 83(8):852–859. <https://doi.org/10.1161/01.res.83.8.852>
  166. Oh H, Takagi H, Suzuma K, Otani A, Matsumura M, Honda Y (1999) Hypoxia and vascular endothelial growth factor selectively up-regulate angiotensin-2 in bovine microvascular endothelial cells. *J Biol Chem* 274(22):15732–15739. <https://doi.org/10.1074/jbc.274.22.15732>
  167. Shastry BS (2009) Lack of association of VEGF (-2578 C → A) and ANG 2 (-35 G → C) gene polymorphisms with the progression of retinopathy of prematurity. *Graefes Arch Clin Exp Ophthalmol* 247(6):859–860. <https://doi.org/10.1007/s00417-008-0988-z>
  168. Bányász I, Bokodi G, Vannay Á, Szebeni B, Treszl A, Vászrhelyi B, Tulassay T, Szabó A (2006) Genetic polymorphisms of vascular endothelial growth factor and angiotensin 2 in retinopathy of prematurity. *Curr Eye Res* 31(7–8):685–690. <https://doi.org/10.1080/02713680600801123>
  169. Dammann O, Brinkhaus MJ, Bartels DB, Dördelmann M, Dressler F, Kerk J, Dörk T, Dammann CEL (2009) Immaturity, perinatal inflammation, and retinopathy of prematurity: a multi-hit hypothesis. *Early Hum Dev* 85(5):325–329. <https://doi.org/10.1016/j.earlhumdev.2008.12.010>
  170. Taha H, Skrzypek K, Guevara I et al (2010) Role of heme oxygenase-1 in human endothelial cells: lesson from the promoter allelic variants. *Arterioscler Thromb Vasc Biol* 30(8):1634–1641. <https://doi.org/10.1161/ATVBAHA.110.207316>
  171. Sarlos S, Wilkinson-Berka JL (2005) The renin-angiotensin system and the developing retinal vasculature. *Investig Ophthalmol Vis Sci* 46(3):1069–1077. <https://doi.org/10.1167/iovs.04-0885>
  172. Moravski CJ, Kelly DJ, Cooper ME, Gilbert RE, Bertram JF, Shahinfar S, Skinner SL, Wilkinson-Berka JL (2000) Retinal neovascularization is prevented by blockade of the renin-angiotensin system. *Hypertension* 36(6):1099–1104. <https://doi.org/10.1161/01.HYP.36.6.1099>

173. Haider MZ, Devarajan LV, Al-Essa M, Kumar H (2002) Angiotensin-converting enzyme gene insertion/deletion polymorphism in Kuwaiti children with retinopathy of prematurity. *Biol Neonate* 82(2):84–88. <https://doi.org/10.1159/000063092>
174. Spiegler J, Gilhaus A, König IR et al (2009) Polymorphisms in the renin-angiotensin system and outcome of very-low-birth-weight infants. *Neonatology* 97(1):10–14. <https://doi.org/10.1159/000226602>
175. Cockle JV, Gopichandran N, Walker JJ, Levene MI, Orsi NM (2007) Matrix metalloproteinases and their tissue inhibitors in preterm perinatal complications. *Reprod Sci* 14(7):629–645. <https://doi.org/10.1177/1933719107304563>
176. Visse R, Nagase H (2003) Matrix metalloproteinases and tissue inhibitors of metalloproteinases: structure, function, and biochemistry. *Circ Res* 92(8):827–839. <https://doi.org/10.1161/01.RES.0000070112.80711.3D>
177. Zhong S, Khalil RA (2019) A disintegrin and metalloproteinase (ADAM) and ADAM with thrombospondin motifs (ADAMTS) family in vascular biology and disease. *Biochem Pharmacol* 164:188–204. <https://doi.org/10.1016/j.bcp.2019.03.033>
178. Weskamp G, Mendelson K, Swendeman S et al (2010) Pathological neovascularization is reduced by inactivation of ADAM17 in endothelial cells but not in pericytes. *Circ Res* 106(5):932–940. <https://doi.org/10.1161/CIRCRESAHA.109.207415>
179. Guaiquil VH, Hewing NJ, Chiang MF, Rosenblatt MI, Chan RVP, Blobel CP (2013) A murine model for retinopathy of prematurity identifies endothelial cell proliferation as a potential mechanism for plus disease. *Investig Ophthalmol Vis Sci* 54(8):5294–5302. <https://doi.org/10.1167/iovs.12-11492>
180. Kondo H, Kusaka S, Yoshinaga A, Uchio E, Tawara A, Tahira T (2013) Genetic variants of FZD4 and LRP5 genes in patients with advanced retinopathy of prematurity. *Mol Vis* 19:476–485
181. Hutcheson KA, Paluru PC, Bernstein SL, Koh J, Rappaport EF, Leach RA, Young TL (2005) Norrie disease gene sequence variants in an ethnically diverse population with retinopathy of prematurity. *Mol Vis* 11:501–508
182. Haider MZ, Devarajan LV, Al-Essa M, Kumar H (2002) A C597→A polymorphism in the Norrie disease gene is associated with advanced retinopathy of prematurity in premature Kuwaiti infants. *J Biomed Sci* 9(4):365–370. <https://doi.org/10.1159/000065008>
183. Shastry BS, Pendergast SD, Hartzler MK, Liu X, Trese MT (1997) Identification of missense mutations in the Norrie disease gene associated with advanced retinopathy of prematurity. *Arch Ophthalmol* 115(5):651–655. <https://doi.org/10.1001/archophth.1997.01100150653015>

**Publisher's Note** Springer Nature remains neutral with regard to jurisdictional claims in published maps and institutional affiliations.