

Treatment approach in patients with hyperbilirubinemia secondary to liver metastases in gastrointestinal malignancies: a case series and review of literature

Julia Quidde, Marc Azémar, Carsten Bokemeyer, Dirk Arnold and Alexander Stein

Ther Adv Med Oncol

2016, Vol. 8(3) 144–152

DOI: 10.1177/
1758834016637585

© The Author(s), 2016.
Reprints and permissions:
[http://www.sagepub.co.uk/
journalsPermissions.nav](http://www.sagepub.co.uk/journalsPermissions.nav)

Abstract

Background: Treatment of patients with severe liver dysfunction including hyperbilirubinemia secondary to liver metastases of gastrointestinal (GI) cancer is challenging. Regimen of oxaliplatin and fluoropyrimidine (FP)/folinic acid (FA) ± a monoclonal antibody (moAb), represents a feasible option considering the pharmacokinetics. Clinical data on the respective dosage and tolerability are limited and no recommendations are available.

Methods: Consecutive patients with severe hyperbilirubinemia [$>2 \times$ upper limit of the normal range (ULN) and >2.4 mg/dl] due to liver metastases of GI cancer without options for drainage receiving oxaliplatin, FP/FA ± moAb were analyzed. To collect further data a review of the literature was performed.

Results: A total of 12 patients were identified between 2011 and 2015. At treatment start, median bilirubin level was 6.1 mg/dl ($>5 \times$ ULN, range 2.7–13.6). The majority of patients ($n = 11$) received dose-reduced regimen with oxaliplatin (60–76%) and FP/FA (0–77%), rapidly escalating to full dose regimen. During treatment, bilirubin levels dropped more than 50% within 8 weeks or normalized within 12 weeks in 6 patients (responders). Median overall survival was 5.75 months (range 1.0–16.0 months) but was significantly prolonged in responders compared to nonresponders [9.7 and 3.0 months, $p = 0.026$ (two-sided test); 95% confidence interval (CI): 1.10–10.22]. In addition, case reports or series comprising a further 26 patients could be identified. Based on the obtained data a treatment algorithm was developed.

Conclusion: Treatment with oxaliplatin, FP/FA ± moAb is feasible and may derive relevant benefits in patients with severe liver dysfunction caused by GI cancer liver metastases without further options of drainage.

Keywords: chemotherapy, gastrointestinal cancer, hyperbilirubinemia, liver dysfunction, liver metastases

Introduction

Gastrointestinal (GI) cancer, particularly colorectal, gastric, esophageal and pancreatic malignancies, are among the most common cancer types worldwide [Ferlay *et al.* 2014]. Moreover, the high rate of metastatic disease accounts for the overall high mortality rates. Due to anatomical location and venous drainage the liver is the predominant organ for metastatic manifestation of tumors arising from the GI tract. Thus, impaired liver function and finally liver failure are common among GI

cancer patients. On the other hand, the approved treatment combinations are based on clinical trials of selected patients with good liver function and normal values of bilirubin [<1.5 times upper limit of normal (ULN)] and transaminases.

Metastatic liver involvement may result in liver dysfunction, indicated by increased bilirubin (hyperbilirubinemia), increased level of cholestatic parameters (gamma-glutamyl transferase and alkaline phosphatase) and transaminases as well as

Correspondence to:
Julia Quidde, Dr.
University Medical Center
Hamburg-Eppendorf,
Department of Oncology,
Hematology, Bone Marrow
Transplantation with
Section Pneumology,
Hubertus Wald Tumor
Center, Martinistraße 52,
20246 Hamburg, Germany
j.quidde@uke.de

Marc Azémar, Dr.
Tumor Biology Center
Freiburg, Freiburg,
Germany

Carsten Bokemeyer, Dr.
Alexander Stein, Dr.
University Medical Center
Hamburg-Eppendorf,
Department of Oncology,
Hematology, Bone Marrow
Transplantation with
Section Pneumology,
Hubertus Wald Tumor
Center, Hamburg,
Germany

Dirk Arnold, Dr.
Tumor Biology Center
Freiburg, Freiburg,
Germany
CUF Hospitals Cancer
Centre, Lisbon, Portugal

impaired liver synthesis (e.g. low albumin). Pretreatment evaluation of liver dysfunction is important to ensure treatment tolerability and thus efficacy. Within the above-mentioned laboratory values, bilirubin is often used for a rough estimate of liver function and the consecutive treatment selection. Hyperbilirubinemia may have different reasons, in the case of severe liver involvement without options for biliary drainage, active and tolerable systemic treatment may reduce tumor burden and alleviate symptoms. By contrast, hyperbilirubinemia due to extrahepatic cholestasis may be managed by drainage and bilirubin will recover over time. Thus, tolerability will be the central concern of treatment administration.

Several systemic agents are available for GI cancer (e.g. irinotecan, fluoropyrimidine, taxanes and platin compounds), which differ highly in terms of pharmacokinetics, particularly regarding hepatic metabolism. For example, bioactivation of irinotecan and detoxification of its metabolite SN-38 occurs predominantly in the liver and thus drug clearance is diminished in patients with hepatic dysfunction [Rivory and Robert, 1995; Gagne *et al.* 2002]. The tolerability of irinotecan in patients with hepatic dysfunction (bilirubin greater than 2 mg/dl) has not been assessed sufficiently and no recommendations for dosing can be made. Fluoropyrimidines (FP) are eliminated primarily by hepatic metabolism, with less than 5% of the drug excreted in the urine in normal individuals [Schalhorn and Kuhl, 1992; Schilsky, 1998]. Capecitabine, a prodrug of 5-Fluorouracil (5-FU) is activated through three enzymatic reactions. Although high activities of drug metabolizing enzymes are expressed in human liver, the involvement of the liver in capecitabine metabolism is not fully understood and the use in patients with hepatic failure is controversially discussed [Twelves *et al.* 1999; Saif and Tejani, 2007]. Available reports showed no clinically significant influence on the pharmacokinetics of capecitabine and its metabolites by modestly impaired hepatic function [Twelves *et al.* 1999; Saif and Tejani, 2007]. Taxanes (docetaxel or paclitaxel) are predominantly eliminated by hepatobiliary extraction and are thus already contraindicated in case of modest liver dysfunction [Bruno *et al.* 2001; Hooker *et al.* 2008; Minami *et al.* 2009; Eckmann *et al.* 2014]. In contrast to irinotecan, fluoropyrimidines and taxanes, oxaliplatin is rapidly cleared from plasma by binding to tissue and renal elimination [Graham *et al.* 2000; Jerremalm *et al.* 2009]. Urinary excretion ($53.8 \pm 9.1\%$) is

the major route of platinum elimination. In addition, oxaliplatin undergoes rapid and extensive nonenzymatic biotransformation [Graham *et al.* 2000]. The favorable pharmacokinetic profile makes oxaliplatin a systemic agent of particular interest in patients with liver dysfunction.

Clinical data on the use of systemic chemotherapy in hepatic dysfunction are limited, particularly for current standard combination regimen including monoclonal antibodies (moAbs). Available data mainly confer to small case series on the use of oxaliplatin in combination with infusional 5-FU or capecitabine for either metastatic colorectal (mCRC) or gastric cancer or single agent cetuximab [Fakih, 2004; Hwang *et al.* 2006; Walia *et al.* 2008; Mizota *et al.* 2011; Elsoueidi *et al.* 2014; Tural *et al.* 2014].

In order to establish a dose recommendation for administration of current combination regimen including moAbs, bi-institutional case series and a literature review was performed.

Materials and methods

Consecutive patients with severe liver dysfunction and hyperbilirubinemia ($>2 \times \text{ULN}$, >2.4 mg/dl) due to liver metastases of GI malignancies from two German institutions treated between August 2011 and April 2015 were analyzed for outcome, adverse events, liver function tests and blood count. Patients with hyperbilirubinemia were screened for options of internal or external biliary drainage by different imaging modalities (computed tomography, magnet resonance tomography or ultrasound) and discussed within the multidisciplinary tumor board. Only patients with hyperbilirubinemia caused by diffuse metastatic liver involvement after exclusion of further options for biliary drainage and no extrahepatic cholestasis were included in the analysis. Patients with known nonmalignant liver diseases like hepatitis, fibrosis or cirrhosis were excluded. The treatment had to contain any FP, folic acid (FA) and oxaliplatin with or without moAbs.

Patients were stratified into two groups according to the respective decrease in bilirubin levels following treatment.

Responders were defined as those with a reduction of bilirubin levels of at least 50% within the first 4–8 weeks or normalization up to week 12. The remaining patients were defined as nonresponders.

For the literature review relevant data from published trials, reports and abstracts presented at selected oncology association meetings [American Society of Clinical Oncology (ASCO), European Society for Medical Oncology (ESMO), European Cancer Organisation (ECCO)] and Medline/Pubmed until July 2015 were reviewed.

Results

Detailed results of the literature review are shown in Table 1. Overall 11 case reports or case series about hyperbilirubinemia in patients (a total of 26 patients) with GI cancers (25 with mCRC) and one with gastric cancer were found.

Elevated bilirubin levels due to liver metastases ranged from 2.6 mg/dl to 29.8 mg/dl before treatment start. The majority of patients ($n = 18$) had not undergone any prior systemic treatment. After treatment start, bilirubin decreased in 16 of 25 patients (missing $n = 1$). Only one patient with mCRC received an irinotecan based chemotherapy regimen (FOLFIRI), in combination with bevacizumab as first line treatment [Yeh *et al.* 2014]. In this patient initial bilirubin was 5.94 mg/dl and dropped to 0.78 mg/dl after 4 cycles; overall survival (OS) was 9 months.

Shitara and colleagues reported on seven heavily pretreated patients with mCRC treated with cetuximab alone [Shitara *et al.* 2010]. In these patients median bilirubin at treatment start was 7.4 mg/dl. In five of seven patients bilirubin dropped less than 50% of the initial value. Treatment with cetuximab alone was feasible, however outcome was poor with a median OS of 2.4 months.

Eighteen patients were treated with oxaliplatin-based chemotherapy regimens (with any FP; with or without moAb; no moAb: $n = 11$, bevacizumab: $n = 3$, cetuximab: $n = 1$, panitumumab: $n = 1$) [Fakih, 2004; Hwang *et al.* 2006; Walia *et al.* 2008; Grenader *et al.* 2009; Mizota *et al.* 2011; Terasawa *et al.* 2013; Elsoueidi *et al.* 2014; Tural *et al.* 2014; Kasi *et al.* 2015] with bilirubin ranged from 3.2–29.8 mg/dl at treatment start, that dropped in 14 patients by more than 50%. OS ranged from 1.5 months to 18 months. All treatment regimens were feasible without any severe toxicity (grade ≥ 3).

In our case series, 12 patients were identified (Table 2): 9 male and 3 female, with a median

age of 59 (range 46–74) years. Tumor types were colorectal ($n = 6$), biliary tract ($n = 5$) and gastroesophageal cancer ($n = 1$). In addition to diffuse liver metastases, they also presented lung ($n = 3$), bone ($n = 3$) and lymph node ($n = 6$) metastases. Before the malignant liver involvement none of the patients had any preexisting liver diseases. In all patients, drainage by stent placement or percutaneous transhepatic biliary drainage was evaluated and if feasible done before systemic treatment with 5-FU/FA, oxaliplatin \pm moAb. Thus, hyperbilirubinemia was solely caused by diffuse malignant liver infiltration with all other potential causes ruled out. Prior systemic chemotherapy, either in the adjuvant or metastatic setting, was administered in eight patients. In four patients 5-FU/FA, oxaliplatin \pm moAb was the firstline treatment.

Liver dysfunction was documented prior to systemic treatment (but after maximal drainage) by a median bilirubin level of 6.1 mg/dl (range 2.7–13.6 mg/dl), median alkaline phosphatase (AP) level of 571.0 U/l (range 192–938 U/l), median gamma-glutamyl transpeptidase (gGT) 422.75 U/l (range 165–1446 U/l), median glutamic-pyruvic transaminase (GPT) level of 76.0 U/l (range 29–283 U/l) and median level of glutamic-oxaloacetic transaminase (GOT) 140.0 U/l (range 82–441 U/l). Liver synthesis function was relevantly impaired, shown by low levels of albumin (median level of 31 g/l, range 20–38) and elevated international normalized ratio (INR) of prothrombin time (median 1.3, range 0.92–1.84).

Oxaliplatin was administered with infusional 5-FU/FA once a week ($n = 5$) or every two weeks ($n = 7$) or with capecitabine every three weeks ($n = 1$). Chemotherapy was combined with bevacizumab ($n = 4$), trastuzumab ($n = 1$) or cetuximab ($n = 1$).

Upfront dose reductions were applied in five patients for oxaliplatin (60–76% of full dose) and in 10 patients for 5-FU (0–77% of full dose). In one patient, treatment was started with fully dosed chemotherapy.

Only in one patient, a dose escalation of oxaliplatin to full standard doses was done. However, the weekly FUFOX regimen was changed to every two weeks FOLFOX in two patients. Escalation of 5-FU/FA to full standard doses was done within median 3.8 weeks, respectively. Individual dosing strategies are displayed in Table 2.

Table 1. Results of literature review.

	n	Tumor	Metastases	Prior treatment	Treatment	Bilirubin (mg/dl)		OS in months
						Before treatment	During/ after treatment	
Yeh <i>et al.</i> [2014]	1	colorectal	liver	no	4 cycles red FOLFIRI plus bevacizumab 5 mg/kg 8 cycles FOLFIRI plus bevacizumab 5 mg/kg	5.94	after 4 cycles: 0.78	9
Shitara <i>et al.</i> [2009, 2010]	7	colorectal	liver, lung, lymph node, peritoneum	yes	cetuximab mono	6.5 (mean level)	nk (no drop in 5 of 7 pts)	2.5 (mean OS)
Fakih [Fakih, 2004]	3	colorectal	liver	no	2 cycles red FOLFOX (Ox 60 mg/qm, LV 200 mg/qm, bolus 5-FU 300 mg/qm, 5-FU 46 h infusion 1800 mg/qm) 12 cycles FOLFOX	3.5	1.2	7
		colorectal	liver	no	1 cycle red FOLFOX (Ox 65 mg/qm, LV 400 mg/qm, 5-FU 46 h infusion 2000 mg/qm) 7 cycles FOLFOX	5.9	1.8	4
		sigmoid	liver	no	1 cycle red FOLFOX (Ox 85 mg/qm, LV 400 mg/qm, 5-FU 46 h infusion 2000 mg/qm) 10 cycles FOLFOX	4.2	1.3	ongoing
Hwang <i>et al.</i> [2006]	1	gastric	liver	yes	5 cycles Ox 130 mg/qm capecitabine 1000 mg/qm	10.9	2.1	ongoing
Walia <i>et al.</i> [2008]	6	colorectal	liver	no	FOLFOX (dose unknown)	16.2	0.6	9.4
		colorectal	liver	no	FOLFOX (dose unknown) + bevacizumab	27.7	2.5	2
		colorectal	liver	no	XELOX	6.2	no drop	0.8
		colorectal	liver	no	FOLFOX (dose unknown)	3.5	no drop	1.5
		colorectal	liver	no	FOLFOX (dose unknown)	12.5	3.0	nk
		colorectal	liver	no	FOLFOX (dose unknown)	6.5	5.7	2.4
		colorectal	liver	no	unknown	3.2	nk	nk
Elsoueidi <i>et al.</i> [2014]	1	colorectal	liver	no	21 cycles red FOLFOX (Ox 75 mg/qm, 5-FU Bolus 200 mg/qm, 5-FU 46 h infusion 1200 mg/qm q14) change to 19 cycles cetuximab weekly after progress	9.4 29.8	1.2 1.9	nk
Mizota <i>et al.</i> [2011]	1	colorectal	liver	no no	mFOLFOX6 + cetuximab	9.7	0.8	nk
Terasawa <i>et al.</i> [2013]	1	rectal	liver	no	mFOLFOX6 (80%) after 4 cycles escalated to mFOLFOX6 plus bevacizumab	15.6	0.8	nk
Tural <i>et al.</i> [2014]	1	colorectal	liver	no	oxaliplatin, after two weeks escalated to FOLFOX6	22.5	1.8	nk
Grenader <i>et al.</i> [2009]	1	colon	liver, lung	no	FP/FA (70% of de Gramont regimen) escalated to FOLFOX, after 4 weekly escalated with bevacizumab	11.2	0.6	nk
Kasi <i>et al.</i> [2015]	2	colorectal	liver	no	mFOLFOX7 plus panitumumab	9.4	18.4	1.5
		colorectal	liver	no	mFOLFOX7 plus bevacizumab (10 cycles) FOLFIRI, followed by FOLFOX plus cetuximab	8.4	3.9	18

5-FU, 5-Fluorouracil; nk, not known; red, reduced; LV, leucovorin; Ox, oxaliplatin; OS, overall survival; pts, patients.

Bilirubin levels dropped within 4–8 weeks or normalized within 12 weeks in six patients, (responders). The remaining six patients showed no

bilirubin response to systemic treatment (nonresponders). Responders compared with nonresponders were younger (median age of 55.5 years

Table 2. Bilirubin levels and individual dosing strategies of systemic treatment with oxaliplatin/ fluoropyrimidine, with or without moAbs.

	Tumor type (mets)	Gender (age)	Prior Tx	Tx	BL	Week												OS
						1	2	3	4	5	6	7	8	9	10	11	12	
1	Rectum (liver, bone)	m (66)	no	Bili Ox ¹ 5-FU ²	6.7 64 1.5	8.4 – –	– – –	– – –	– – –	12.5 – –	† † †	† † †	† † †	† † †	† † †	† † †	1.3	
2	Colon (liver, lung, bone)	m (66)	yes	Bili Ox ¹ 5-FU ² Bev ⁴	13.3 50 0 5	10.6 50 0 –	6.4 50 0 5	6.4 50 1.0 –	5.1 50 1.5 5	3.8 50 2.0 –	3.8 50 2.0 –	2.9 50 2.0 –	2.0 – † –	† † † †	† † † †	† † † †	2	
3	Colon (liver, lymph node)	m (62)	yes	Bili Ox ¹ 5-FU ² Cet ⁵	11.0 65 1.3 –	– – – –	10.6 65 0 –	9.3 – – –	9.6 70 1.5 –	7.5 – – 400	6.9 70 1.5 250	7.4 – – 250	6.1 70 1.5 250	7.6 – – 250	6.9 70 1.5 500	– – – –	8.2 85 1.5 500	5.8
4	Cholangio (liver)	m (55)	yes	Bili Ox ¹ 5-FU ²	10.8 50 1.0	– 50 1.0	– 50 1.0	– – –	7.5 50 1.0	– 50 1.0	– 50 1.0	– – –	4.2 50 1.0	– 50 1.0	– 50 1.0	– – –	1.4 50 1.0	16
5	Gall bladder (liver peritoneum)	m (56)	yes	Bili Ox ¹ 5-FU ² Tras ⁶	8.3 60 2.4 4	– – – –	– – – –	– – – –	6.8 60 2.4 4	– – – –	4.4 – – –	– – – –	2.3 80 2.4 4	1.2 – – –	1.3 – – –	– – – –	1.0 80 2.4 4	12
6	Colon (liver lymph nodes)	f (65)	yes	Bili Ox ¹ 5-FU ² Bev ⁴	13.6 75 1.8 5	– – – –	10.1 75 1.8 5	6.2 – – –	4.5 75 1.8 5	– – – –	2.8 75 1.8 5	– – – –	1.5 75 1.8 5	– – – –	– – – –	0.8 75 1.8 5	0.7 75 1.8 5	14
7	Colon (liver lung)	f (73)	no	Bili Ox ¹ 5-FU ² Bev ⁴	4.0 50 1.5 –	4.3 50 2.0 5	3.6 50 2.0 –	4.3 85 2.0 5	2.9 – – –	2.0 – – –	– – – –	– – – –	2.6 – – –	3.8 50 2.0 –	6.0 50 2.0 –	† † † †	2.5	
8	Colon (liver lymph node)	m (49)	no	Bili Ox ¹ 5-FU ² Bev ⁴	5.5 50 1.5 5	9.3 50 1.5 –	11.7 50 2.0 5	12.2 – – –	7.5 85 2.4 5	4.9 – – –	– 85 2.4 –	– 85 2.4 –	4.2 – – –	3.3 85 2.4 5	2.5 – – –	– 85 2.4 5	2.5 – – –	4.5
9	Cholangio (liver lymph node)	f (55)	yes	Bili Ox ¹ 5-FU ²	2.7 60 1.68	– 60 –	2.3 – 1.68	– 85 –	3.1 – 2.4	– 85 –	4.0 85 2.4	– 85 –	4.8 85 2.4	– 85 –	2.6 85 2.4	3.5 – –	4.5 85 2.4	10
10	Colon (liver, lung, lymph node)	m (74)	yes	Bili Ox ¹ 5-FU ²	3.1 50 1.5	2.3 50 1.5	– – –	– † †	– † †	– † †	– † †	– † †	– † †	– † †	– † †	– † †	– † †	1
11	Cholangio (liver, bone)	m (46)	yes	Bili Ox ¹ Cape ³	2.7 130 1.0	3.3 – 1.0	2.6 – 1.0	– – –	1.3 100 1.0	– – 1.0	– – 1.0	– – 1.0	1.8 100 1.0	1.8 – 1.0	– – 1.0	– – 1.0	1.6 100 1.0	7.5
12	Esophageal (liver, lymph node)	m (47)	no	Bili Ox ¹ 5-FU ²	3.6 85 1.3	– – –	1.4 85 1.95	– – –	0.8 85 1.95	– – –	0.6 85 2.6	– – –	0.6 85 2.6	– – –	0.9 85 2.6	– – –	0.9 85 2.6	6.5

†not application because of death.

Bev, Bevacizumab; Bili, bilirubin in mg/dl (normal value <1.2 mg/dl); BL, baseline; Cape, capecitabine; Cet, Cetuximab; f, female; FP, 5-Fluorouracil; m, male; mets, metastases; OS, overall survival; Ox, oxaliplatin; Tras, Trastuzumab; Tx, treatment.

¹Oxaliplatin was given as weekly FUFOX (oxaliplatin 50 mg/qm), every 2 weeks mFOLFOX6, FOLFOX7 or FLO (oxaliplatin 85 mg/qm) or FOLFOX6 (oxaliplatin 100 mg/qm); and every 3 weeks XELOX (oxaliplatin 130 mg/qm).

²5-FU (5-Fluorouracil) was given as FUFOX (24 h infusion; 2.0 g/qm) weekly; mFOLFOX6 (48 h infusion; 2.4 g/qm) every 2 weeks; FOLFOX7 (48 h infusion; 3.0 g/qm) every 2 weeks or FLO (24 h infusion, 2.6 g/qm).

³Capecitabine was given as CAPOX with 1000 mg/qm twice a day for 14 days.

⁴Bevacizumab, every 2 weeks with 5 mg/kg.

⁵Cetuximab, loading dose 400 mg/qm, weekly 250 mg/qm, every 2 weeks 500 mg/qm.

⁶Trastuzumab, 4 mg/kg.

versus 64 years) and had higher bilirubin levels at baseline (9.6 mg/dl *versus* 4.7 mg/dl).

Median overall survival after start of chemotherapy was overall 5.75 months (range 1.0–16.0 months) but was significantly longer in responders compared with nonresponders [median 9.7 and 3.0 months, $p = 0.026$ (two-sided test); 95% CI: 1.10–10.22]. Bilirubin level at treatment start was not correlated to response rate, side effects or survival. Comparing patients with and without the combination with moAb, median OS was 6.8 months and 6.5 months and thus not statistically different ($p = 0.92$).

Apart from severe nausea and emesis (grade 3) in one patient the treatment with 5-FU/FA, oxaliplatin with or without moAb was well tolerated, even after escalation to full dose. No correlation between the severity of liver dysfunction, hyperbilirubinemia and treatment tolerability was noted.

Discussion

The presented case series clearly demonstrate the feasibility of systemic treatment with oxaliplatin/fluoropyrimidine combinations, with or without moAbs. In regard to the low percentage of escalation to a full dose regimen, and the overall relatively poor outcome of these patients, a more aggressive dosing strategy and treatment intensity should be considered in eligible patients, as outcome may be correlated to adequate dosage. Similarly, recent guidelines (e.g. in mCRC) recommend an upfront rather intensive treatment approach in the case of symptomatic or rapid progressive disease (ESMO group 2), as commonly applies for patients with hyperbilirubinemia [Schmoll *et al.* 2012]. However, choosing an intensive approach with a quick dose escalation might not be feasible for all patients and harmful. Therefore, a cautious pretreatment evaluation is important. In case of an underlying not cancer-associated reduced ECOG performance status (PS) of two or more or a far advanced and already heavily pretreated disease, the suggested approach may not be reasonable.

Of note, patients without bilirubin response after 4–8 weeks do not seem to derive any benefit from systemic treatment and may thus receive early treatment discontinuation and referral to best supportive care. In contrast, patients responding to treatment as shown by an early decline in bilirubin levels may have a longer survival.

The addition of moAbs was feasible, which seems to be in line with the known pharmacokinetics in these drugs [Lu *et al.* 2008; Azzopardi *et al.* 2011; Zhi *et al.* 2011]. As recently shown, epidermal growth factor receptor (EGFR) antibodies seem to be of particular interest in terms of application as single agent or in combination in RAS wildtype mCRC with severe liver dysfunction [Shitara *et al.* 2009; Mizota *et al.* 2011; Kasi *et al.* 2015].

The current case series and the respective analyses are limited by the small number of patients, the retrospective character and the evaluation of patients from only two centers. Therefore, a review of literature was performed to collect further case series.

Based on the published data and our case series, we suggest the following treatment algorithm for patients with GI cancer and severe liver dysfunction (Figure 1).

In case of elevated levels of bilirubin ($>2 \times$ ULN) due to liver metastases, the option for interventional drainage should be evaluated first. If bilirubin remains high (or drainage is technically not possible) and ECOG PS is adequate, systemic treatment should be started with a dose-reduced regimen, preferably FUFOX weekly, with the doses of oxaliplatin 50 mg/qm (100%), FA 500 mg/qm (100%) and 5-FU 1500 mg/qm (75% of the original dosage) for the first application [Grothey *et al.* 2002]. If treatment is well tolerated, dosages should also be elevated to 100 (2000 mg/qm) given for the second application. Thereafter, a switch to a biweekly regimen with higher single doses (like FOLFOX) is possible. The combination with moAbs is feasible and may thus be considered in eligible patients to increase efficacy in this poor prognosis patient population.

Conclusion

Liver dysfunction resulting from liver metastases in patients with GI malignancies should not lead to therapeutic nihilism. In contrary, these patients may derive relevant benefit from chemotherapy with FA and oxaliplatin with or without the addition of a moAbs. Careful upfront patient selection based on ECOG PS, comorbidity and disease characteristics is important to identify patients able to still tolerate such an aggressive treatment approach. In regard of the limited data further studies are necessary. The recommended

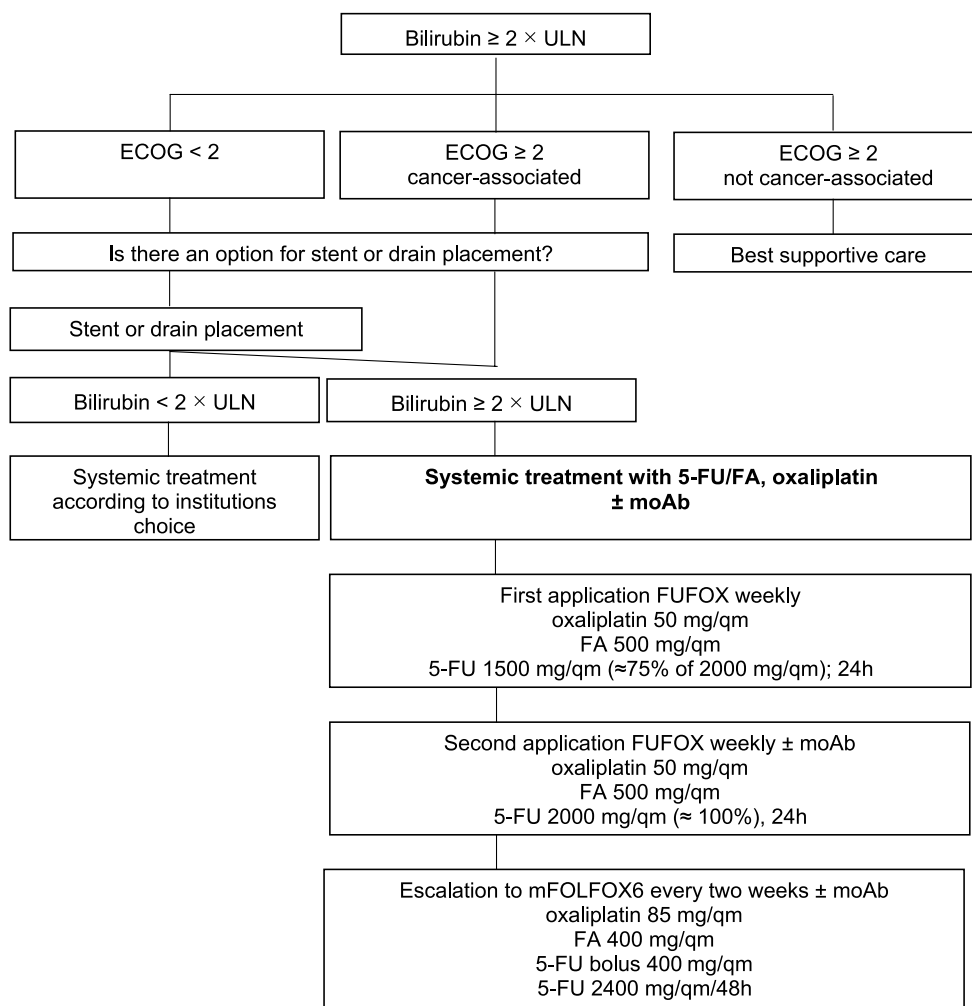


Figure 1. Treatment algorithm for patients with GI cancer and severe liver dysfunction.

approach will further be evaluated in a prospective registry.

Funding

This research received no specific grant from any funding agency in the public, commercial, or not-for-profit sectors.

Conflict of interest statement

The authors declare that there is no conflict of interest.

References

Azzopardi, N., Lecomte, T., Ternant, D., Boisdron-Celle, M., Piller, F., Morel, A. *et al.* (2011) Cetuximab pharmacokinetics influences progression-free survival of metastatic colorectal cancer patients. *Clin Cancer Res* 17: 6329–6337.

Bruno, R., Vivier, N., Veyrat-Follet, C., Montay, G. and Rhodes, G. (2001) Population pharmacokinetics and pharmacokinetic-pharmacodynamic relationships for docetaxel. *Invest New Drugs* 19: 163–169.

Eckmann, K., Michaud, L., Rivera, E., Madden, T., Esparza-Guerra, L., Kawedia, J. *et al.* (2014) Pilot study to assess toxicity and pharmacokinetics of docetaxel in patients with metastatic breast cancer and impaired liver function secondary to hepatic metastases. *J Oncol Pharm Pract* 20: 120–129.

Elsoueidi, R., Craig, J., Mourad, H. and Richa, E. (2014) Safety and efficacy of FOLFOX followed by cetuximab for metastatic colorectal cancer with severe liver dysfunction. *J Natl Compr Canc Netw* 12: 155–160.

Fakih, M. (2004) 5-Fluorouracil leucovorin and oxaliplatin (FOLFOX) in the treatment of metastatic colon cancer with severe liver dysfunction. *Oncology* 67: 222–224.

- Ferlay, J., Soerjomataram, I., Dikshit, R., Eser, S., Mathers, C., Rebelo, M. *et al.* (2014) Cancer incidence and mortality worldwide: sources, methods and major patterns in globocan 2012. *Int J Cancer* 136: E359–E386.
- Gagne, J., Montminy, V., Belanger, P., Journault, K., Gaucher, G. and Guillemette, C. (2002) Common human UGT1A polymorphisms and the altered metabolism of irinotecan active metabolite 7-ethyl-10-hydroxycamptothecin (SN-38). *Mol Pharmacol* 62: 608–617.
- Graham, M., Lockwood, G., Greenslade, D., Brienza, S., Bayssas, M. and Gamelin, E. (2000) Clinical pharmacokinetics of oxaliplatin: a critical review. *Clin Cancer Res* 6: 1205–1218.
- Grenader, T., Goldberg, A. and Gabizon, A. (2009) Combination therapy with oxaliplatin and 5-fluorouracil in a patient with severe hepatic dysfunction associated with metastatic adenocarcinoma of the large bowel. *Anticancer Drugs* 20: 845–847.
- Grothey, A., Deschler, B. and Kroening, H. (2002) Phase III study of bolus 5-fluorouracil (5-FU)/folinic acid (FA) (Mayo) vs weekly high-dose 24H 5-FU infusion/FA + oxaliplatin (OXA) (FUFOX) in advanced colorectal cancer (ACRC). *Proc Am Soc Clin Oncol* 21: 129a (abstract 512).
- Hooker, A., Ten Tije, A., Carducci, M., Weber, J., Garrett-Mayer, E., Gelderblom, H. *et al.* (2008) Population pharmacokinetic model for docetaxel in patients with varying degrees of liver function: incorporating cytochrome P4503a activity measurements. *Clin Pharmacol Ther* 84: 111–118.
- Hwang, S., Park, J., Lee, S., Kim, G., Sin, C., Nam, S. *et al.* (2006) Capecitabine and oxaliplatin (XELOX) for the treatment of patients with metastatic gastric cancer and severe liver dysfunction. *Korean J Intern Med* 21: 252–255.
- Jerremalm, E., Wallin, I. and Ehrsson, H. (2009) New insights into the biotransformation and pharmacokinetics of oxaliplatin. *J Pharm Sci* 98: 3879–3885.
- Kasi, P., Thanarajasingam, G., Finnes, H., Villasboas Bisneto, J., Hubbard, J. and Grothey, A. (2015) Chemotherapy in the setting of severe liver dysfunction in patients with metastatic colorectal cancer. *Case Rep Oncol Med* 2015: 420159.
- Lu, J., Bruno, R., Eppler, S., Novotny, W., Lum, B. and Gaudreault, J. (2008) Clinical pharmacokinetics of bevacizumab in patients with solid tumors. *Cancer Chemother Pharmacol* 62: 779–786.
- Minami, H., Kawada, K., Sasaki, Y., Tahara, M., Igarashi, T., Itoh, K. *et al.* (2009) Population pharmacokinetics of docetaxel in patients with hepatic dysfunction treated in an oncology practice. *Cancer Sci* 100: 144–149.
- Mizota, A., Shitara, K., Kondo, C., Nomura, M., Yokota, T., Takahari, D. *et al.* (2011) FOLFOX plus cetuximab for a patient with metastatic colorectal cancer with icterus due to multiple liver metastases. *Gan To Kagaku Ryoho* 38: 1205–1208.
- Rivory, L. and Robert, J. (1995) Identification and kinetics of a beta-glucuronide metabolite of SN-38 in human plasma after administration of the camptothecin derivative irinotecan. *Cancer Chemother Pharmacol* 36: 176–179.
- Saif, M. and Tejani, M. (2007) Safety of capecitabine use in patients with liver dysfunction. *Clin Adv Hematol Oncol* 5: 730–732; discussion 736.
- Schalhorn, A. and Kuhl, M. (1992) Clinical pharmacokinetics of fluorouracil and folinic acid. *Semin Oncol* 19: 82–92.
- Schilsky, R. (1998) Biochemical and clinical pharmacology of 5-fluorouracil. *Oncology (Williston Park)* 12: 13–18.
- Schmoll, H., Van Cutsem, E., Stein, A., Valentini, V., Glimelius, B., Haustermans, K. *et al.* (2012) ESMO consensus guidelines for management of patients with colon and rectal cancer. A personalized approach to clinical decision making. *Ann Oncol* 23: 2479–2516.
- Shitara, K., Takahari, D., Yokota, T., Shibata, T., Ura, T., Muro, K. *et al.* (2010) Case series of cetuximab monotherapy for patients with pre-treated colorectal cancer complicated with hyperbilirubinemia due to severe liver metastasis. *Jpn J Clin Oncol* 40: 275–277.
- Shitara, K., Yokota, T. and Utsunomiya, S. (2009) Cetuximab for patients with colon cancer and hepatic metastasis complicated by liver dysfunction and icterus. *Gastrointest Cancer Res* 3: 171–172.
- Terasawa, T., Koja, S., Yasuda, K. and Fukuda, K. (2013) A case of metastatic colorectal cancer with icterus due to multiple liver metastases treated effectively by FOLFOX plus bevacizumab. *Gan To Kagaku Ryoho* 40: 1115–1118.
- Tural, D., Akar, E., Ozturk, M., Yildiz, O., Turna, H. and Serdengeci, S. (2014) Severe liver dysfunction and safe use of 5-fluorouracil leucovorin and oxaliplatin in one patient with metastatic colorectal carcinoma. *J Cancer Res Ther* 10: 745–748.
- Twelves, C., Glynne-Jones, R., Cassidy, J., Schuller, J., Goggin, T., Roos, B. *et al.* (1999) Effect of hepatic dysfunction due to liver metastases on the pharmacokinetics of capecitabine and its metabolites. *Clin Cancer Res* 5: 1696–1702.


Walia, T., Quevedo, J., Hobday, T., Croghan, G. and Jatoi, A. (2008) Colorectal cancer patients with liver metastases and severe hyperbilirubinemia: a consecutive series that explores the benefits and risks of chemotherapy. *Ther Clin Risk Manag* 4: 1363–1366.

Yeh, Y., Huang, M., Chang, S., Chen, C., Hu, H. and Wang, J. (2014) FOLFIRI combined with bevacizumab as first-line treatment for metastatic colorectal cancer patients with hyperbilirubinemia

after UGT1A1 genotyping. *Med Princ Pract* 23: 478–481.

Zhi, J., Chen, E., Major, P., Burns, I., Robinson, B., Mckendrick, J. *et al.* (2011) A multicenter, randomized, open-label study to assess the steady-state pharmacokinetics of bevacizumab given with either XELOX or FOLFOX-4 in patients with metastatic colorectal cancer. *Cancer Chemother Pharmacol* 68: 1199–1206.

Visit SAGE journals online
<http://tam.sagepub.com>

 SAGE journals