

## Case 1462

### Absence of the infra-renal segment of the inferior vena cava

C. Oliveira, S. Vinhais, T. M. Cunha

INSTITUTO PORTUGUÊS DE ONCOLOGIA de Francisco Gentil de LISBOA

**Section:** Vascular Imaging

**Published:** 2002, May. 29

**Patient:** 59 year(s), female

## Clinical Summary

---

A CT examination for assessment of a neoplastic disease, disclosed a rare vascular anatomical variant.

## Clinical History and Imaging Procedures

---

Following diagnosis of fibrosarcoma of the right arm, the patient underwent a contrast-enhanced CT examination for the detection of disseminated disease. Although there was no evidence of secondary disease, absence of the infra-renal segment of the inferior vena cava was detected as an incidental finding. A pancreatic tumoral lesion was also found.

## Discussion

---

Formation of the inferior vena cava (IVC) is a complex process that involves multiple steps. Three entire venous systems develop (supracardinal, sub-cardinal and posterior cardinal) and selectively regress to complete formation of the inferior vena cava and its large tributaries. Caval development begins in the sixth week of fetal life and progresses rapidly, with formation of all three precursor venous systems by the eighth week.

Many different anomalies are described, usually as incidental and infrequent findings: left-sided IVC, double IVC, azygos continuation of the IVC, circumaortic left renal vein, retroaortic left renal vein, circuncaval ureter, absence of the entire IVC and finally, absence of the infra-renal segment of the IVC when there is selective injury to the supracardinal system. Recognition of these anatomical variants can avoid significant morbidity during abdominal surgical procedures, liver or renal transplantation, placement of caval filters and varicocele sclerotherapy. Agenesis of the infra-renal segment of the IVC is a

rare anomaly (15 cases described by imagiology in the english language literature between 1957 and 1999). Of these, only two reports described persistence of the suprarenal segment, such as in this case.

Absence of the IVC was found to be associated with 5% of cases of deep venous thrombosis in patients below 30 years of age, thus representing a rare risk factor for idiopathic deep venous thrombosis.

In this particular case, CT was sufficient for diagnosis. Angiography, which remains the most accurate diagnostic technique, may provide further characterisation of these malformations.

## Final Diagnosis

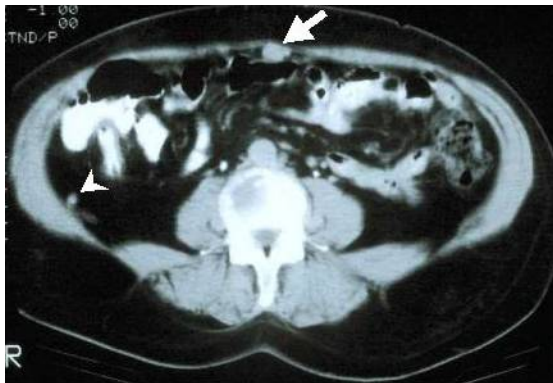---

Absence of the infra-renal segment of the inferior vena cava

## Figures

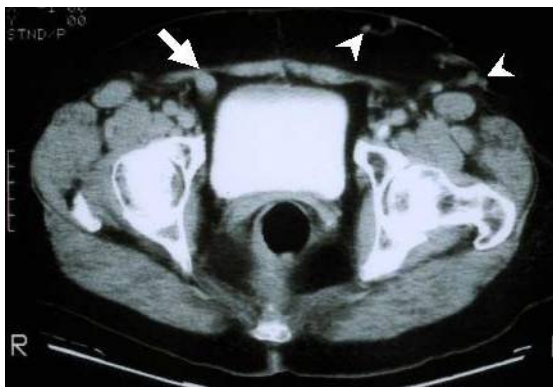---

**Figure 1**



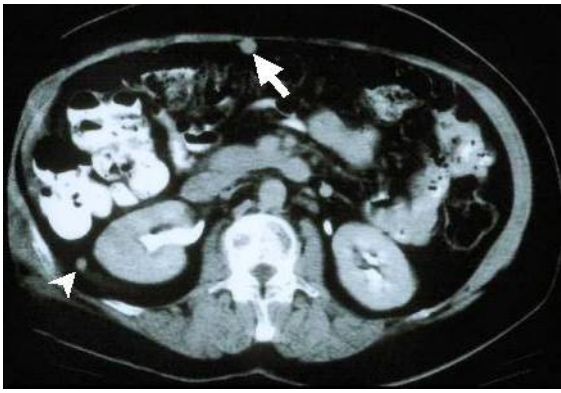Contrast-enhanced CT scan 1cm above the aorta bifurcation showing absence of the inferior vena cava. Collateral circulation has developed through an ingurgitated umbilical vein (white arrow) and through a retroperitoneal vein (arrowhead).

**Figure 2**

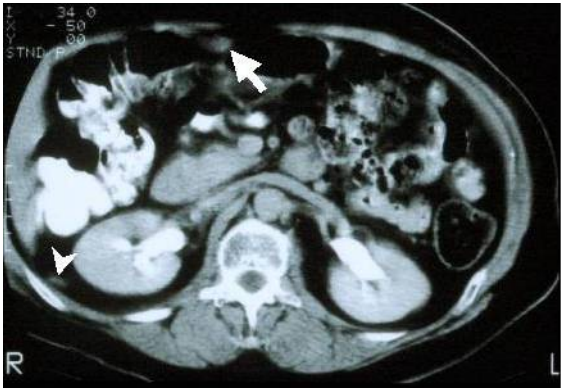

Pelvic contrast-enhanced CT showing an ingurgitated right inferior epigastric vein (white arrow). Dilated left superficial epigastric and thoracoepigastric veins are also shown (arrowheads).

**Figure 3**

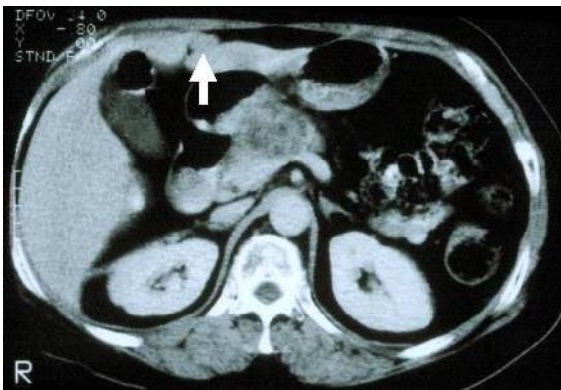


Abdominal contrast-enhanced CT: reperfusion of the umbilical vein (white arrow). Venous drainage of the lower body also occurs through a dilated retroperitoneal vein (arrowhead).



Abdominal contrast-enhanced CT: confluence of both renal veins at the origin of the supra-renal segment of the inferior vena cava. Reperfusion of the umbilical vein (white arrow) is seen. The right retroperitoneal vein is also shown here (arrowhead).

**Figure 4**



Abdominal contrast-enhanced CT. In this scan, the right retroperitoneal vein shows an axial course, entering the inferior vena cava. Reperfusion of the umbilical vein (white arrow) is seen. As an incidental finding a pancreatic tumoral lesion was demonstrated.

## MeSH

### Vena Cava, Inferior [A07.231.908.949.648]

The venous trunk which receives blood from the lower extremities and from the pelvic and abdominal organs.

## References

[1] Bass JE, Redwine MD, Kramer LA, Huynh PT, Harris JH Jr. Spectrum of congenital anomalies of the inferior vena cava: cross-sectional imaging findings. Radiographics 2000 May-Jun;20(3):639-52.

[2] Bass JE, Redwine MD, Kramer LA, Harris JH Jr. Absence of the inferior vena cava with preservation of the suprarenal segment as revealed by CT and MR venography. *AJR Am J Roentgenol* 1999 Jun;172(6):1610-12.

[3] Pirenne J, Benedetti E, Kashtan CE, Lledo-Garcia E, Hakim N, Schroeder CH, Cook M, Sutherland DE, Matas AJ, Najarian JS. Kidney transplantation in the absence of the infrarenal vena cava. *Transplantation* 1995 Jun 27;59(12):1739-42.

[4] Ruggeri M, Tosetto A, Castaman G, Rodeghiero F. Congenital absence of the inferior vena cava: a rare risk factor for idiopathic deep-vein thrombosis. *Lancet* 2001 Feb 10;357(9254):441.

## Citation

---

C. Oliveira, S. Vinhais, T. M. Cunha (2002, May. 29)

**Absence of the infra-renal segment of the inferior vena cava {Online}**

URL: <http://www.eurorad.org/case.php?id=1462>