


This article was downloaded by:[Guerra, Adalgisa]
On: 24 June 2008
Access Details: [subscription number 794230680]
Publisher: Informa Healthcare
Informa Ltd Registered in England and Wales Registered Number: 1072954
Registered office: Mortimer House, 37-41 Mortimer Street, London W1T 3JH, UK



Acta Radiologica

Publication details, including instructions for authors and subscription information:
<http://www.informaworld.com/smpp/title~content=t713394674>

Magnetic Resonance Evaluation of Adnexal Masses

A. Guerra^{abc}, T. M. Cunha^{abc}, A. Félix^{abc}

^a Department of Radiology, Hospital Pulido Valente, Lisbon, Portugal

^b Department of Radiology, Instituto Português de Oncologia de Francisco Gentil, Lisbon, Portugal

^c Department of Pathology, Instituto Português de Oncologia de Francisco Gentil, Lisbon, Portugal

First Published: 2008

To cite this Article: Guerra, A., Cunha, T. M. and Félix, A. (2008) 'Magnetic Resonance Evaluation of Adnexal Masses', Acta Radiologica, 49:6, 700 — 709

To link to this article: DOI: 10.1080/02841850802064995

URL: <http://dx.doi.org/10.1080/02841850802064995>

PLEASE SCROLL DOWN FOR ARTICLE

Full terms and conditions of use: <http://www.informaworld.com/terms-and-conditions-of-access.pdf>

This article maybe used for research, teaching and private study purposes. Any substantial or systematic reproduction, re-distribution, re-selling, loan or sub-licensing, systematic supply or distribution in any form to anyone is expressly forbidden.

The publisher does not give any warranty express or implied or make any representation that the contents will be complete or accurate or up to date. The accuracy of any instructions, formulae and drug doses should be independently verified with primary sources. The publisher shall not be liable for any loss, actions, claims, proceedings, demand or costs or damages whatsoever or howsoever caused arising directly or indirectly in connection with or arising out of the use of this material.

Magnetic Resonance Evaluation of Adnexal Masses

A. GUERRA, T. M. CUNHA & A. FÉLIX

Department of Radiology, Hospital Pulido Valente, Lisbon, Portugal; Department of Radiology, Instituto Português de Oncologia de Francisco Gentil, Lisbon, Portugal; Department of Pathology, Instituto Português de Oncologia de Francisco Gentil, Lisbon, Portugal

Guerra A, Cunha TM, Félix A. Magnetic resonance evaluation of adnexal masses. *Acta Radiol* 2008;49:700–709.

Background: Accurate evaluation of adnexal masses allows correct surgical procedure, avoiding unnecessary surgery.

Purpose: To evaluate the accuracy of magnetic resonance imaging (MRI) in the diagnosis of malignancy of adnexal lesions.

Material and Methods: We retrospectively reviewed the pelvic MRI scans of 161 patients with 199 surgically confirmed adnexal masses, between November 1998 and June 2005. The criteria for adnexal malignancy were contrast-enhanced solid lesions, contrast-enhanced solid components in mixed lesions (except those with low-signal-intensity solid components on T2-weighted imaging [T2WI]), contrast-enhanced papillary projections in cystic lesions (except those with low-signal-intensity papillary projections on T2WI), or septal thickness ≥ 3 mm. Ascites, peritoneal metastasis, and pelvic adenopathy were also regarded as criteria for malignancy.

Results: On MRI evaluation, 97 adnexal lesions were malignant and 102 were non-malignant. Thirty-two percent of patients with ascites had benign lesions. Histopathologic evaluation of the adnexal lesions showed that 83 were malignant (true positives), 100 were non-malignant (true negatives), and seven were uncertain malignant potential tumors; two were false negative and seven were false positive. The MRI sensitivity and specificity for malignancy were 98% and 93%, respectively. MRI reached an accuracy of 95%, with a positive predictive value of 0.92 and a negative predictive value of 0.98 for malignant adnexal lesions. The kappa coefficient was 0.906, indicating almost perfect agreement between MRI and histological results.

Conclusion: MRI is an accurate method for evaluating the malignancy of adnexal lesions.

Key words: Adnexal masses; genital; magnetic resonance imaging; ovarian tumor; pelvis

Adalgisa Guerra, Largo Maria Leonor 12 14A, 1495-144, Miraflores, Lisboa, Portugal (fax. +351 243679942, e-mail. gisaguerra@gmail.com)

Accepted for publication February 28, 2008

Ovarian cancer is the second most common gynecologic malignancy, and is the leading cause of death concerning gynecologic tumors (1). The majority of women with ovarian cancer present at an advanced stage of disease, largely because there are no apparent signs or symptoms at earlier stages (1). Screening examinations, including imaging modalities, are important for the early detection and evaluation of adnexal lesions. As adnexal masses are commonly found, the main goal of imaging should be the evaluation and characterization of the lesions in order to differentiate malignant from non-malignant tumors. Transvaginal ultrasonography (TVUS) should be the first imaging approach for adnexal lesions (2), which allows

specific diagnosis in the majority of cases (3). However, magnetic resonance imaging (MRI) is superior in the characterization of adnexal masses (4) and should be used to further characterize indeterminate adnexal mass identified by US (5). Previous imaging studies have reported accuracies in the characterization of malignancy of adnexal masses ranging from 60 to 95% for US (4, 6, 7) and from 83 to 94% for MRI (3, 4, 7–13); the lower figure of 83% is from a relatively early pioneer study using older equipment (3).

Reported MR imaging criteria for the diagnosis of adnexal malignant tumors include mass size larger than 4 cm, predominantly solid lesions, the presence of necrosis on contrast-enhanced solid lesions,

contrast-enhanced papillary projections, or septal thickness ≥ 3 mm in cystic lesions, and bilaterality (8, 14). The presence of ascites, peritoneal metastasis, pelvic adenopathy, and the continuous spread of the adnexal lesion to adjacent organs or the pelvic wall are also helpful criteria in the diagnosis of a malignant tumor or in cases where it is suspected (8). Adnexal lesions with signals characteristic of fat, blood, or cyst without enhancement are reported as benign lesions (15).

Our aim was to evaluate the accuracy of MRI in the diagnosis of malignancy of adnexal lesions. In order to determine the accuracy of MRI, we classified the adnexal lesions as malignant and non-malignant using MR, and compared this with the final histological diagnoses.

Material and Methods

We retrospectively reviewed data concerning the pelvic MRI exams of 161 patients with 199 adnexal lesions that underwent surgery at our hospital between November 1998 and June 2005. The mean patient age was 50.5 years (range 15–83 years). In this study, lesions of ovarian and extra-ovarian origin, such as the fallopian tube and peritoneum, were included. The vast majority of the adnexal masses were ovarian in origin.

The pelvic MRI studies were performed, according to the guidelines of our hospital, for the characterization of indeterminate adnexal mass identified by US. Patient case notes included reports of previous US and, occasionally, clinical reports.

MRI examinations were performed using a 1.0-Tesla superconducting unit (Gyrosan NT10; Philips Medical Systems, Eindhoven, The Netherlands) with a pelvic phased-array coil. All examinations were carried out according to the following imaging protocol: T1-weighted transverse turbo spin-echo (repetition time/echo time [TR/TE] 550/14 ms), T2-weighted transverse and sagittal turbo spin-echo (TR/TE 4000/90 ms), and T1-weighted transverse turbo spin-echo sequences were carried out immediately after completing the administration of 0.2 mmol/kg gadopentetate dimeglumine (Magnevist; Schering, Berlin, Germany), with a fat-suppression technique, a matrix of 256×256 , 5-mm slice thickness, and 1-mm interslice gap. All transverse planes were acquired from the aortic bifurcation to the ischial tuberosity. If a large tumor was detected, the pelvic MRI study was extended to the rest of the abdomen to cover the entire lesion. Dynamic studies were not performed.

All patients fasted for 6 hours before the examination, and 20 mg of intramuscular hyoscine butylbromide (Buscopan; Boehringer, Germany) was given to reduce motion artifacts by bowel movements.

MR imaging analysis

MRI readings were carried out by a senior radiologist (T.M.C.) with experience in pelvic MRI and a radiologist in training (A.G.). All images were saved on film, and were retrospectively reviewed and consensually evaluated by both. All adnexal lesions were analyzed and classified according to the following criteria: contrast-enhanced solid lesions, contrast-enhanced solid components in mixed lesions (except those with low-signal-intensity solid components on T2-weighted images), contrast-enhanced papillary projections in cystic lesions (except those with low-signal-intensity papillary projections on T2-weighted images), or septal thickness ≥ 3 mm. The presence of ascites, peritoneal metastasis, and pelvic adenopathies was also an ancillary criterion for malignancy; otherwise, lesion size and bilaterality were not regarded as criteria for malignancy.

Adnexal lesions were classified into three types: cystic, solid, or mixed lesions with malignant or non-malignant features according to the following characteristics.

- a. Lesions were considered cystic if they had low to slightly high signal intensity on T1-weighted images and high signal intensity on T2-weighted images compared with urine, and were classified as malignant cystic lesions if there were contrast-enhanced papillary projections (Fig. 1) or septal thickness ≥ 3 mm (Fig. 2), except those with low-signal-intensity papillary projections on T2-weighted images. The identification of blood was carried out based on signal intensity characteristics on T1- and T2-weighted images. When a cystic lesion had variable signal intensity on T1-weighted images and high signal intensity on T2-weighted images without contrast enhancement, it was considered a high-protein-content or subacute hemorrhagic cyst. The diagnosis of endometrioma was given if the cystic lesion had high signal intensity on T1-weighted images with loss of signal intensity on T2-weighted images (“shading”). The diagnosis of a mature teratoma was given when fatty tissue was identified.

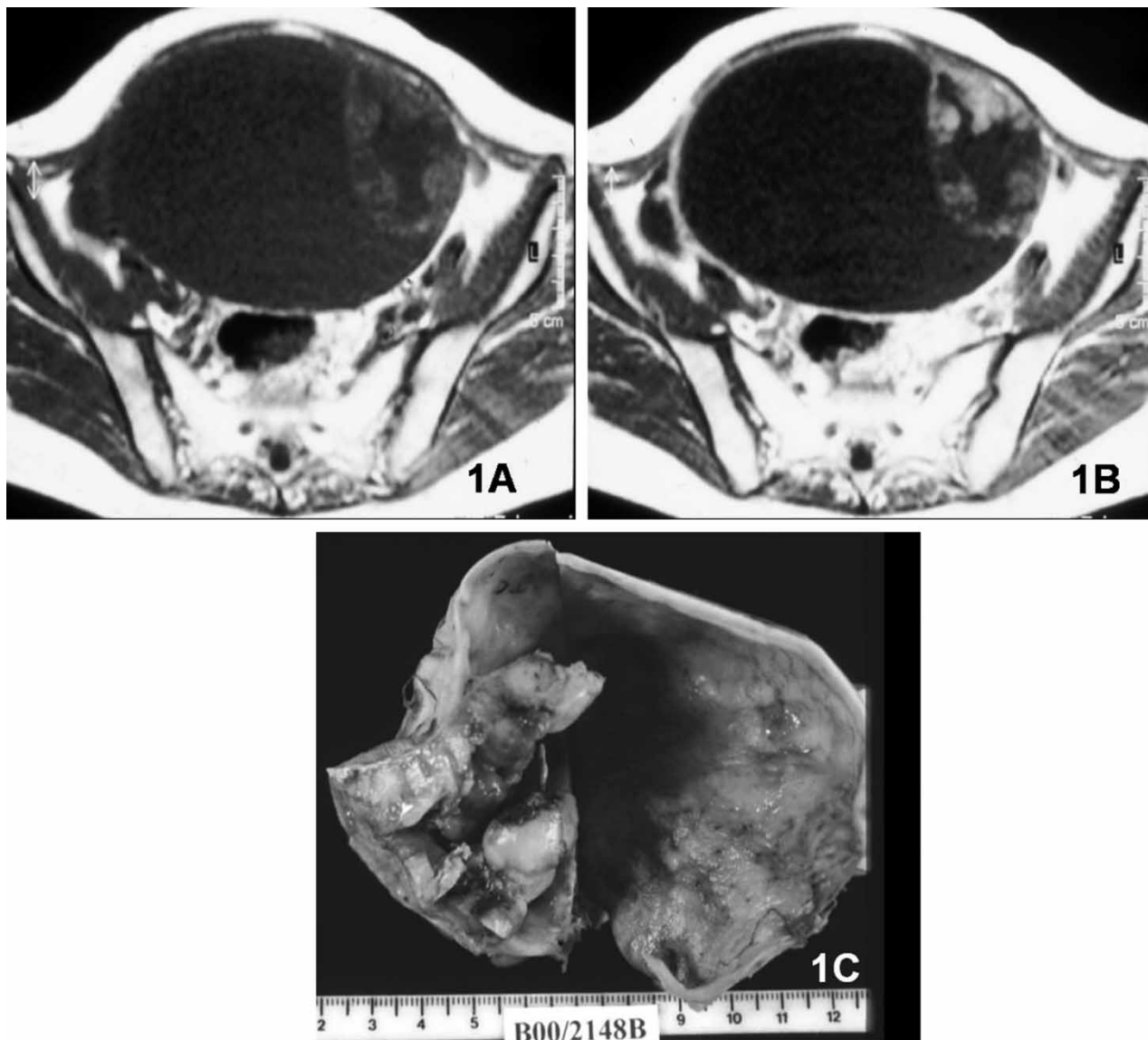


Fig. 1. Clear-cell carcinoma. A. Large cystic right adnexal lesion with intermediate-signal-intensity solid papillary projections and a thick septum on axial T1-weighted MR image. B. On contrast-enhanced axial T1-weighted image, the papillary projections and the septum show contrast enhancement. C. Gross specimen section of right oophorectomy.

- b. Lesions were considered solid if they had variable signal intensity on T1- and T2-weighted images and showed enhancement after contrast with or without areas of necrosis. All contrast-enhanced solid lesions were considered malignant, except those with low signal intensity on T2-weighted images.
- c. Lesions were considered mixed if they had solid and cystic components in harmonious portions (Fig. 3). All these lesions were considered malignant, except those with low-signal-intensity solid components on T2-weighted images (Fig. 4). If the lesion had a

predominantly cystic component with a negligible enhanced solid component, it was considered as cystic with papillary projection. If the lesion had a predominantly enhanced solid component with a negligible cystic area, it was considered as solid with areas of necrosis/cystic areas.

Mixed, solid, or cystic lesions with very-low-signal-intensity solid components on T2-weighted images (like striate muscle) were considered as benign tumors with fibrous components (16–19). Lesion size >4 cm as a malignant criterion was not

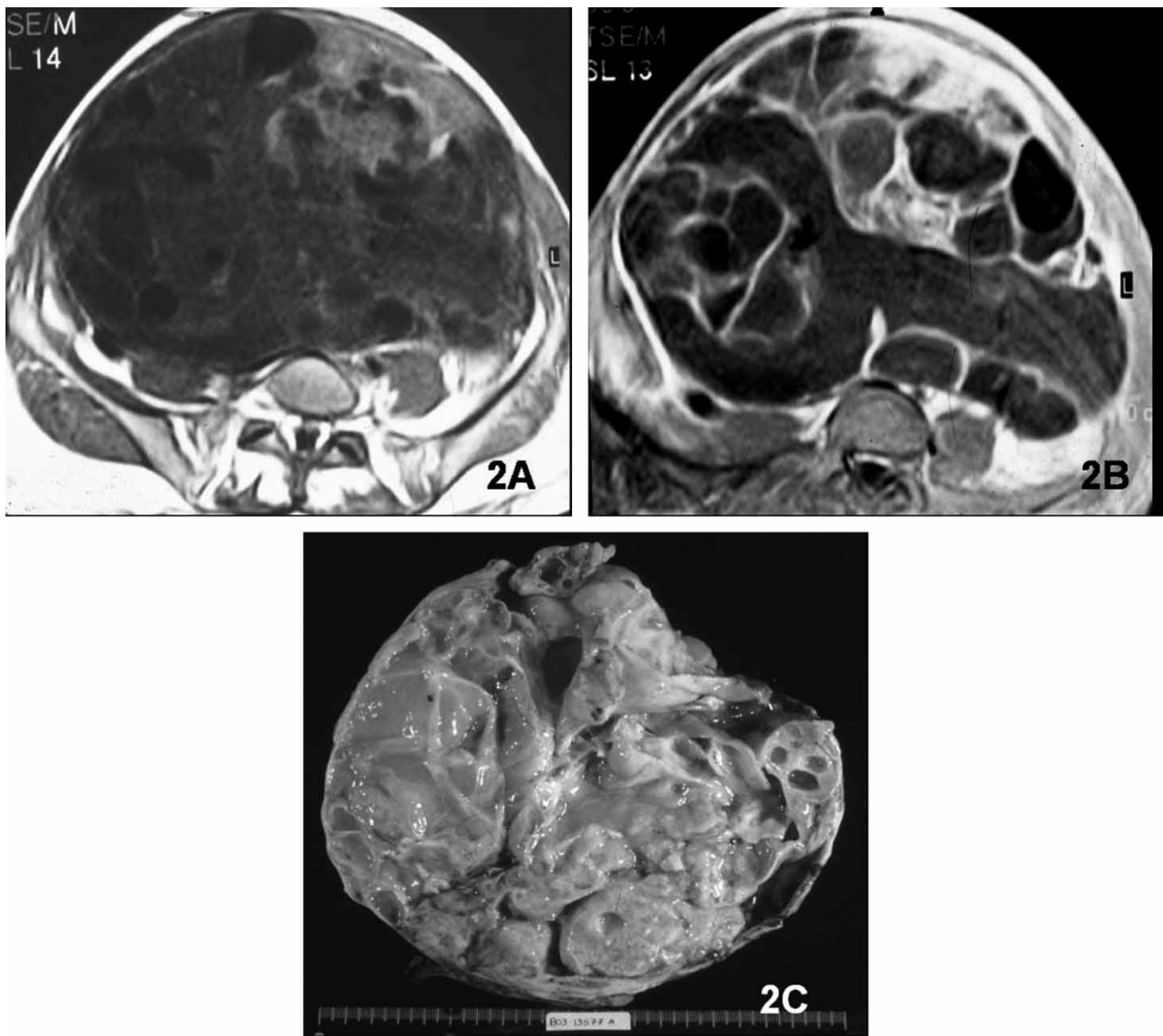


Fig. 2. Mucinous borderline tumor. A. Large multiloculated right adnexal cystic mass shows heterogeneous signal intensity with thick septa on axial T1-weighted MR image. B. On contrast-enhanced fat-suppressed axial T1-weighted image, the wall and septa of the mass show contrast enhancement. C. Gross specimen section of right oophorectomy.

included if it did not contribute to further prediction of malignancy when combined with other imaging findings (9). Neither did we use bilaterality as a criterion of malignancy, because it occurs in both malignant and benign lesions, and it is mainly related to specific histological types (5, 10).

Histological analysis

Histological reports were also evaluated, and if there was any doubt concerning the histological diagnosis, the specimen was reviewed by a pathologist (A.F.) with experience in gynecological pathology. Using the World Health Organization (WHO) classifica-

tion of tumors of female genital organs (20) for the histological diagnosis, adnexal lesions were divided into three groups: malignant, non-malignant, and uncertain malignant potential tumors. All malignant neoplasms and borderline tumors were included as malignant tumors. All benign lesions, as well as functional ovarian cysts, peritoneal inclusion cysts, and adnexal inflammatory lesions, were grouped and classified as non-malignant lesions. The remaining tumors were classified as uncertain malignant potential tumors.

The MRI results (malignant/non-malignant) were classified as correct or not correct according to the final histological diagnoses (malignant/

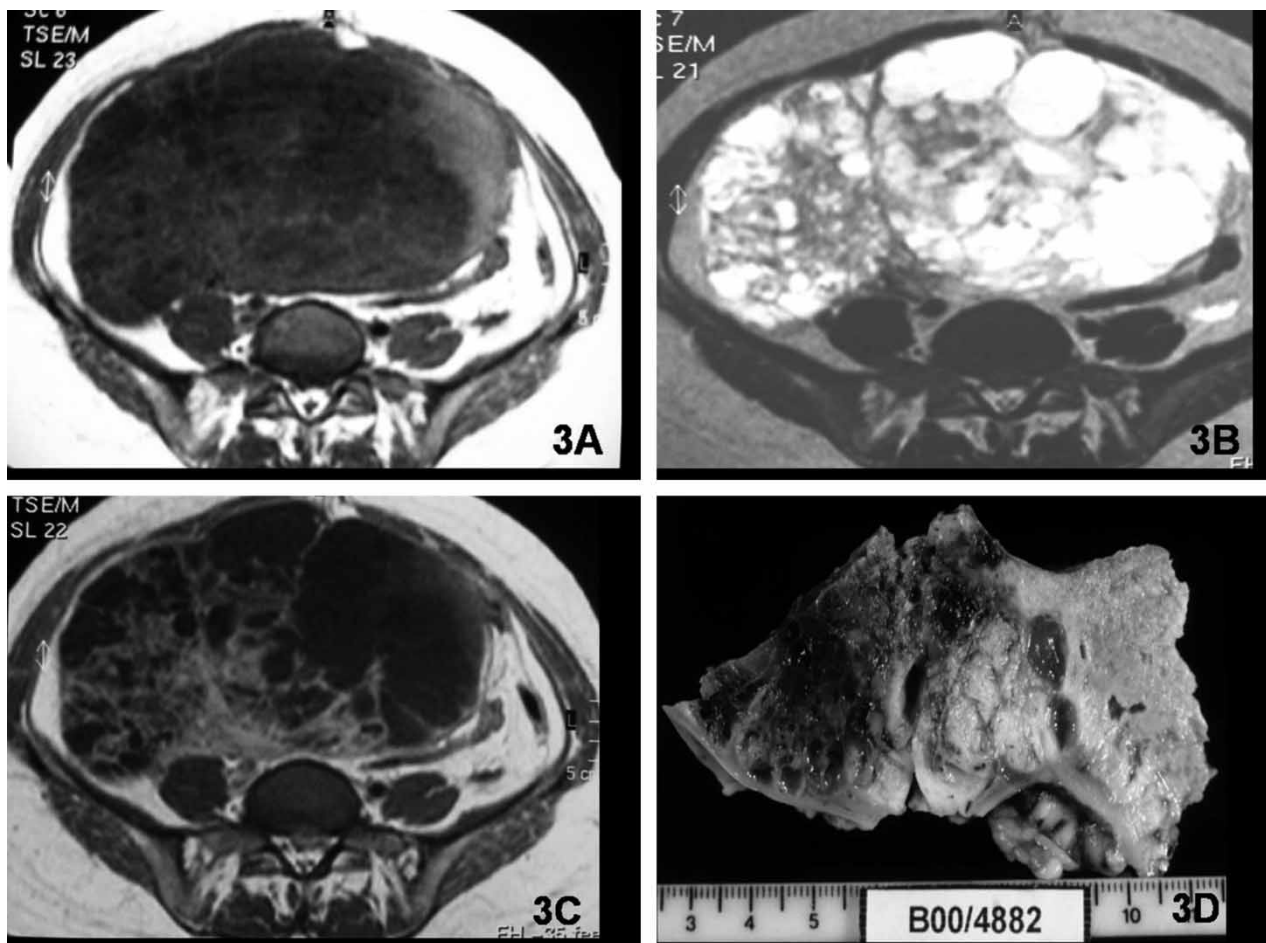


Fig. 3. Germ-cell tumor of the right ovary in a 40-year-old woman. Large mixed mass with solid and cystic components on T1-weighted (A) and T2-weighted (B) images. C. Contrast-enhanced T1-weighted image shows prominent enhancement of the solid component. D. Section of part of the resected specimen with solid hemorrhagic and necrotic tumor.

non-malignant). All MRI and histological results were compared, except those relating to tumors classified as of uncertain malignant potential.

Statistical analysis

The kappa statistic was used to evaluate the degree of correlation between the MRI and histological results.

Results

MR results

Based on the analysis of the imaging characteristics of the 199 lesions, 97 adnexal lesions were characterized as malignant and 102 as non-malignant. Of these, seven lesions were excluded from the study because they were histologically classified as uncertain malignant potential tumors. The final pathological report of the remaining 192 lesions found that 83 malignant (true positive) and 100

non-malignant (true negative) lesions were correctly diagnosed. The MRI evaluation of adnexal lesions failed to detect malignancy in nine cases: two were false-negative and seven were false-positive results. On MRI evaluation of the 192 adnexal lesions, 120 lesions were found to be cystic, 33 were mixed, and 39 were solid.

Cystic lesions

Of the 120 cystic lesions, 32 were classified as malignant and 88 as non-malignant. The vast majority of non-malignant cystic lesions had variable signal intensity on T1- and T2-weighted images without enhanced papillary projections or thick septa. Cystic lesions with very-low-signal-intensity solid components on T2-weighted images (similar to muscle) (Fig. 5) were also included in this group. This pattern was present in six cases: five cystadenofibromas and one borderline cystadenofibroma tumor.

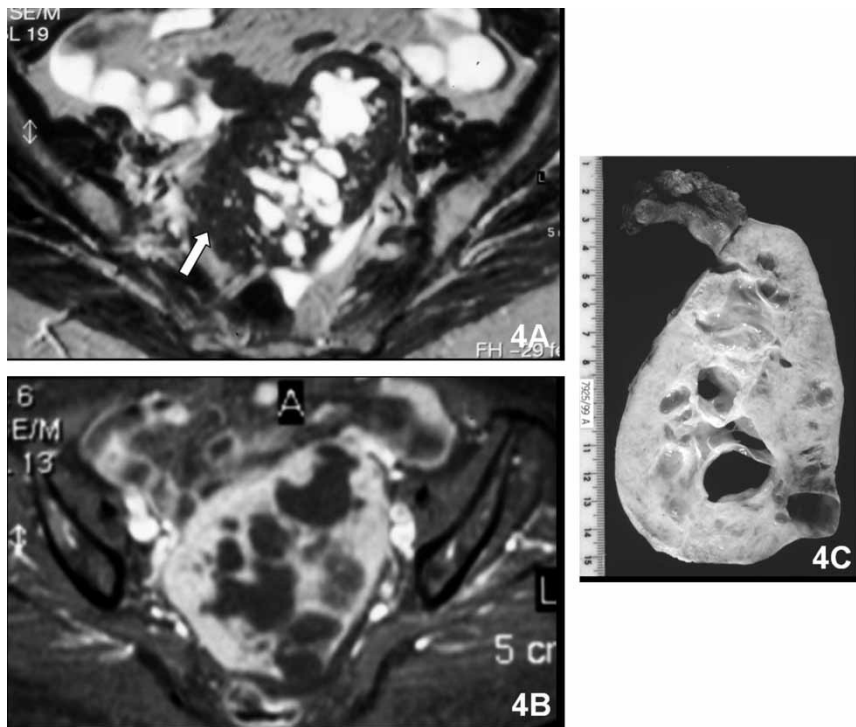


Fig. 4. Left adnexal fibroma in a 70-year-old woman. A. Mixed left adnexal lesion demonstrates heterogeneous signal intensity with high-signal-intensity cystic portions and low-signal-intensity solid portions (white arrow) on axial T2-weighted MR image. B. The mass shows enhancement of the solid portions on contrast-enhanced fat-suppressed axial T1-weighted image. C. Gross specimen section of left oophorectomy.

On MRI, 99% of all non-malignant cystic lesions were histologically confirmed as benign, except the borderline cystadenofibroma (1%). The major-

ity of the non-malignant cystic lesions were simple hemorrhagic or high-protein-content cysts, endometriomas, and teratomas.

All 32 cases of cystic lesions defined as malignant by MRI (enhanced papillary projections or enhanced thick septa) were confirmed by histology as malignant, except for three (9%) lesions (one benign struma ovarii, one cystadenoma associated with benign struma ovarii, and one serous cystadenoma).

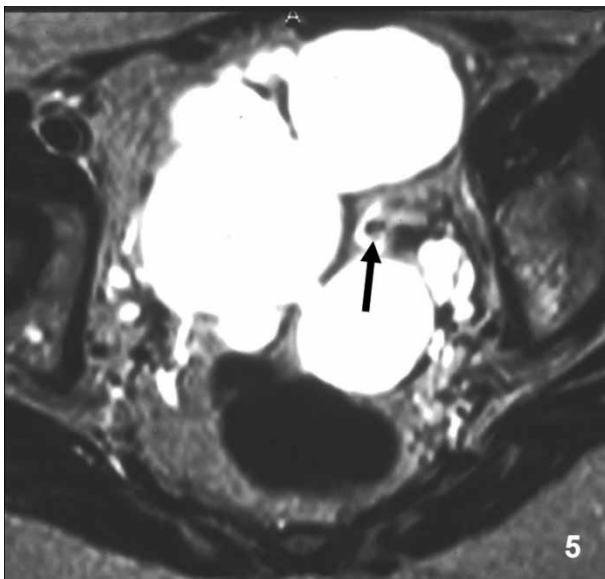


Fig. 5. Bilateral cystadenofibroma of the ovary in a 77-year-old woman. Axial T2-weighted image shows a bilateral cystic lesion with thick and thin septations, a low-signal-intensity solid component, and a low-signal-intensity papillary projection (arrow).

Solid lesions

Of the 39 adnexal masses demonstrating solid pattern, 31 were malignant and eight were non-malignant in the final histological diagnoses. All five solid lesions considered as non-malignant on MRI had a non-malignant histological diagnosis. These lesions were three fibromas, one fibrothecoma, and one thecoma. In none of the malignant lesions was this MR feature (solid lesions with low signal intensity on T2-weighted images) found. Four lesions (10%) with solid pattern and malignant features on MRI (two fibromas and one bilateral cystadenofibroma) were non-malignant on histologic examination. The remaining solid lesions were correctly diagnosed on MRI as malignant.

Mixed lesions

All 21 lesions with mixed pattern and criteria of malignancy on MRI were correctly diagnosed as malignant. Twelve lesions with mixed pattern and low-signal-intensity solid components on T2-weighted images were classified as non-malignant. Eleven (92%) were correctly diagnosed on MRI as non-malignant (seven cystadenofibromas and four fibromas), and one (8%) was a borderline Brenner tumor.

Ancillary criteria

Ascites, peritoneal nodules, and pelvic adenopathies were present in 65, 17, and eight patients, respectively. All patients with pelvic adenopathies and peritoneal metastasis had malignant adnexal masses. Ascites was presented in 44 patients with malignant adnexal masses and in 21 with benign adnexal masses.

Lesions with the highest accuracy rate for the diagnosis of malignancy achieved by MRI were mixed lesions; these diagnoses concurred 100% with the histological diagnoses. There were three cystic (9%) and four solid (13%) lesions that were histologically non-malignant, but had malignant features on MRI.

Histological results

Using histological evaluation, 85 masses were classified as malignant tumors (37 ovarian tumors, 16 epithelial borderline ovarian tumors [one cystadenofibroma, 10 epithelial serous tumors, three epithelial mucinous tumors, one mixed tumor, and one Brenner tumor], 26 ovarian metastases, five primary fallopian tube carcinomas, and one carcinoma originating from the mesosalpinx). One hundred seven were classified as benign tumors (94 ovarian benign tumors, seven functional cysts, one peritoneal inclusion cyst, one cystosteatonecrosis of an epiploic appendix, three tubo-ovarian abscesses, and one hematosalpinx). Seven were classified as uncertain malignant potential tumors (one sclerosing stromal tumor, one Sertoli-Leydig cell tumor, one granulosa cell tumor, one stromal endometrial tumor in an endometrioma, one steroid cell tumor, one Leydig cell tumor, and one ovarian Wolffian tumor).

Statistical results

A kappa coefficient of 0.906 revealed an almost perfect agreement between MRI and the histological results. The MRI sensitivity and specificity for malignancy were 98% and 93%, respectively. MRI

reached an accuracy of 95%, with a positive predictive value of 0.92 and a negative predictive value of 0.98 for malignant adnexal lesions.

Discussion

Preoperative characterization of adnexal lesions has important implications. Firstly, it is of considerable value for the gynecologist or general surgeon to know before surgery whether the lesion is benign or malignant, as this enables them to perform the most appropriate surgical procedure. Secondly, clinical and laboratory data are usually not specific enough for the characterization of the malignant nature of these lesions, especially in premenopausal women (9).

US and MRI are the most useful modalities for the assessment of adnexal lesions (4). US should be the primary imaging approach for the assessment and characterization of adnexal lesions (2). MRI, specifically contrast-enhanced MRI, provides additional information, mainly in the characterization of indeterminate lesions identified by US, as contrast-enhanced MRI is significantly more accurate than US in adnexal lesion characterization, as shown by previous studies (4, 11, 21). Endovenous contrast administration is fundamental to the differentiation between solid and cystic lesions. For this reason, it is essential to apply the correct MRI protocol when evaluating adnexal lesions.

In this study, we found that MRI is a reliable method for differentiating between malignant and non-malignant adnexal lesions with high accuracy (95%), and our data concur with previously published data that report accuracies ranging from 83 to 94% (3, 4, 7–13). The pelvic MRI scans of 161 patients with 199 adnexal lesions who underwent surgery at our hospital were reviewed, and the MRI and histological results were compared. Of these lesions, seven were excluded (seven adnexal patients) because the final histological diagnosis of these lesions was tumor with uncertain prognosis. These tumors could not be unambiguously classified as malignant or non-malignant, as the prognosis was unpredictable. It is important to point out that all these lesions had malignant features on MRI. One hundred ninety-two adnexal lesions were hence included, and well-established MRI criteria for diagnosing malignancy were applied. Some modifications were introduced, such as masses with very low signal intensity (similar to muscle striate) on T2-weighted images, which were excluded from the malignant group. Although the size of the lesion (>4 cm) is considered a criterion of malignancy by

some authors (8, 4, 14), it was not included as such in our study, as we agree with others that lesion size (>4 cm) when combined with other imaging findings does not further contribute to the prediction of malignancy (9). The bilaterality of adnexal lesions is another accepted criterion of malignancy. This criterion was also rejected, because bilaterality can occur in both malignant and benign lesions, and is mainly related to specific histological types (5, 10). Despite bilateral ovarian involvement usually reflecting the presence of metastases, recent studies have shown that bilaterality is not a reliable differentiating feature of primary versus secondary ovarian neoplasm (22).

All lesions studied in this report with non-malignant features on MRI were correctly diagnosed as non-malignant, except for two borderline tumors (one cystic lesion with low-signal-intensity papillary projections on T2-weighted images and one mixed lesion with low-signal-intensity solid components on T2-weighted images). The majority of non-malignant lesions were cystic. Our study shows that non-malignant simple cystic lesions were almost all correctly diagnosed based on previously established criteria (3, 4, 15). The identification of blood and high protein content based on signal intensity characteristics on T1- and T2-weighted images contributed to the diagnosis of hemorrhagic/high-protein-content cysts, as proven in the literature (15).

All endometriomas in this study had high signal intensity on T1-weighted images with loss of signal on T2-weighted images ("shading"), as already shown by previous studies (3, 4, 15). In this series, as in the study by TOGASHI et al. (23), no case of malignancy was misdiagnosed as an endometrial cyst. The diagnosis of mature teratoma was correctly made when fatty tissue was identified (3, 4, 15, 16).

The extra-ovarian non-malignant lesions were correctly diagnosed because of their appearance—oblong fluid-filled tubular structures, as in hemato-salpinx and tubo-ovarian abscesses (3, 4). In these cases, additional clinical history and examination were fundamental in establishing the diagnosis.

The remaining non-malignant lesions were cystic lesions with low-signal-intensity papillary projections, homogeneous solid lesions with very low signal intensity on T2-weighted images, and mixed lesions with very-low-signal intensity solid components on T2-weighted images (like striate muscle). Our data proved that homogeneous solid lesions with very low signal intensity on T2-weighted images were all non-malignant. The majority of mixed and cystic lesions with very-low-signal-intensity components on T2-weighted images (like striate muscle) were non-malignant. We failed only in two borderline tumors: one borderline cystadenofibroma and one borderline Brenner tumor (Table 1). These tumors may have extensive areas of dense fibrous tissue, and have features on MRI similar to other benign tumors with fibrous components (16). Previous studies support the thesis that fibromas, cystadenofibromas, and fibrothecomas are defined by their low-signal-intensity content on T2-weighted images. However, no previous studies have proven that all lesions with solid components with very low signal intensity on T2-weighted images (such as striate muscle) could be regarded as non-malignant (16–19).

The three cystic lesions that we failed to diagnose as non-malignant on MR were one benign struma ovarii, one cystadenoma associated with benign struma ovarii, and a serous cystadenoma. The two struma ovarii were cystic lesions with septal thickness ≥ 3 mm and contrast-enhanced papillary projections without fat component tissue signal on MR. Our data are in line with previous studies that have reported that some benign ovarian tumors with enhancing solid portions such as struma ovarii could mimic malignant lesions (15). The other cystic lesion was a serous cystadenoma with a contrast-enhanced papillary projection.

The four solid lesions incorrectly diagnosed as malignant on MRI were two fibromas and one bilateral cystadenofibroma. These lesions had little fibrous tissue, which was not enough to produce as low a signal as muscle on T2-weighted imaging. In addition to the non-malignant findings referred to above, we can conclude that when an adnexal lesion

Table 1. Adnexal lesions with low-signal-intensity solid components on T2-weighted images.

Type	Fibroma	Fibrothecoma	Cystadenofibroma	Borderline
Solid	5	1	–	–
Cystic	–	–	5	1
Mixed	4	–	7	1

has a very-low-signal-intensity solid component on T2-weighted images, it should have fibrous tissue in its composition. However, not all lesions with fibrous content have low-signal-intensity solid components on T2-weighted imaging. This feature may result from the amount of fibrous tissue in the adnexal lesion.

The ancillary inclusion criteria may be important, as they increase the diagnostic confidence of malignancy (15). However, caution should be used regarding the presence of ascites. Ascites is not an unusual finding associated with benign lesions, mainly fibromas. In our study, contrary to the findings of SOHAIB et al. (10), 32% of patients with ascites had benign lesions. All patients with pelvic adenopathies and peritoneal metastasis had malignant adnexal tumors.

Our conclusions are limited by the following factors: the patient population was previously selected and biased by the US examination; more benign than malignant lesions were found; the study was retrospective; and the MR machine used was of only intermediate strength. However, our results are in line with previous studies performed with 1.5-Tesla unit equipment, and 1.0-Tesla machines can obtain similar results. Finally, because the number of cases with very-low-signal-intensity solid components on T2-weighted images was small, it cannot be regarded as a statistically acceptable criterion of non-malignancy. Nevertheless, it is our belief that our findings are of significant importance and should be divulged to clinicians, since they indicate that the lesion has a high probability of being non-malignant, with a great likelihood of being a cystadenofibroma, fibroma, or thecoma. We also believe that it would be important to follow up our work with a further study to confirm our findings through statistically acceptable data.

In conclusion, MRI has an excellent accuracy (95%) with a high (0.92) positive predictive value for the diagnosis of malignant adnexal lesions. Ascites is an ancillary inclusion criterion of malignancy, but is present in some (32%) benign adnexal lesions as well.

References

1. Moon HM. Ovarian tumors: general considerations and mode of spread. In: Kim SH, McClennan BL, Outwater EK, editors. *Radiology illustrated: gynecologic imaging*. 1st ed. New York: Cambridge University Press; 2005. p. 453–99.
2. Kinkel K, Hricak H, Lu Y, Tsuda K, Filly RA. US characterization of ovarian masses: a meta-analysis. *Radiology* 2000;217:803–11.
3. Jain KA, Friedman DL, Pettinger TW, Alagappan R, Jeffrey RB Jr, Sommer FG. Adnexal masses: comparison of specificity of endovaginal US and pelvic MR imaging. *Radiology* 1993;186:697–704.
4. Yamashita Y, Torashima M, Hatanaka Y, Harada M, Higashida Y, Takahashi M, et al. Adnexal masses: accuracy of characterization with transvaginal US and precontrast and postcontrast MR imaging. *Radiology* 1995;194:557–65.
5. Bazot M, Nassar-Slaba J, Thomassin-Naggara I, Cortez A, Uzan S, Darai E. MR imaging compared with intraoperative frozen-section examination for the diagnosis of adnexal tumors; correlation with final histology. *Eur Radiol* 2006;16:2687–99.
6. Orden MR, Jurvelin JS, Kirkinen PP. Kinetics of US contrast agent in benign and malignant adnexal tumors. *Radiology* 2003;226:405–10.
7. Rieber A, Nussle K, Stohr I, Grab D, Frenchel S, Kreienberg R, et al. Preoperative diagnosis of ovarian tumors with MR imaging: comparison with transvaginal sonography, positron emission tomography, and histologic findings. *Am J Roentgenol* 2001;177:123–9.
8. Stevens SK, Hricak H, Stern JL. Ovarian lesions: detection and characterization with gadolinium-enhanced MR imaging at 1.5 T. *Radiology* 1991;181:481–8.
9. Hricak H, Chen M, Coakley FV, Kinkel K, Yu K, Sica G, et al. Complex adnexal masses: detection and characterization with MR imaging – multivariate analysis. *Radiology* 2000;214:39–46.
10. Sohaib SA, Sahdev A, Van Trappen P, Jacobs IJ, Reznick RH. Characterization of adnexal mass lesions on MR imaging. *Am J Roentgenol* 2003;180:1297–304.
11. Medl M, Kulenkampff KJ, Stiskal M, Peters-Engl C, Leodolter S, Czembirek H. Magnetic resonance imaging in the preoperative evaluation of suspected ovarian masses. *Anticancer Res* 1995;15:1123–5.
12. Occhipinti KA. Computed tomography and magnetic resonance imaging of the ovary. In: *Gynecologic imaging*. Anderson JC, ed. London: Churchill Livingstone; 1999. p. 345–59.
13. Saini A, Dina R, McIndoe GA, Soutter WP, Gishen P, deSouza NM. Characterization of adnexal masses with MRI. *Am J Roentgenol* 2005;184:1004–9.
14. Forstner R, Hricak H, White S. CT and MRI of ovarian cancer. *Abdom Imaging* 1995;20:2–8.
15. Jeong YY, Outwater EK, Kang HK. Imaging evaluation of ovarian masses. *Radiographics* 2000;20:1445–70.
16. Jung SE, Lee JM, Rha SE, Byun JY, Jung JI, Hahn ST. CT and MR imaging of ovarian tumors with emphasis on differential diagnosis. *Radiographics* 2002;22:1305–25.
17. Kim KA, Park CM, Lee JH, Kim HK, Cho SM, Kim B, et al. Benign ovarian tumors with solid and cystic components that mimic malignancy. *Am J Roentgenol* 2004;182:1259–65.
18. Schwartz RK, Levine D, Hatabu H, Edelman RR. Ovarian fibroma: findings by contrast-enhanced MRI. *Abdom Imaging* 1997;22:535–7.

19. Troiano RN, Lazzarini KM, Scoutt LM, Lange RC, Flynn SD, McCarthy S. Fibroma and fibrothecoma of the ovary: MR imaging findings. *Radiology* 1997;204:795–8.
20. WHO histological classification of tumours of the ovary. In Tavassoli FA, Devilee P, editors. World Health Organization classification of tumors. Pathology and genetics. Tumors of the breast and female genital organs. 1st ed. Lyon: IARC Press; 2003. p. 114–5.
21. Popovich MJ, Hricak H. The role of magnetic resonance imaging in the evaluation of gynecologic disease. In: Callen PW, editor. *Ultrasonography in obstetrics and gynecology*. 3rd ed. Philadelphia: Saunders; 1994. p. 660–88.
22. Brown DL, Zou KH, Tempany CM, Frates M, Silverman S, McNeil B, et al. Primary versus secondary ovarian malignancy: imaging findings of adnexal masses in the Radiology Diagnostic Oncology Group Study. *Radiology* 2001;219:213–8.
23. Togashi K, Nishimura K, Kimura I, Tsuda Y, Yamashita K, Shibata T, et al. Endometrial cysts: diagnosis with MR imaging. *Radiology* 1991;180:73–8.



**How do you get the most
out of contrast media?**

Use a little less.

Details are crucial. A sharp and clear detailed image is a must in order to give a reliable diagnosis and an optimal examination. Initios Medical's unique contrast media enables a lower dose and gives you a clearer, high quality image.

At Initios Medical you will find the experience and expertise that you need to do an excellent job and make secure diagnoses. On our website you can keep yourself updated on the latest findings about CIN and NSF, benefit from the experiences of peers from around the world and read more about our wide range of innovative and safe products.

Please visit www.initios.com

Initios Medical AB + 46 (0)31 760 18 80

Initios
clearly there's a difference



PROTOCOL