

Contents lists available at [ScienceDirect](https://www.sciencedirect.com)

Journal of ISAKOS

journal homepage: www.elsevier.com/locate/jisakos

Original Research

Influence of the rotator cuff tear pattern in shoulder stability after arthroscopic superior capsule reconstruction: a computational analysis

Madalena Antunes^a, Carlos Quental^a, João Folgado^a, Ana Catarina Ângelo^{b,c},
Clara de Campos Azevedo^{b,c,*}

^a IDMEC, Instituto Superior Técnico, Universidade de Lisboa, Av. Rovisco Pais 1, 1049-001, Lisbon, Portugal

^b Hospital CUF Tejo, Av. 24 de Julho 171 A, 1350-352, Lisbon, Portugal

^c Hospital dos SAMS de Lisboa, Lisbon, Portugal

ARTICLE INFO

Keywords:

Rotator cuff tear
Arthroscopic superior capsule reconstruction
Shoulder stability
Musculoskeletal model
Fascia lata autograft

ABSTRACT

Objectives: To assess the ability of the arthroscopic superior capsule reconstruction (SCR) in restoring glenohumeral stability in the presence of different preoperative patterns of irreparable rotator cuff tears (RCTs).

Methods: A computational musculoskeletal (MSK) model of the upper limb was used to simulate isolated SCR and to estimate the stability of the shoulder. Four patterns of preoperative irreparable RCTs were modeled: Supraspinatus (SSP); SSP + Subscapularis (SSC); SSP + Infraspinatus (ISP); and SSP + SSC + ISP. The muscles involved in the irreparable RCT were removed from the MSK model to simulate an irreparable full-thickness tear. In the MSK model, the muscle and joint forces were estimated for a set of upper limb positions, from four types of motions (abduction in the frontal plane, forward flexion in the sagittal plane, reaching behind the back, and combing the hair) collected in a biomechanics laboratory, through inverse dynamic analysis. The stability of the shoulder was estimated based on the tangential and compressive components of the glenohumeral joint reaction force. The comparison of pre- and post-operative conditions, for the four patterns of irreparable RCTs, with the healthy condition, was performed using ANOVA and Tukey's tests (statistical level of $p < 0.05$).

Results: In the setting of an isolated irreparable SSP tear, SCR statistically significantly improved stability compared with the preoperative condition ($p < 0.001$). For the irreparable SSP + SSC pattern, a statistically significant loss in stability was observed ($p < 0.001$) when SCR was applied. For the irreparable SSP + ISP and SSP + SSC + ISP patterns, the postoperative condition increased shoulder stability, compared to the preoperative condition; however, the improvement was not statistically significantly different.

Conclusion: Isolated SCR for irreparable RCTs extending beyond the SSP does not statistically significantly improve the stability of the glenohumeral joint.

Level of evidence: Level IV.

What are the new findings?

- Arthroscopic superior capsule reconstruction for isolated irreparable supraspinatus tendon tears improves shoulder stability for all shoulder positions of fixation evaluated.
- For tears that extended to the subscapularis and/or infraspinatus tendons, the graft cannot restore the anterior and/or posterior stability lost with the rotator cuff tear.
- For anterosuperior irreparable rotator cuff tears, a significant loss in stability was observed compared to the preoperative condition.

* Corresponding author. Hospital CUF Tejo, Av. 24 de Julho 171 A, 1350-352, Lisbon, Portugal.

E-mail addresses: madalena.antunes@tecnico.ulisboa.pt (M. Antunes), carlos.quental@tecnico.ulisboa.pt (C. Quental), jfolgado@tecnico.ulisboa.pt (J. Folgado), ana_angelo@msn.com (A.C. Ângelo), claracamposazevedo@gmail.com (C. de Campos Azevedo).

<https://doi.org/10.1016/j.jisako.2024.01.014>

Received 14 October 2023; Received in revised form 10 January 2024; Accepted 29 January 2024

Available online xxx

2059-7754/© 2024 The Author(s). Published by Elsevier Inc. on behalf of International Society of Arthroscopy, Knee Surgery and Orthopedic Sports Medicine. This is an open access article under the CC BY-NC-ND license (<http://creativecommons.org/licenses/by-nc-nd/4.0/>).

Please cite this article as: Antunes M et al., Influence of the rotator cuff tear pattern in shoulder stability after arthroscopic superior capsule reconstruction: a computational analysis, Journal of ISAKOS, <https://doi.org/10.1016/j.jisako.2024.01.014>

INTRODUCTION

Arthroscopic superior capsule reconstruction (ASCR) was introduced by Mihata et al. for the treatment of irreparable rotator cuff tears (RCTs) [1]. An irreparable RCT leads to a destabilization of the glenohumeral (GH) joint, as the muscles of the rotator cuff are its main dynamic stabilizers [2–4]. In ASCR, a graft is positioned and fixed along the physiological vector of the supraspinatus (SSP) tendon (Fig. 1), bridging the superior glenoid rim and the SSP footprint [1,5,6]. The goal of the superior capsular graft is to act as a fulcrum to the deltoid pulling vector and to restore the physiologic kinematics [7,8].

The four most common patterns of irreparable RCTs, correspond to the full-thickness tear of the following tendon(s): SSP; SSP + Subscapularis (SSC); SSP + Infraspinatus (ISP); and SSP + SSC + ISP [5, 7–10]. These preoperative tear patterns influence the mechanisms of stabilization of the GH joint. Previous cadaveric and computational studies suggest that tear patterns that extend beyond the SSP are associated with instability and altered kinematics of the GH joint, highlighting the importance of the stabilizing action of the transverse force couple (SSC and ISP) [11–13]. If the SSC or ISP tendons are intraoperatively identified as repairable, direct repair may be applied concomitantly to ASCR by suturing the tendon to its healthy footprint [5,6,14]. Conversely, if the fully torn SSC and/or ISP tendon are classified as irreparable, alternative concomitant procedures may be considered with the purpose of re-establishing the horizontal force couple, including [5,6,14]: augmented repair using an autograft or allograft [15,16]; pectoralis major or latissimus dorsi tendon transfer to the SSC footprint [17,18]; and latissimus dorsi or lower trapezius transfer to the ISP footprint [19–22].

The effect of ASCR on the stability of the GH joint in the setting of an isolated irreparable full-thickness tear of the SSP tendon has been studied biomechanically through two *in vitro* and *in silico* models, with both studies showing that the isolated fixation of the superior capsular graft is able to restore GH joint stability [1,23]. Biomechanical evidence on whether ASCR alone is able to compensate the loss of the transverse force couple in the setting of a massive irreparable RCT is still lacking. Using cadaveric shoulders, Lacheta et al. found that a dermal allograft partially restored superior stability in the presence of superior (SSP) and posterolateral (SSP + ISP) tears [24]; however, their study considered only static muscle loading in standard shoulder planes of motion (abduction, flexion and scaption). Further research is necessary to evaluate how the biomechanics of the shoulder and the stabilization mechanisms are affected by an irreparable RCT that extends to the anterior and/or posterior cuff, and if ASCR alone is able to restore the stability and physiological kinematics of the shoulder for these RCT patterns. The purpose of this study was to assess the influence of the preoperative pattern of RCTs in the stability of the GH joint after ASCR. Standard shoulder motions (abduction and flexion) and two activities of the daily life were studied using a three-dimensional musculoskeletal (MSK) model of the upper limb. The hypothesis was that ASCR alone would not be able to restore

the GH joint stability in the setting of an irreparable RCT extending beyond the SSP tendon.

METHODS

Computational modeling

A three-dimensional MSK model of the upper limb composed of 7 rigid bodies and 22 muscles of the upper limb (74 muscle bundles), was modified to account for the fixation of the superior capsular graft in the superior capsule reconstruction (SCR) [23]. The origin and insertion sites of the graft, in the glenoid rim and the SSP footprint, respectively, were defined with the guidance of two experienced shoulder orthopedic surgeons (C.d.C.A. and A.C.A.). The graft was assumed to be perfectly bonded to the bone at the SSP footprint. The graft type used was of fascia lata (FL) material. The material properties of the FL graft were defined based on experimental data collected from fresh cadaveric FL grafts [25]. Muscle and joint reaction forces were estimated through inverse dynamic analyses considering kinematic data, collected from the database of the Laboratory of Biomechanics of Lisbon [26,27]. The population dataset consisted in 18 healthy subjects (7 males, 11 females), with a mean age of 24.5 years (range, 18–55 years). The kinematic data included four types of activities: abduction in the frontal plane, forward flexion in the sagittal plane, reaching behind the back, and combing the hair. The estimation of muscles forces, for each upper limb position of the kinematic data, was based on the minimization of muscle energy consumption, while also ensuring the fulfillment of the equations of motion and the stability of the anatomical joints [26]. A set of 45 shoulder positions of fixation of the graft (combination between abduction relative to the trunk, forward flexion, and axial rotation) were considered for analysis. These modeled shoulder positions of fixation of the graft were based in the published results of a previous computational study, considering the fixation positions in which the graft would not be at risk of failure in the setting of an ASCR [23]. As the present study aimed to evaluate how the fixation of the superior graft alone influenced GH joint stability, no other concomitant procedures (e.g., ISP or SSC repair; or side-to-side sutures between the graft and ISP or SSC tendons) were modeled.

Patterns of irreparable RCTs

The patterns of irreparable RCTs were modeled assuming the 4 most common types of shoulder preoperative conditions observed in patients who underwent ASCR [5,28,29]. Irreparable full-thickness tears of the following tendons were assumed: SSP; SSP + SSC; SSP + ISP; and SSP + SSC + ISP. For the sake of brevity, the term “irreparable” is henceforth omitted when referring to the modelled RCTs. For each of these four patterns of RCTs, the corresponding muscle of the torn tendon was removed from the MSK model (Fig. 2). This methodology was followed previously in cadaveric studies, where the muscles (of the torn tendons) were unloaded or resected [1,30,31]; and in a computational study by Steenbrink et al., where the force produced by these muscles was cancelled [13].

Shoulder stability evaluation

Shoulder stability was assessed based on the ratio between the tangential and compressive components of the GH joint reaction force, augmented by a weighting term related with how much additional muscle activity was necessary to prevent dislocation of the GH joint, mimicking the central nervous system [23]—the larger this augmented ratio, the lower the shoulder stability. Note that a high ratio, indicating reduced shoulder stability, does not necessarily imply a dislocation of the GH joint. Instead, it indicates a higher susceptibility of the joint to dislocation compared to a condition with greater shoulder stability. When removing the rotator cuff muscles from the MSK model (e.g., SSP, SSC and ISP), the biomechanics of the shoulder is altered, as these are the main dynamic

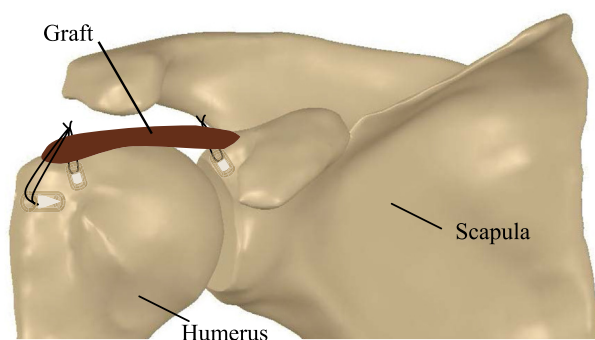


Fig. 1. Schematic representation of a superior capsule reconstruction. The superior capsular graft is fixed proximally to the superior glenoid rim and distally to the supraspinatus tendon footprint on the greater tuberosity.

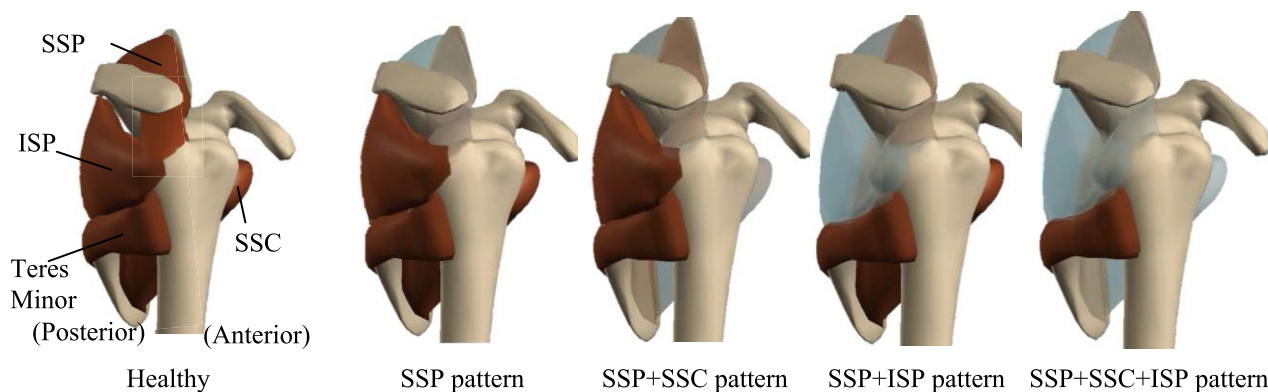


Fig. 2. Rotator cuff muscles and tendons for the (a) intact condition and rotator cuff tear conditions simulated, including an irreparable full-thickness tear of the supraspinatus (SSP); supraspinatus and subscapularis (SSC); supraspinatus and infraspinatus (ISP); and supraspinatus, subscapularis, and infraspinatus tendons.

stabilizers of the GH joint. For some upper limb positions (from the kinematic data), the MSK model may fail to find a physiological solution to the muscle force sharing problem, as previously described by Steenbrink et al. [13]. In this work, these positions, hereafter referred to as “unfeasible upper limb positions”, represent a scenario in which the stability of the GH joint or the fulfillment of the equations of motion were not ensured by the remaining muscles (in the MSK model), as there is a physiological limit to the additional muscular activity that can be recruited [27]. To allow a consistent computation of shoulder stability among the four patterns of RCTs, the stability of the shoulder for these positions was defined as the worst stability condition obtained for the feasible upper limb positions. These unfeasible upper limb positions were also saved, for each studied condition, to evaluate the effect of graft fixation on shoulder stability, by comparing their frequency between the pre- and post-operative conditions; and the effect of the pattern of RCT on shoulder stability, by comparing their frequency between the four RCT patterns considered.

Statistical analysis

Shoulder stability was compared between pre- and post-operative conditions for the four patterns of RCTs and the corresponding 45 shoulder positions of fixation studied. This comparison was based on one-way analysis of variance (ANOVA) and post-hoc Tukey's multiple comparison tests. The statistical analysis was conducted in MATLAB 2018a, where the *anova1* and *multi-compare* functions were used for ANOVA and Tukey's test, respectively. The significance level was set to $p = 0.05$.

RESULTS

Biomechanical performance of SCR

Compared to the intact condition, shoulder stability decreased with the increased extent of the RCT pattern, i.e., the SSP + SSC + ISP pattern was further away from the intact condition than the SSP pattern ($p < 0.05$) (Fig. 3). For the SSP pattern, our results suggest a statistically significant improvement, in terms of shoulder stability, from the pre to the postoperative condition, regardless of the shoulder position of fixation evaluated (95% confidence intervals, $p < 0.001$). For the SSP + SSC pattern a statistically significant loss in stability was observed for shoulder positions of fixation with abduction angles of 10° and 15° ($p < 0.05$), compared with the respective preoperative condition. Overall, fixation positions with neutral or 5° of abduction presented no statistically significant difference before and after isolated SCR. For the SSP + ISP and SSP + SSC + ISP patterns, the postoperative condition was better than the preoperative condition; however, this improvement was not statistically significant. Shoulder stability for each individual motion activity was also assessed, but, for the sake of brevity, these results are

only presented in the Supplementary Material. For the SSP pattern, the postoperative condition recovered the intact shoulder condition ($p < 0.001$) for the motions of abduction in the frontal plane and reaching behind the back. For the SSP + SSC pattern, the postoperative condition presented a statistically significant improvement in shoulder stability ($p < 0.05$) for the motions of abduction in the frontal plane, forward flexion in the sagittal plane, and combing the hair. On the other hand, for the SSP + ISP and SSP + SSC + ISP patterns, there was only an improvement in shoulder stability for the motion of forward flexion in the sagittal plane.

Unfeasible upper limb positions

For the SSP pattern, the MSK model found a physiological solution for all 7,529 upper limb positions evaluated, both before and after isolated SCR (Table 1). For the SSP + SSC, SSP + ISP and SSP + SSC + ISP patterns of RCT, the amount of unfeasible upper limb positions accounted for 1%, 6%, and 10% of the studied upper limb positions, respectively, in the preoperative condition. After fixation of the graft, the number of unfeasible upper limb positions increased from 1% to 3.80% (range, 1.92%–5.68%) for the SSP + SSC pattern, but decreased from 6% to 1.80% (range, 1.43%–2.17%) and from 10% to 5.73% (range, 4.50%–6.96%) for the SSP + ISP and SSP + SSC + ISP patterns of RCTs, respectively.

DISCUSSION

The main finding of this study was that isolated ASCR was not able to statistically significantly improve the stability of the shoulder for preoperative patterns of RCTs that extended beyond the SSP tendon, confirming the hypothesis of this study. The isolated fixation of the superior capsular graft could not compensate the loss of the transverse force couple.

The shoulder is a complex structure, whose stability is ensured by the joint action of muscles and static structures. A destabilization of this balance may translate into changes of the muscular dynamic activation and, consequently, the stability mechanisms. The preoperative patterns of RCTs were associated with a shoulder stability loss, compared to the intact shoulder condition. To prevent the dislocation of the GH joint, higher muscle recruitment was needed by the remaining muscles in the MSK model. For an irreparable tear of the SSP tendon, previous studies by Oh et al., Parsons et al., and Steenbrink et al. found no difference in the stability of the shoulder between the torn and intact conditions [11–13]. However, the first two are cadaveric studies that did not consider the dynamic muscular activation by the remaining muscles of the upper arm that participate in the stabilization of the GH joint [11,12]; and the third study evaluated only the stability of the shoulder for a single upper limb

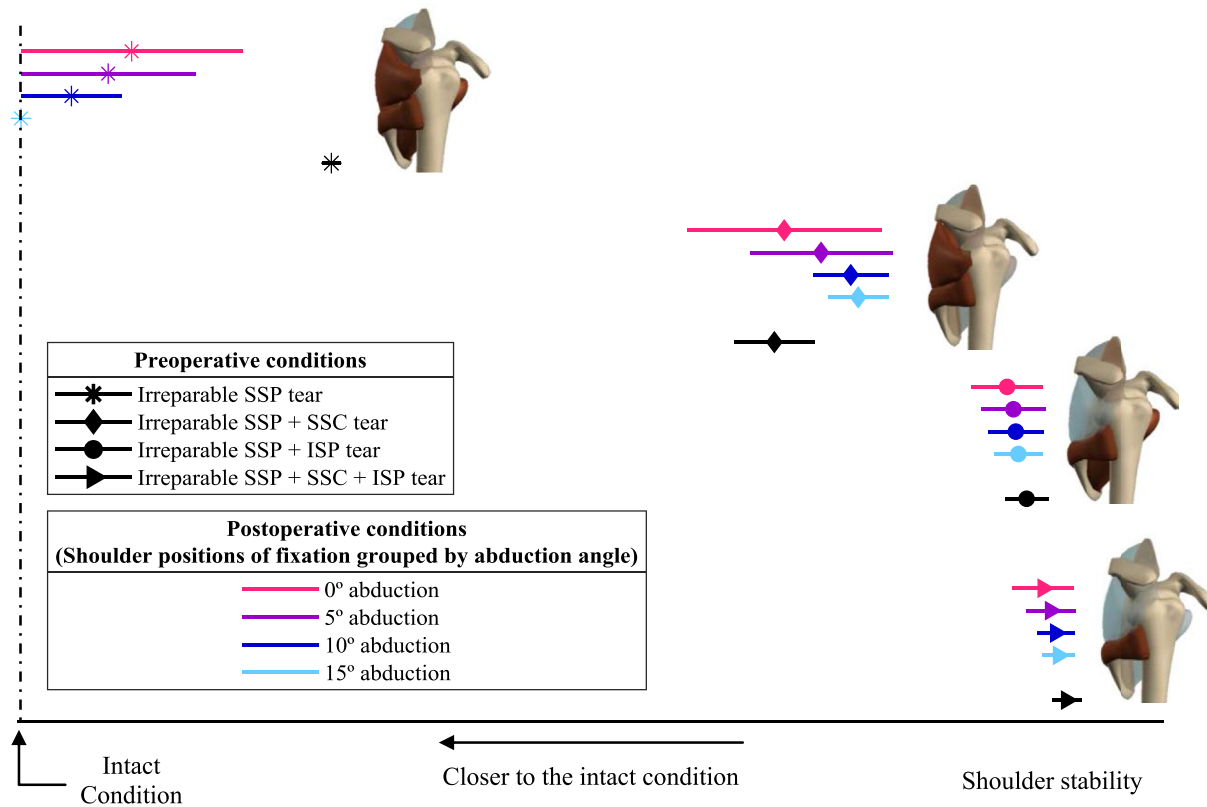


Fig. 3. Multiple comparison test for the estimated shoulder stability in the pre- and postoperative conditions for the four patterns of irreparable rotator cuff tears, including irreparable tears of the following tendons: supraspinatus (SSP); supraspinatus and subscapularis (SSC); supraspinatus and infraspinatus (ISP); and supraspinatus, subscapularis, and infraspinatus. In the postoperative condition, the shoulder positions of fixation are grouped by abduction angles (0°, 5°, 10°, and 15°), in which forward flexion varies between 0° and 70° and axial rotation varies between -10° and 10°. The markers represent the mean value of each group. The lines crossing the markers symbolize the respective comparison intervals. The difference between two means is statistically significant when the comparison intervals do not overlap.

position, against the 7,529 upper limb positions from four types of activities used in the current study [13]. For the preoperative patterns of RCTs that extended in the anterior direction and/or posterior direction, previous studies also found a loss in shoulder stability compared to the intact condition [12,13]. Note that the infraspinatus has been shown to aid stabilization during abduction of the arm, by restricting posterior and superior translations [32,33]; and the subscapularis has been shown to prevent excessive anterior translations [4]. In the current study, the MSK model failed to find a physiological solution for these preoperative patterns of RCTs for some upper limb positions (Table 1), hereafter referred to as “unfeasible upper limb positions.” No statistically significant difference was found in stability between the preoperative SSP + ISP and SSP + ISP + SSC patterns of RCTs, as obtained previously by Parsons et al. [12].

ASCR aims to restore the physiological kinematics of the shoulder and the stability mechanisms compromised by the irreparable RCT [1,7]. The superior capsular graft works like a hammock, helping to center the

humeral head with respect to the glenoid, and as a stabilizer, producing force and redirecting the force couple to the glenoid as it deforms [23]. For an isolated irreparable full-thickness tear of the SSP tendon, the MSK model found a physiological solution for all upper limb positions after isolated SCR. The muscular activity necessary to avoid dislocation of the joint statistically significantly reduced ($p < 0.001$), compared to the preoperative condition, as the superior component of the vertical force couple was re-established by the superior capsular graft. Moreover, for some of the shoulder positions of graft fixation studied, the postoperative shoulder condition restored the intact condition. These results are consistent with those of Mihata et al., who showed that ASCR restored superior stability for a full-thickness SSP [1].

For the SSP + SSC pattern, with the ISP still transmitting force (intact or after repair), shoulder stability statistically significantly decreased ($p < 0.05$) for some shoulder positions of graft fixation, compared with the preoperative condition (Fig. 3 and Table 1), mainly because the number of unfeasible upper limb positions increased. Unfeasible positions occurred

Table 1

Percentage of unfeasible upper limb positions for the pre- and post-operative conditions of the four patterns of irreparable rotator cuff tears, including irreparable tears of the following tendons: supraspinatus (SSP); supraspinatus and subscapularis (SSC); supraspinatus and infraspinatus (ISP); and supraspinatus, subscapularis, and infraspinatus.

Irreparable RCT	Preoperative condition, %	Postoperative condition, %	
		Mean	Std
SSP	0	0	0
SSP + SSC	1	3.80	1.88
SSP + ISP	6	1.80	0.37
SSP + SSC + ISP	10	5.73	1.23

when secondary joint forces and moments introduced by the graft deformation in ASCR could not be counteracted by the remaining muscles while also ensuring GH joint stability, which represented a less stable condition than the preoperative condition. The upper limb positions of the reaching behind the back motion contributed the most to this outcome. As the SSC was not repaired, the transverse force couple was disrupted, and the remaining muscles could not assist the internal rotation of the arm [2]. For the remaining motions evaluated (abduction in the frontal plane, forward flexion in the sagittal plane, and combing the hair) the postoperative condition presented a statistically significant improvement in shoulder stability ($p < 0.05$), compared to the preoperative condition. It has been suggested that the irreparability of the SSC line of action should be considered a contraindication for ASCR [28,34]. This is supported by the results of the current study. Nevertheless, further studies are necessary to evaluate the performance of concomitant procedures to restore the SSC line of action in ASCR, such as anterior graft reconstruction, pectoralis major transfer, and latissimus dorsi transfer [16–18].

When the rotator cuff tear extended to the ISP (SSP + ISP and SSP + SSC + ISP patterns), isolated SCR resulted in an improvement of shoulder stability; however, this improvement was not statistically significant. The fixation of the graft decreased the number of unfeasible upper limb positions, compared to the preoperative conditions of the respective patterns of RCTs. Even though the MSK model found a physiological solution at the cost of higher muscle recruitment, compared to the intact condition, note that in a physiological scenario, the loss of the ISP action, and the extra muscular activity necessary to compensate for this loss, might not be tolerated by the patient. The results of this study suggest that the fixation of the superior capsular graft is not able to statistically significantly compensate for the disruption in the transverse direction when the ISP is fully torn, which is in agreement with the cadaveric study by Lacheta et al. [24], where SCR alone with a dermal allograft was only able to partially restore superior stability in a simulated posterosuperior RCT (SSP + ISP). For the SSP + ISP pattern, further investigation is necessary to evaluate if the stability of the shoulder may be improved by concomitant procedures that re-establish the stabilizing action of the ISP, such as graft augmentation, latissimus dorsi transfer, and lower trapezius transfer [15,19,22]. For the complete loss of the transverse force couple, in the SSP + SSC + ISP pattern, concomitant procedures to restore the action of the ISP and SSC are not recommended, as they should only be performed in patients that have an intact ISP or SSC [14,35]. For patients presenting with a SSP + SSC + ISP pattern of RCT, other techniques should be considered, such as reverse total shoulder arthroplasty [36,37].

The current study provides relevant insight into the biomechanics of the shoulder after isolated ASCR for several preoperative patterns of RCTs. The MSK model used was qualitatively validated in previous studies for healthy and pathological (patients with reverse shoulder arthroplasty) populations by comparing muscle moment arms with the literature and muscle activations with collected EMG data [27,38]. Four types of activities were included: abduction in the frontal plane, forward flexion in the sagittal plane, reaching behind the back, and combing the hair. The kinematic data used were obtained from a dataset of healthy and young subjects, as also considered in previous studies addressing irreparable RCTs [13,23], allowing for a direct comparison of the estimated shoulder stability between the four patterns of RCTs. The translation and possible dislocation of the GH joint was modeled indirectly based on the ratio between the components of the GH joint reaction force, which are affected by dynamic muscular activation [23,39,40].

The methodology followed is not free of limitations. No direct validation of the MSK model was performed for isolated SCR. The muscular activation was computed through the minimization of muscle energy consumption [41,42], even though it might not be the primary aim of the central nervous system when recruiting muscle fibers in patients affected by an irreparable RCT. The spacer effect of the graft was not directly modeled. By modeling the GH joint as a spherical joint with clearance in the MSK model [43], future studies may also evaluate if the role of the superior capsular graft as a spacer, working against superior translations,

is able to assist the stabilization of the GH joint, when the transverse force couple is disrupted. No concomitant procedures that restore the line of action of the SSC or ISP were studied. Further studies should investigate the impact of concomitant procedures on the outcome of ASCR, and if this impact is able to restore the stabilizing action of the remaining rotator cuff torn tendons (SSC and ISP).

CONCLUSION

Shoulder stability was evaluated using a computational model of the upper limb, before and after isolated superior capsule reconstruction. For isolated irreparable supraspinatus tendon tears, shoulder stability statistically significantly improved for all shoulder positions of fixation evaluated. For tears that extended to the subscapularis and/or infraspinatus tendons, the isolated superior capsule reconstruction does not statistically significantly improve shoulder stability, and the graft cannot restore the anterior and/or posterior stability lost with the rotator cuff tear.

Funding

This work was supported by the Portuguese Foundation for Science and Technology (FCT), through IDMEC, under LAETA, project UIDB/50022/2020, and the PhD scholarship 2021.06844.BD.

Declaration of competing interest

The authors declare the following financial interests/personal relationships that may be considered as potential competing interests: Clara de Campos Azevedo reports a relationship with CONMED Corp that includes: consulting or advisory, speaking and lecture fees, and travel reimbursement. Ana Catarina Angelo reports a relationship with CONMED Corp that includes: consulting or advisory and travel reimbursement. Clara de Campos Azevedo reports a relationship with Zimmer Biomet that includes: consulting or advisory and speaking and lecture fees. Ana Catarina Angelo reports a relationship with Zimmer Biomet that includes: consulting or advisory and speaking and lecture fees. If there are other authors, they declare that they have no known competing financial interests or personal relationships that could have appeared to influence the work reported in this article.

Availability of data and material

Not applicable.

Code availability

Not applicable.

Ethics approval

Not applicable.

Consent to participate

Not applicable.

Consent for publication

Not applicable.

Appendix A. Supplementary data

Supplementary data to this article can be found online at <https://doi.org/10.1016/j.jisako.2024.01.014>.

References

- [1] Mihata T, McGarry MH, Pirolo JM, Kinoshita M, Lee TQ. Superior capsule reconstruction to restore superior stability in irreparable rotator cuff tears: a biomechanical cadaveric study. *Am J Sports Med* 2012;40(10):2248–55. <https://doi.org/10.1177/0363546512456195>.
- [2] Akhtar A, Richards J, Monga P. The biomechanics of the rotator cuff in health and disease – a narrative review. *J Clin Orthop Trauma* 2021;18:150–6. <https://doi.org/10.1016/j.jcot.2021.04.019>.
- [3] Burkhart SS. Reconciling the paradox of rotator cuff repair versus debridement: a unified biomechanical rationale for the treatment of rotator cuff tears. *Arthrosc J Arthrosc Relat Surg* 1994;10(1):4–19. [https://doi.org/10.1016/s0749-8063\(05\)80288-9](https://doi.org/10.1016/s0749-8063(05)80288-9).
- [4] Greenspoon JA, Petri M, Warth RJ, Millett PJ. Massive rotator cuff tears: pathomechanics, current treatment options, and clinical outcomes. *J Shoulder Elbow Surg* 2015;24(9):1493–505. <https://doi.org/10.1016/j.jse.2015.04.005>.
- [5] Altintas B, Scheidt M, Kremser V, Boykin R, Bhatia S, Sajadi KR, et al. Superior capsule reconstruction for irreparable massive rotator cuff tears: does it make sense? A systematic review of early clinical evidence. *Am J Sports Med* 2020;48(13):3365–75. <https://doi.org/10.1177/0363546520904378>.
- [6] Gao I, Sochacki KR, Freehill MT, Sherman SL, Abrams GD. Superior capsular reconstruction: a systematic review of surgical techniques and clinical outcomes. *Arthrosc J Arthrosc Relat Surg* 2021;37(2):720–46. <https://doi.org/10.1016/j.arthro.2020.09.016>.
- [7] Mihata T, Lee TQ, Watanabe C, Fukunishi K, Ohue M, Tsujimura T, et al. Clinical results of arthroscopic superior capsule reconstruction for irreparable rotator cuff tears. *Arthrosc J Arthrosc Relat Surg* 2013;29(3):459–70. <https://doi.org/10.1016/j.arthro.2012.10.022>.
- [8] Hirahara AM, Adams CR. Arthroscopic superior capsular reconstruction for treatment of massive irreparable rotator cuff tears. *Arthrosc Tech* 2015;4(6):e637–41. <https://doi.org/10.1016/j.ats.2015.07.006>.
- [9] de Campos Azevedo CI, Angelo ACLPG, Vinga S. Arthroscopic superior capsular reconstruction with a minimally invasive harvested fascia lata autograft produces good clinical results. *Orthop J Sports Med* 2018;6(11):2325967118808242. <https://doi.org/10.1177/2325967118808242>.
- [10] Denard PJ, Brady PC, Adams CR, Tokish JM, Burkhart SS. Preliminary results of arthroscopic superior capsule reconstruction with dermal allograft. *Arthrosc J Arthrosc Relat Surg* 2018;34(1):93–9. <https://doi.org/10.1016/j.arthro.2017.08.265>.
- [11] Oh JH, Jun BJ, McGarry MH, Lee TQ. Does a critical rotator cuff tear stage exist? A biomechanical study of rotator cuff tear progression in human cadaver shoulders. *J Bone Joint Surg Am* 2011;93(22):2100–9. <https://doi.org/10.2106/JBJS.J.00032>.
- [12] Parsons IM, Apreleva M, Fu FH, Woo SLY. The effect of rotator cuff tears on reaction forces at the glenohumeral joint. *J Orthop Res* 2002;20(3):439–46. [https://doi.org/10.1016/S0736-0266\(01\)00137-1](https://doi.org/10.1016/S0736-0266(01)00137-1).
- [13] Steenbrink F, de Groot JH, Veeger HEJ, van der Helm FCT, Rozing PM. Glenohumeral stability in simulated rotator cuff tears. *J Biomech* 2009;42(11):1740–5. <https://doi.org/10.1016/j.jbiomech.2009.04.011>.
- [14] Savoie III FH, Calvo E, Mazzocca AD. The failed rotator cuff diagnosis and management. Springer; 2021. <https://doi.org/10.1007/978-3-030-79481-1>.
- [15] Plavsche GC, Petterson SC, Plancher DL. Repair with biologic augment. In: Savoie FH, Calvo E, Mazzocca AD, editors. *The failed rotator cuff diagnosis and management*. Springer; 2021. p. 109–18. https://doi.org/10.1007/978-3-030-79481-1_13.
- [16] Myers D, Triplett JJ, Johnson DB, Strakowski JA, Wiseman SP, Long NK. Anterior capsular reconstruction using a dermal allograft for an irreparable subscapularis tear after shoulder arthroplasty: a case report. *J Bone Joint Surg Case Connect* 2020;10(1):e0468. <https://doi.org/10.2106/JBJS.CC.18.00468>.
- [17] Elhassan B, Christensen TJ, Wagner ER. Feasibility of latissimus and teres major transfer to reconstruct irreparable subscapularis tendon tear: an anatomic study. *J Shoulder Elbow Surg* 2014;23(4):492–9. <https://doi.org/10.1016/j.jse.2013.07.046>.
- [18] Shin JJ, Saccomanno MF, Cole BJ, Romeo AA, Nicholson GP, Verma NN. Pectoralis major transfer for treatment of irreparable subscapularis tear: a systematic review. *Knee Surg Sports Traumatol Arthrosc* 2016;24(6):1951–60. <https://doi.org/10.1007/s00167-014-3229-5>.
- [19] Lädermann A, Collin P, Athwal GS, Scheibel M, Zumstein MA, Nourissat G. Current concepts in the primary management of irreparable posterosuperior rotator cuff tears without arthritis. *EFORT Open Rev* 2018;3(5):200–9. <https://doi.org/10.1302/2058-5241.3.180002>.
- [20] Gerber C, Rahm SA, Catanzaro S, Farshad M, Moor BK. Latissimus dorsi tendon transfer for treatment of irreparable posterosuperior rotator cuff tears: long-term results at a minimum follow-up of ten years. *J Bone Joint Surg Am* 2013;95(21):1920–6. <https://doi.org/10.2106/JBJS.M.00122>.
- [21] Elhassan BT, Wagner ER, Werthel JD. Outcome of lower trapezius transfer to reconstruct massive irreparable posterior-superior rotator cuff tear. *J Shoulder Elbow Surg* 2016;25(8):1346–53. <https://doi.org/10.1016/j.jse.2015.12.006>.
- [22] Bertelli JA. Lengthening of subscapularis and transfer of the lower trapezius in the correction of recurrent internal rotation contracture following obstetric brachial plexus palsy. *J Bone Joint Surg Br* 2009;91(7):943–8. <https://doi.org/10.1302/0301-620X.91B7>.
- [23] Antunes M, Quental C, Folgado J, de Campos Azevedo C, Angelo AC. Shoulder positioning during superior capsular reconstruction: computational analysis of graft integrity and shoulder stability. *Biology* 2021;10(12):1263. <https://doi.org/10.3390/biology10121263>.
- [24] Lacheta L, Brady A, Rosenberg SI, Dekker TJ, Kashyap R, Zandiye P, et al. Superior capsule reconstruction with a 3 mm-thick dermal allograft partially restores glenohumeral stability in massive posterosuperior rotator cuff deficiency: a dynamic robotic shoulder model. *Am J Sports Med* 2021;49(8):2056–63. <https://doi.org/10.1177/03635465211013364>.
- [25] de Campos Azevedo CI, Angelo ACLPG, Quental C, Gonçalves S, Folgado J, Ferreira N, et al. Proximal and mid-thigh fascia lata graft constructs used for arthroscopic superior capsule reconstruction show equivalent biomechanical properties: an in vitro human cadaver study. *JSES Int* 2021;5(3):439–46. <https://doi.org/10.1016/j.jseint.2021.01.016>.
- [26] Quental C, Folgado J, Ambrósio J, Monteiro J. Critical analysis of musculoskeletal modelling complexity in multibody biomechanical models of the upper limb. *Comput Methods Biomech Biomed Eng* 2015;18(7):749–59. <https://doi.org/10.1080/10255842.2013.845879>.
- [27] Quental C, Azevedo M, Ambrósio J, Gonçalves SB, Folgado J. Influence of the musculotendon dynamics on the muscle force-sharing problem of the shoulder-A fully inverse dynamics approach. *J Biomech Eng* 2018;140(7):071005. <https://doi.org/10.1115/1.4039675>.
- [28] Mihata T, Lee TQ, Hasegawa A, Fukunishi K, Kawakami T, Fujisawa Y, et al. Arthroscopic superior capsule reconstruction for irreparable rotator cuff tears: comparison of clinical outcomes with and without subscapularis tear. *Am J Sports Med* 2020;48(14):3429–38. <https://doi.org/10.1177/0363546520965993>.
- [29] Takayama K, Yamada S, Kobori Y. Clinical outcomes and temporal changes in the range of motion following superior capsular reconstruction for irreparable rotator cuff tears: comparison based on the Hamada classification, presence or absence of shoulder pseudoparalysis, and status of the subscapularis tendon. *J Shoulder Elbow Surg* 2021;30(11):e659–75. <https://doi.org/10.1016/j.jse.2021.04.019>.
- [30] Denard PJ, Chae S, Chalmers C, Choi JH, McGarry MH, Adamson G, et al. Biceps box configuration for superior capsule reconstruction of the glenohumeral joint decreases superior translation but not to native levels in a biomechanical study. *Arthrosc Sports Med Rehabil* 2021;3(2):e343–50. <https://doi.org/10.1016/j.asmr.2020.09.024>.
- [31] Lobao MH, Melvani RT, Abbasi P, Parks BG, Murthi AM. Dermal allograft superior capsule reconstruction biomechanics and kinematics. *J Shoulder Elbow Surg* 2021;30(9):2156–65. <https://doi.org/10.1016/j.jse.2020.11.024>.
- [32] Mura N, O'Driscoll SW, Zobitz ME, Heers G, Jenkyn TR, Chou SM, et al. The effect of infraspinatus disruption on glenohumeral torque and superior migration of the humeral head: a biomechanical study. *J Shoulder Elbow Surg* 2003;12(2):179–84. <https://doi.org/10.1067/mse.2003.9>.
- [33] Terry GC, Chopp TM. Functional anatomy of the shoulder. *J Athl Train* 2000;35(3):248–55. PMID: 16558636.
- [34] Yamamoto M, Itoi E. Treatment of irreparable rotator cuff tears with superior capsular reconstruction. *J Exp Orthop* 2021;8(1). <https://doi.org/10.1186/s40634-021-00342-1>.
- [35] Werner CML, Zingg PO, Lie D, Jacob HAC, Gerber C. The biomechanical role of the subscapularis in latissimus dorsi transfer for the treatment of irreparable rotator cuff tears. *J Shoulder Elbow Surg* 2006;15(6):736–42. <https://doi.org/10.1016/j.jse.2005.11.002>.
- [36] Mulieri P, Dunning P, Klein S, Pupello D, Frankle M. Reverse shoulder arthroplasty for the treatment of irreparable rotator cuff tear without glenohumeral arthritis. *Journal of Bone and Joint Surgery American* 2010;92(15):2544–56. <https://doi.org/10.2106/JBJS.I.00912>.
- [37] Seivias N, Ferreira N, Andrade R, Moreira P, Portugal R, Alves D, et al. Reverse shoulder arthroplasty for irreparable massive rotator cuff tears: a systematic review with meta-analysis and meta-regression. *J Shoulder Elbow Surg* 2017;26(9):e265–77. <https://doi.org/10.1016/j.jse.2017.03.039>.
- [38] Martins A, Quental C, Folgado J, Ambrósio J, Monteiro J, Sarmento M. Computational reverse shoulder prosthesis model: experimental data and verification. *J Biomech* 2015;48(12):3242–51. <https://doi.org/10.1016/j.jbiomech.2015.06.031>.
- [39] Dickerson CR, Chaffin DB, Hughes RE. A mathematical musculoskeletal shoulder model for proactive ergonomic analysis. *Comput Methods Biomech Biomed Eng* 2007;10(6):389–400. <https://doi.org/10.1080/10255840701592727>.
- [40] Klemm C, Nolte D, Grigoriadis G, Di Federico E, Reilly P, Bull AMJ. The contribution of the glenoid labrum to glenohumeral stability under physiological joint loading using finite element analysis. *Comput Methods Biomech Biomed Eng* 2017;20(15):1613–22. <https://doi.org/10.1080/10255842.2017.1399262>.
- [41] Praagman M, Chadwick EKJ, van der Helm FCT, Veeger HEJ. The relationship between two different mechanical cost functions and muscle oxygen consumption. *J Biomech* 2006;39(4):758–65. <https://doi.org/10.1016/j.jbiomech.2004.11.034>.
- [42] Ambrósio JAC, Kecskeméthy A. Multibody dynamics of biomechanical models for human motion via optimization. In: *Multibody dynamics. Computational methods in applied sciences*. Vol 4. Springer; 2007. p. 245–72. https://doi.org/10.1007/978-1-4020-5684-0_12.
- [43] Quental C, Folgado J, Ambrósio J, Monteiro J. A new shoulder model with a biologically inspired glenohumeral joint. *Med Eng Phys* 2016;38(9):969–77. <https://doi.org/10.1016/j.medengphy.2016.06.012>.