

Endoscopic resection of a large colonic lipoma by unroofing technique

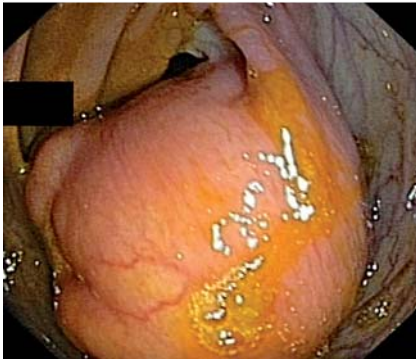

Fig. 1 Endoscopic view of the large, subepithelial, broad-based, polypoid mass with smooth, yellow surface in the ascending colon.

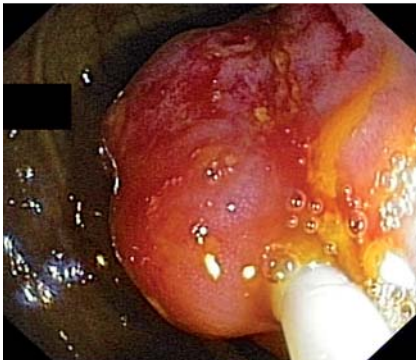


Fig. 2 The electrocautery snare transecting the upper portion of the mass.

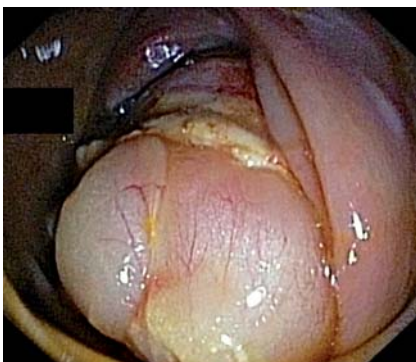

Fig. 3 Fat seen extruding from the mass after the unroofing procedure.

A 52-year-old man with a 1-year history of lower abdominal pain and constipation was referred to our unit for endoscopic resection of a large lipoma in the ascending colon, which had been detected by abdominal computed tomography (CT). Colonoscopy revealed a 50-mm, subepithelial, broad-based, polypoid mass in the as-

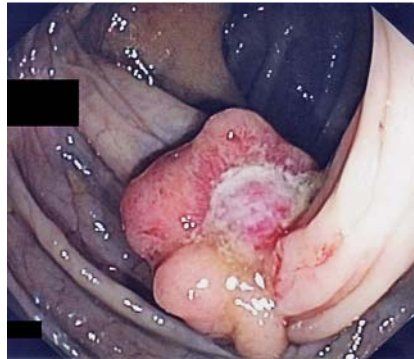

Fig. 4 Follow-up endoscopy 1 month later showing a small ulcer in involution at the resection site.

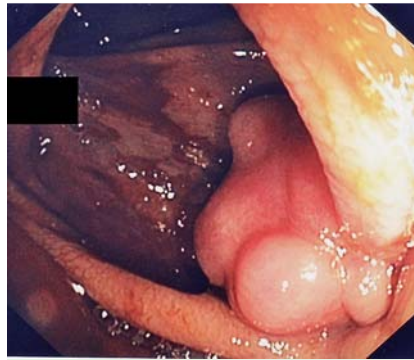

Fig. 5 Follow-up endoscopy 3 months later showing scarred mucosa at the resection site.

ending colon (● Fig. 1). Using an electrocautery snare, we transected the upper third of the mass to unroof the lesion (● Fig. 2). Fat was observed extruding from the cut surface, consistent with the diagnostic hypothesis (● Fig. 3). There were no procedure-related complications. Histopathologic examination of the excised specimen confirmed the diagnosis of a lipoma. A follow-up endoscopy 1 month later showed a small ulcer at the resection site (● Fig. 4), which was completely scarred 3 months later, with no evidence of residual lipoma (● Fig. 5).

Colonic lipomas are benign, submucosal tumors [1]. Although most colonic lipomas remain asymptomatic and need no treatment, large lipomas can cause symptoms such as abdominal pain, change in bowel habits, bleeding, and intussusception, and should be removed, preferably endoscopically [1]. Various endoscopic

techniques have been used in the treatment of large colonic lipomas, which include snare resection following endoscopic clipping, looping or injection of the base, endoscopic loop ligation, and endoscopic submucosal dissection [1–3]. The unroofing technique cuts off only the upper half of the lipoma, while the remaining adipose tissue is rapidly and completely extruded from the open surface [4,5]. Therefore, this is a simple technique that allows both histological confirmation and complete treatment with minimal risk of perforation [4,5]. Nevertheless, there are only two case reports of endoscopic resection of lipomas in the duodenum by this technique [4,5]. To the best of our knowledge, this is the first report of the endoscopic resection of a lipoma in the colon using this technique.

Endoscopy_UCTN_Code_TTT_1AQ_2AD

Competing interests: None

J.-B. Soares, R. Gonçalves, C. Rolanda
Gastroenterology Department of Braga Hospital, Braga, Portugal

References

- 1 Matsushita M, Danbara N, Kawamata S et al. Endoscopic removal of large colonic lipomas: difficult submucosal dissection or easy snare unroofing? *Endoscopy* 2009; 41: 475; author reply 475
- 2 Geraci G, Pisello F, Arnone E et al. Endoscopic Resection of a Large Colonic Lipoma: Case Report and Review of Literature. *Case Rep Gastroenterol* 2010; 4: 6–11
- 3 Koo J, Kaffes A. Endoscopic resection of large colonic lipomas assisted by a prototype single-use Endoloop device. *Endoscopy* 2006; 38: 644–647
- 4 Hizawa K, Kawasaki M, Kouzuki T et al. Unroofing technique for the endoscopic resection of a large duodenal lipoma. *Gastrointest Endosc* 1999; 49: 391–392
- 5 Huang WH, Peng CY, Yu CJ et al. Endoloop-assisted unroofing for the treatment of symptomatic duodenal lipomas. *Gastrointest Endosc* 2008; 68: 1234–1236

Bibliography

DOI 10.1055/s-0030-1256938

Endoscopy 2011; 43: E407

© Georg Thieme Verlag KG Stuttgart · New York · ISSN 0013-726X

Corresponding author

J.-B. Soares, MD

Gastroenterology Department of Braga Hospital
Sete Fontes, S. Victor
4701-243 Braga
Portugal
jbrunosoes@yahoo.com